EMPSON H. BAINBRIDGE
E. H. BAINBRIDGE

EX LIBRIS
ROBERT L. PHILLIPS, M.D.

EMPSON H. BAINBRIDGE
E. H. BAINBRIDGE

# Tumors *of the* Nervus Acusticus

## and the Syndrome of the

# Cerebellopontile Angle

*By*

Harvey Cushing, M.D.

Professor of Surgery at Harvard University
Surgeon-in-Chief to the Peter Bent Brigham Hospital
Formerly Associate Professor of Surgery
at the Johns Hopkins University
Director of the United States Army Base Hospital No. 5

*Illustrated*

*Philadelphia and London*

W. B. Saunders Company

1917

Copyright, 1917, by W. B. Saunders Company

PRINTED IN AMERICA

TO MY FRIEND

WILLIAM T. COUNCILMAN

Digitized by the Internet Archive
in 2025

https://archive.org/details/tumorsofnervusac0000harv

# PREFACE

In the course of preparation of a monograph dealing with a series of meningeal fibro-endotheliomata, a careful review was necessitated of the pathological as well as the clinical aspects of these interesting tumors. They have their point of origin in certain definite regions, and a tentative subdivision had been made of those arising from the spinal meninges, those from the basilar meninges, and those from the superior envelopes of the brain.

It was apparent that the spinal and basilar lesions usually arose from the meninges at the point of exit of a spinal or cerebral nerve root, and it was anticipated that many of the tumors of the cerebellopontile angle which involve the acoustic nerve would be included in the series, for the majority of them had previously been diagnosed from their gross appearance, though admittedly with some reservation on histological grounds, as endotheliomata.

Hesitation was felt in regard to the inclusion in the series of some of the spinal cord tumors, and these doubts became intensified when the lateral recess tumors came to be assembled and closely inspected.

A thorough rehearsal of the material at hand, comprising twenty-nine histologically certified cases, together with a much larger number of probable though unverified ones, which nevertheless were useful from the standpoint of their clinical data, so clarified many obscure matters relating to these peculiar and unmistakable tumors of the VIII$^{th}$ nerve that they have been made the subject of this separate study, and a report upon the 60 endotheliomata proper must await its turn. Unquestionably the acoustic tumors are most distinctive growths and such relationship as they have to the meningeal tumors occurring in the lateral recess will be pointed out in its proper place.

Some important monographs on the subject have already been published, of which Folke Henschen's Inaugural Dissertation, 1910,[81] is the most noteworthy, but in all of them the various tumors of the cerebellopontile angle have been incorporated, whereas the acoustic neuromas will alone occupy our attention to the exclusion of other tumors of the recess except in so far as they are of interest from the standpoint of differential diagnosis.

Most publications on the topic of brain tumors attempt to cover the entire subject from one aspect or another, but the time is ripe for special studies of special tumors in special localities, particularly if the surgical treatment of these difficult lesions is to be perfected.

Unquestionably the author profits most by an analytical study of a given group of cases, but inasmuch as the series of acoustic tumors herein reported is apparently the largest to have been verified in a single operative clinic, the study may be of some interest and value to others as well, and the future will doubtless see many improvements in the surgical procedure, with a still greater lowering of the operative mortality, which in the past has been so high as to be prohibitive.

I wish to express my deep obligations to the assistants who for the past

several years have consecutively had supervision of the neurological cases in my clinic and to whose industry and ability the hospital records of these cases testify—to George J. Heuer (1908), Samuel J. Crowe (1909), Emil Goetsch (1910) and Walter E. Dandy (1911) in Baltimore, to Charles Bagley (1912), Carl W. Rand (1913), E. B. Towne (1914), Gilbert Horrax (1915), and Samuel C. Harvey (1916) in Boston. I am indebted also to Ernest Grey for his special observations, during the past few years, of the cerebellar cases, and to my colleague Professor Councilman for his histological studies of the extensive material which has passed through his hands.

My thanks are due also to Professor Halsted for permitting me to use, as though they were still my own, the records of cases observed during my service in his clinic previous to September, 1912, at the Johns Hopkins Hospital.

To my secretary, Miss Louise Eisenhardt, whose assistance has been invaluable during the preparation of this monograph, I must leave the task of preparing the index and seeing the book through the press. The events of the past two months have made impossible the insertion of much new information gleaned from the four cases operated upon subsequent to February first. I fear that there may be many incomplete passages and many inaccuracies which I had intended to check during the revision. These faults, under the circumstance of an unlooked for but cordially accepted order for service overseas, my friends will overlook.

HARVEY CUSHING.

BOSTON, MASS.
May 6, 1917

# CONTENTS

CHAPTER I

PAGE

**Introductory and historical.** The early case reports by Sandifort, Bell, Cruveilhier, and others. The recognition of tumors of the posterior fossa: of the cerebellopontile angle: of the acoustic nerve . . . . . 1

CHAPTER II

**Sources of clinical material.** Baltimore and Boston series. Standard of tumor verification. Statistical studies showing percentages of acoustic tumors . . . . . 14

CHAPTER III

**Case reports.** Clinical and pathological records of thirty cases, twenty-nine with verified tumors (Cases I–III, V–XXX) . . . . . 18

CHAPTER IV

**Case reports.** Illustrative examples of the thirty-five unverified though presumable tumors of the acusticus (Cases IV, XXXI–XXXIII) . . . . . 138

CHAPTER V

**Etiology and incidence.** Trauma. Embryonal rests. Sex. Situation. Age. Expectation of life . . . . . 147

CHAPTER VI

**Symptomatology.** Importance of chronology. Primary auditory symptoms. Dilatation of the porus. Occipital discomforts. The cerebellar manifestations. Adjacent and contralateral cerebral nerve symptoms. General pressure signs. Dysphagia and dysarthria. Cerebellar crises. The fluctuation of symptoms. The corticospinal sensory and motor paths . . . . . 152

CHAPTER VII

**Pathological anatomy.** The lesion in gross; its place of origin, appearance, and situation. Its relation to the meninges and the brain and nerves. Histology of the lesion. The degenerations: central and peripheral . . . . . 177

CHAPTER VIII

**Bilateral tumors and generalized neurofibromatosis.** Relation of acoustic tumors to the meningeal endotheliomata . . . . . 210

CHAPTER IX

**Diagnosis.** Tumors of the cerebellopontile angle in general. Common sources of diagnostic error: (1) tumor syndrome misinterpreted: (2) erroneous localization; (3) other lesions of the angle, with examples of endothelioma (Case XXXIV), papilloma (Case XXXV), and glioma (Case XXXVI). Radiographic changes in the porus. The Bárány reactions . . . . . 217

CHAPTER X

PAGE

**Surgical treatment.** Methods of access to the tumor. The unilateral exposure. The translabyrinthine and the combined method. The bilateral operation. Its technical steps. Its advantages and defects. Statistical results of operation: the operative mortality and the ultimate results . . . . . 244

---

**Bibliography** . . . . . 279

**Index of Authors** . . . . . 289

**Index of Subjects** . . . . . 293

# TUMORS OF THE NERVUS ACUSTICUS

## CHAPTER I

## INTRODUCTORY AND HISTORICAL

**Introductory.**—The growing interest in the subject of intracranial tumors during the past decade has been due to several factors, the most important of which has unquestionably been the changed attitude of the operating surgeon toward the difficult problems which these conditions present. Whereas in former years the occasional attempts of the surgeon to expose and remove a brain tumor were made under the guidance of another, today he has come to assume the responsibility for the preliminary study and diagnosis of the case.

It was but natural under the old order that disappointments should have been many and successes few. Nothing is so likely to check progress as when surgical responsibilities are divided, and in the past, when they were shared by neurologist, ophthalmologist, otologist and perhaps others in addition to a reluctant operator, surgical failures were so frequent that utter discouragement prevailed.

Progress in cerebral surgery, though slow, nevertheless has continued to be made and credit for this is probably due largely to the unquenchable enthusiasm and persistence of the late Sir Victor Horsley, whose studies in experimental neurology were the basis of his activities as a neurological surgeon. There can be no better preparation for neurological operations on man than the experience gained from the production of experimental lesions on the central nervous system of animals, if made with the scrupulous technique employed in the hospital operating room; but in addition to this, the study of the symptoms and degenerations consequent upon these experimental procedures serves to give the best possible grasp on the complex subject of neurology.

The neurological clinic itself has benefited greatly from the wide-spread employment of the electric ophthalmoscope, more refined perimetry, the routine use of the X-ray, the revolving chair and the caloric tests of Bárány, to mention but a few of our present aids to diagnosis. These and other precise methods of examination are today in the hands of all and have led to an exactness of clinical observation. As a result of all this, during the past few years comparatively large numbers of patients with intracranial tumors have come to be congregated in certain surgical clinics where the preliminary studies and treatment are conducted by a coördinate staff of trained observers who approach the problems presented by each case from the surgical point of view.

Whereas formerly occasional examples of the various types of tumor might have been made the subject of study, the opportunity of investigating the lesion except at autopsy was rarely given and then only as a terminal condi-

tion after the clinical picture had become more or less confused. Today the opportunity is given of verifying the lesion in an increasing number of cases at a much more early stage than has heretofore been possible, and the operating room has largely supplanted the postmortem laboratory as the source of material for study. This is merely a repetition of the story concerning lesions in many other parts of the body.

Our increasing familiarity with intracranial tumors in general has led to a better classification of them on a structural basis, so that in some instances it has become possible not only to localize a lesion with considerable accuracy but to foretell its histological character with reasonable certainty. No more striking illustration of this is afforded than by a review of the story of the tumors occurring in the so-called cerebellopontile angle, which in the brief period since the beginning of the present century have emerged from comparative obscurity.

## Historical Review

With the historical information concerning acoustic tumors, which Carl Gustav Lincke[115] gathered in 1837 for his valuable and timely treatise on diseases of the ear, nearly all monographs on the subject have since been introduced. However, as was pointed out many years later by Virchow in his celebrated *Vorlesungen*, it is difficult enough to tell from the tissues at hand whether one is dealing with a true acoustic tumor, and these difficulties are greatly enhanced if one attempts to pass judgment on the incomplete case reports of the earlier writers.

Doubtless isolated examples of these distinctive growths must have long been observed, but Sandifort's presumptive case[155] described in 1777 does not seem to be definitely antedated. Of this tumor, under the title *De duro quodam corpusculo, nervo auditorio adhaerente,* Sandifort wrote from Leyden as follows:

" * * * * As I examined the base of the brain, with the origins of the nerves, I discovered a small body clinging to the right auditory nerve, of such toughness that it was supposed surely to be cartilage. It was not so firmly attached to the inferior part of the said nerve, but it clung tightly to the proximal portion of the medulla oblongata, at that point where this nerve (the VIII$^{th}$), together with the VII$^{th}$, makes its exit, likewise insinuating itself into the foramen as an obstruction in the interior of the petrous portion of the temporal bone, which said nerve enters. The length of this small body was six lines, its width in its wider portion was five, and in its lesser, three lines. Its surface was exceedingly uneven, especially that part which was in relation with the base of the skull, and various larger and smaller nodules arose from its surface. It was not possible to separate the nerve from the lesion and neither was it possible to free it entirely from the foramen which the nerve enters, but it was more easily separated from the part of the medulla to which, as stated before, it adhered.

"Having cut into the body, it presented a tough cortex or exterior part: the interior, however, was somewhat softer, although in this also there were hard particles interspersed.

"The situation and firm lodging of this little body demonstrate without doubt that it compressed the auditory nerve. The depression seen at the point noted in the medulla and neighboring soft parts proves it, and the extension of the nodules into the foramen of the nerve still further confirms it. This lessened the nerve greatly in its capacity, as seen by a comparison of the right auditory nerve with the left.

"And so, this little body, hiding in the recess of the brain, is to be considered as the cause of deafness in this case. To it there was neither medicinal nor manual access, the case being therefore entirely incurable.* * * * * "

During the first half of the past century a few autopsy specimens were described as pathological curiosities, but some of them were accompanied by an account of the symptoms which the patient had exhibited. The earliest of these case reports of which I am aware was that of Lévéque-Lasource[110] in 1810. A woman of 38 had primary vertigo, followed by headache, loss of vision, tinnitus and then deafness in the left ear, instability, numbness of the extremities, dysarthria, and deviation of the tongue. At the autopsy a fibrous tumor, supposedly arising from the auditory meatus, was found attached to the petrous bone, but since the acoustic nerve was not destroyed but merely pressed aside, it is quite possible that here too, as in Sandifort's case, the tumor was a meningeal endothelioma and not an acoustic tumor proper.

Though a brief note of a possible case was given by Abercrombie[1] in 1828, the first clinical account of what seems to be an undoubted tumor of the acusticus appeared in 1830 in the appendix to Charles Bell's classical monograph on the nervous system,[19] and the letter from John Whiting (*cf.* pp. 176 and 180) concerning the patient is a good illustration of the clinical acumen and descriptive powers of the English physician of a century ago. This of course was long before cellular pathology, long before the ophthalmoscope and long before cerebral localization. Bell's chief interest lay in the discomforts produced by the pressure of the growth (Fig. 1) against the V$^{th}$ nerve, whose function as a transmitter of afferent impulses, in contrast to the motor VII$^{th}$, he was endeavoring in every way possible to emphasize.†

In 1834 Boyer[31] reported before the *Société anatomique* as a *tumeur encephaloides cancéreuse* what seems from the gross description to have been an unmistakable acoustic tumor which projected into and widened the auditory canal, and Richard Bright is accredited by Henschen with having also described a case in his celebrated *Reports of Medical Cases*, 1831,[34] but this proves without doubt to be a pontile glioma and not a primary tumor of the acoustic nerve.

Weiglein,[194] in 1840, under the title "*Ein Steatom des Gehirns nebst mehreren*

---

* The liberty has been taken of emphasizing certain passages in this quotation which occasion grave doubts as to the pathological diagnosis, for from Sandifort's description it would seem that the tumor must have been an endothelial psammoma, arising from the petrosal meninges, and compressing the nerve, rather than an acoustic tumor proper.

Sandifort's chapter contains the following brief reference to the earlier literature: "We may therefore conclude with the observation of Drelincourt, who was able to prove that he saw blindness, deafness and even lethal apoplexy caused by a steatoma clinging between the cerebrum and the cerebellum."

Dr. F. H. Garrison has kindly traced this reference for me to the *Sepulchretum* of Th. Bonet, Geneva, 1679, Observatio LIII, "*Apoplexia à Tumore steatomico constituto inter cerebrum et cerebellum.* Vidit Clariss. Dom. Drelincurtius Tumorem steatomatis consistentia, pugnique magnitudine, cerebrum et cerebellum inter, lo praecise loci ubi conarium utrique substernitur choroidis plexus alae, spatio semestri à sensibili laesione, caecitatem primo surditatem subinde, omnium denique sensuum & functionum animalium abolitionem, & necem ipsam intulisse Joh. von Flammerdinghe Disputatione de Apoplexia, Thesi 12." Obviously not an acoustic neuroma.

† It is not without interest to note that these four earliest case reports came from Leyden, Paris, Edinburgh, and London, indicating the shift of medical progress successively to these four cities.

*Fungi medullares und Hydrocephalus ventriculorum cerebri,*" gives an excellent and clear case report and, what is more, speaks not only of the pressure absorption of the pyramidal bone but of the secondary dilatation of the sella from a dilated third ventricle, of the hydrocephalus, the thinning of the skull, and, still more notable, of herniations of cerebral substance through cranial pressure defects (*cf.* p. 194).

Remarkable for the time as were some of these observations, by far the most important and complete of these early reports was made by Jean Cruveilhier[41] in a chapter on diseases of the dura mater, in the second volume

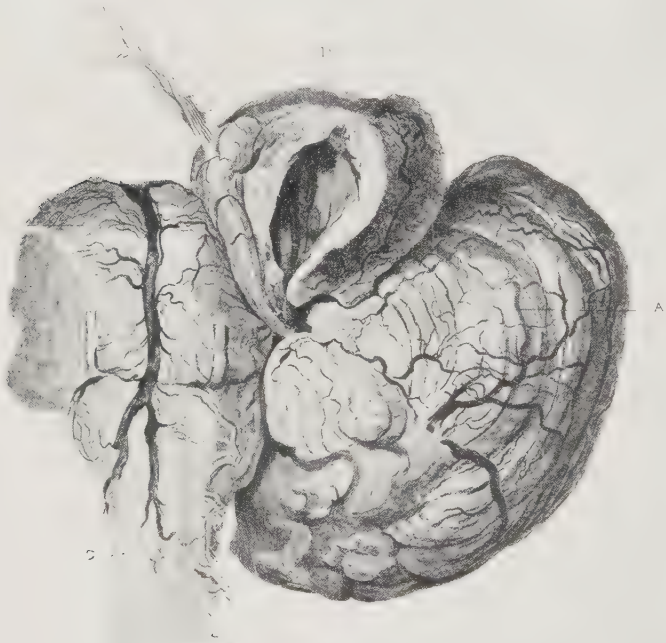


Fig. 1.—Charles Bell's own sketch (1830) of an acoustic tumor with cystic degeneration (D), showing (E) the thinned and shredded N. trigeminus.

(1835–1842) of his justly celebrated folios—*Anatomie pathologique du Corps Humain.* The report is sufficiently notable to deserve translation in full with the photographic reproduction of Chazal's beautiful plate (Fig. 2).

*Tumeur fibreuse née de la face postérieure du rocher, comprimant le cervelet et la protubérance annulaire.—Perte successive de tous les sens.—Érosions profondes de la surface interne de la base du crâne.—Pénétration de la substance cérébrale dans les érosions ou petites excavations accidentelles de cette base.*

Mlle. Amable was under my care during the last three months of her life: at the time

that I was called in consultation she was twenty-six years and three months of age, and her condition was as follows:

Complete amaurosis; no less complete loss of taste and smell; partial deafness. Violent headache, which she reports as occurring constantly in the top of her head; numbness of

Fig. 2.—Chazal's lithographic plate illustrating Cruveilhier's case (1835).

the skin of face, and at times sharp pain in the left thigh, which seems to alternate with the cephalalgia.

Intelligence remained unimpaired to the last; passionate wish to die, as the sole means of ending her sufferings. No paralysis of movement.

From time to time, convulsive contraction of the facial muscles, accompanied by rigidity of the limbs, principally those of the left side. * * * *

During this last month of her life she experienced, at different times, attacks of eclampsia which started with extraordinary fancies; impediment of speech; temporary loss of reason. * * * *

In spite of the loss of taste the desire for food was maintained; but for the last two weeks of life she refused nourishment, and for the first time there was practically continuous nausea; violent efforts to vomit, which raised phlegm; redoubled cephalalgia. There were rare intervals between attacks during which her saneness of mind was admirable, also her clearness of speech; and it was following a state of more prolonged calm than usual—which gave her parents some hope—that the patient lost consciousness and died after 24 hours of agony. * * * *

My diagnosis had been this: Compression of the brain by an expanded tumor, either at the expense of the meninges, or in the thickness of the brain itself; the probability of the seat of this tumor being at the base of the skull.

Here are, besides, the memorandum notes: Health excellent until 19 years of age.

At 19 years, *partial deafness* of the left ear; the young person became subject to *violent headaches*, which occurred several times a week, disappearing quite promptly, and being steadily relieved by the application of cold objects to the forehead. The patient, to this end, rested her forehead, as if instinctively, on marble, and on objects of metal.

At the age of 20, *lessening of the vision of the right eye.*

At 21, convulsive contractions of the left cheek, during which the commissure of the same side drew closer to the ear. These contractions occurred again three times at short intervals. Blood-letting from feet. One month later, renewed contractions in the same cheek. Sixteen leeches applied to mastoid apophyses. From this time her vision weakened by degrees, and three weeks after the first attack the patient could no longer see well enough to get about.

The principal oculists consulted prescribed remedies which were of no avail. The patient entered the Charity Hospital, but her vision not improving, she decided to enter the Hôtel-Dieu, where moxas and the electro-puncture were ineffectually used. Her condition grew perceptibly worse, the spasmodic contractions of the left cheek returned, and at the end of several months' stay in this hospital she was completely blind.

The patient left the hospital, determined to try nothing more. For a period of two years her condition remained unchanged; general health very good, very pronounced appetite, the pains in the head less violent and more infrequent: the muscular force returned, permitting her to take long walks. She was resigned to remaining blind, and her parents, otherwise, had no anxiety for the future.

Nine to ten months before her death, new symptoms appeared unexpectedly, which went to show that the blindness was not idiopathic, but that it pointed to an organic cause, permanent, actual, the increase of which would, however slowly and imperceptibly, lead to the most fatal consequences. These new symptoms were sensations of tingling in the right cheek, frightful pains in the head, which alternated with no less sharp anguish in the left thigh. The contractions were no longer limited to the face, but were accompanied by rigidity of the upper limbs.

The patient entered the Beaujon Hospital; there she lost the sense of taste. Having returned home after a three weeks' sojourn in this hospital she lost her sense of smell. It was then that I was called in to care for her. I have stated above the result of my observations.

*Autopsy.*—I had stated that this malady consisted of an enlarged tumor in the skull, exerting on the brain and probably on the base of this organ an astriction which had caused the successive loss of all the organs of sense, and the numbness of sensibility in the face.

Indeed, the skull being opened, the brain being inverted from top to bottom and from front to back, I saw in the lower left occipital cavity, consequently underneath the tentorium cerebelli, a hard, mammillated tumor which forcibly compressed the left lateral half of the protuberance, the medulla oblongata, the corresponding peduncle of the cerebellum, and the cerebellum. (See Fig. 2, *Figs. 1, 2, 3.*)

This tumor adhered by a considerable pedicle to the posterior face of the petrous bone (Fig. 2, *Fig. 3*). *Fig. 1* of Fig. 2 represents the section of the pedicle PT. It orginated in a cavity TE (*Fig. 4* of Fig. 2), located on the posterior face of the petrous bone, the anfractuous cavity occupying the interior half of this posterior side joining the internal auditory meatus to the jugular foramen and to the carotid canal.

*Fig. 1* represents the tumor in its relation to the encephalic mass: it can be seen that it exerts a considerable compression on the parts previously enumerated. The ligaments of the pneumogastric, glossopharyngeal and Willis' nerve had been thrown back in front of the tumor, which they twined around. These nerves were spread, and remote from each other, but without having had their tissue altered. The large hypoglossal nerve (9) showed nothing in particular. The seventh and the fifth pairs of nerves were compressed between the brain and the tumor. The ligaments of the fifth pair were found to be in front of this tumor; they were spread out like a wide ribbon. The sixths were deviated but not altered; the left olfactory nerve was withered (1st P.), the right one lessened; the optic nerves (2nd P.) completely atrophied. The tissue was grey.

*Fig. 2* shows the tumor inverted, to show clearly the depression of the brain in which it rested. The fifth nerve (5th P.) presented in every part of it that leads to the tumor, a tendency to flatten, remarkable in width and thinness of texture. Both the hard and soft parts of the seventh pair had suffered such a strong compression that by a light pull they could be detached from their point of origin; the peduncles of the cerebellum were softened on the surface, and the cerebral lamellæ were separated and atrophied. * * * *

The tumor was of the fibrous type, and did not present the least symptom of cancerous degeneration; the pedicle PT, *Fig. 1*, even showed some traces of ossification. This pedicle, which was buried in the irregular cavity shown in *Fig. 4*, could be detached easily, so that the tumor seemed to me to have originated not so much from the bone as that portion of the dura mater which extends into the internal cavity of the ear; moreover, the internal auditory passage was impossible to recognize in the middle of the anfractuous cavity TE (*Fig. 4*), which joined the internal cavity of the ear and the posterior ragged hole, communicated principally with the carotid canal, and occupied the internal half of the posterior surface of the petrous bone. The auditory and facial nerves were completely decayed at their entrance into the petrous bone,—in short, I never found a trace of them, and I can hardly believe that they could have resisted a pressure which was strong enough to wear away so thoroughly the flinty temporal bone.

My attention was then directed to the cranial bones, which showed on their inner surface a quite remarkable tendency which I have still to describe, and of which *Fig. 3* is a faithful reproduction.

I had recognized, in turning the brain upside down and from side to side, that the grey substance of this organ seemed to proceed from hollows or sockets with which the base of the skull was grooved, that the dura mater was wanting at the level of these hollows or sockets, that the tractive efforts necessary for removal of the brain sufficed to tear the cerebral substance of which several small portions remained attached in these sockets, being evident to me that these deep depressions, wrinkled on the surface and as if lacerated at the

base of the skull, were the result of the compression exerted by the brain on the various points of the base. * * * *

The very much widened sella turcica FP was filled not only by the pituitary body, but in addition by a very considerable protuberance formed by the lower wall of the middle ventricle, this being swelled into a half-transparent sac by a flood of serous liquid.

This sella turcica was reduced to a groove, the left edge of which was entirely lacking, and the right sharp. At the bottom of this groove were the small erosions which showed that the sphenoid would not have remained long before being pierced.

The orbital surfaces and sphenotemporal grooves were deeply eroded, as if having undergone the corrosive action of an acid, hollowed out by holes, and by small grooves separated by a species of very irregular bony bridges. The two oval holes TO, TO were considerably enlarged, particularly that on the right side (the side opposite to the tumor), which had tripled in dimension; the large round hole on the same side was, in the same way, more developed than that of the left. The ethmoidal canals were enlarged and dotted with erosive holes absolutely distinct from the vascular and nerve cavities of the cribriform plate.

These erosions had singularly lessened the thickness of the walls of the base of the skull, such that the pressure of the finger would have sufficed to break them into a multitude of fragments. The orbital arch was pierced from side to side. The frontal sinus was in a state of degeneracy. The optic foramina were very shrunken, flattened from top to bottom, in harmony with the atrophic nerves to which they gave passage.

*In all the erosions or small hollows of the base of the skull was buried cerebral substance.*

The arch of the skull showed me depressions and eminences much more than ordinarily pronounced. The principal groove of the middle meningeal artery was very deep, so much so that at the level of the anterior and inferior parietal angle the skull was no thicker than a sheet of paper; three or four deep erosions leading to groups of veins were seen at the right of the biparietal suture.

The arch and the base of the skull have been given to the Dupuytren.

*Reflections.*—If now we try to interpret the symptoms observed during life, by the lesion found after death, we shall discover that everything turns on the compression exerted by the tumor on the encephalic mass; but to perfectly comprehend the effects of this compression, a consideration which I have had occasion to develop on the subject of tumors of the dura mater should be remembered,—namely, that the causes for compression of the brain produce two sorts of effect:

First—A direct effect upon the points subjected to the compression;

Second—An indirect effect on all the contents of the skull. Very well! in the case in which we are interested, the direct effects were only felt by the fifth and seventh pairs of cranial nerves, for the protuberance was compressed in its left lateral half, and the lesion of this protuberance showed no symptom of either myotility or tenderness. The left cerebral peduncle, the olivary and left restiform bodies were equally compressed; there was actually silence, if I may describe it thus, on the side of the symptoms.

The first symptom which was manifested was the partial deafness of the left ear, and this deafness was explained by the compression of the auditory nerve; direct effect. The convulsive contractions of the left cheek did not take place until later, undoubtedly because the facial nerve, being harder, resisted for a longer time the causes of compression.

The second symptom which appeared was the diminution of vision, and to explain that we must refer to the indirect compression of which I spoke a short while ago. * * * *

I regard the blindness, and the loss of the sense of smell, as the result pure and simple of the indirect compression of the base of the brain. The olfactory and optic nerves, before and after crossing, were atrophied by the compression. The thalamus opticus, and more particularly the genu facialis, also the quadrigeminal tubercles, were perfectly sound. The

tinglings in the left cheek, as well as the loss of taste, happening unexpectedly toward the end of the illness, kept up very manifestly, also the *direct* compression exerted on the left fifth, and the *indirect* compression exerted on the nerve of the right fifth.

In short, the cephalalgia, a common result of a multitude of different causes, ought to be attributed less perhaps to the compression and irritation exerted directly on the parts compressed than to the general compression of the brain.

I shall call attention, above all, to the wearing away of the base of the skull by a mass as soft as the brain: is this an exceptional thing? But there is nothing which is an exception in the vital harmony, and it is probable that attention being drawn to this point, analogous cases will not remain long unreported. It was observed elsewhere that each circumvolution received in its cranial impression and animated by the movement which stamped the arteries to the encephalic mass can have on the bones the effect of an aneurysmal sac. I will call attention to the fact that intelligence persisted to the last; that the general sensibility and muscular contractility were not injured, so that the brain accustomed itself to all the causes of the compression.

Amaurosis is a common symptom in a great number of organic diseases of the brain, and the result either of a direct compression (example: the tumors of the pituitary body) or of an indirect compression. There are, besides, cases of amaurosis (and these are the most numerous) that are called idiopathic, and result from a pure and simple atrophy of the optic nerves, without any lesion whatever of the genu facialis, the thalamus opticus, or any part of the brain. * * * * Amaurosis with the loss of the olfactory sense, and the sense of hearing on one side, accompanied by numbness of the facial muscles on the same side, characterizes tumors which originate on the posterior face of the petrous bone, and particularly those tumors originating in the internal auditory passage.

It is quite a frequent occurrence to see tumors of different kinds, having originated either on the posterior or else on the anterior surface of the petrous bone. These are sometimes fibromas, sometimes osteofibromas; at other times they show cancerous degeneration in some part. The description of tumors of the petrous bone deserves a place in the history on tumors which develop in the skull: those which originate from the upper surface of the petrous bone, in other words, in the sphenotemporal cavity, being distinguished from those of the lower occipital cavity. The former produce their effects of compression directly upon the cerebellum, the apophysis, and indirectly on the brain.

Little can be added today to this remarkable clinical and pathological report of Cruveilhier's, in which he notes the primary deafness, the fluctuating and contralateral cerebral nerve symptoms, the general pressure phenomena with secondary loss of sight and smell, the stalk of the tumor and the enlarged porus, the distortion of the adjacent cerebral nerves, the deformation and absorption of the sella, the cerebral herniations, and much else besides. Many of these observations have since been remade supposedly for the first time.

In the second half of the century, following Toynbee's[184] brief pathological note in 1853 with the first authentic description (*cf.* p. 177) of an early tumor, and Virchow's casual reference to an acoustic tumor in 1858,[187] the number of reported cases rapidly increased, so that by the end of the century the post-mortem appearances had become fairly well known and the clinical symptomatology sufficiently well appreciated to permit of an occasional localizing diagnosis, in some cases, indeed, with sufficient assurance to justify operative exploration.

Oppenheim[133] is usually accredited (1889) with the first correct localization,* based on clinical symptoms, of a tumor of the angle, and though he gives no pathological note and the growth was regarded as arising from the cerebellum, the sketch of the lesion which accompanies his report leaves no doubt as to its being an unmistakable acoustic tumor. Antedating this, however, by ten years, there was published in this country by G. T. Stevens[175] a typical case in which a correct diagnosis appears to have been made and operation advised but not attempted. The tumor, which was subsequently found projecting into and dilating the internal auditory meatus, was described as a fibrosarcoma and was shown to have taken its origin from the auditory nerve. Sufficient credit has never been given for this observation.

In 1900 Sternberg[174] assembled many of the reported examples of what had come to be called "acoustic tumors,"† and with the addition of four personal observations gave a very clear pathological description of the lesion, which he regarded as a mixed tumor of a gliomatous nature (gliofibroma), whereas on a histological basis the lesion had been most variously designated by his predecessors.

Meanwhile the last decade of the century had been signalized by notable additions to the scant knowledge of cerebellar function which had been acquired since Flourens's time. Flourens's classical experiments led him to believe that the cerebellum as a whole is a center for coördinating the action of voluntary muscles, but it was difficult for later observers to understand how after removal of the cerebellum the early incoördination could be recovered from, and it may be recalled that two Americans, J. C. Dalton[50] in 1861 and Weir Mitchell[128] in 1869, made suggestive contributions to this problem.

In the sixties and seventies, particularly in French and English literature, there occur many case reports of presumed acoustic tumors, mostly chance postmortem findings, though in some instances good clinical histories are given and occasionally the observers had reached out toward a clinical diagnosis. Rapid strides, however, were not made until the experimental researches of the period between 1890 and 1900, of which those of Luciani,[117] of Risien Russell[151] and of Ferrier and Turner[56] were among the most notable.‡ As a result of these studies the homolateral disturbances of coördinate trunk and limb movements—variously designated by such terms as ataxia, dysmetria, astasia, dystonia, asynergia and so on—became sufficiently well understood to lead to a rapid advance in the clinical interpretation of the symptomatology of posterior lesions. Hughlings Jackson and Gowers in England, Bruns and Oppenheim in Germany, and particularly Babinski in France, through his article on cerebellar asynergia based on two cases of presumable acoustic tumor, were notable contributors to our better understanding of cerebellar symptomatology.

More exact clinical diagnoses quickly followed. In 1900 Sternberg's

---

* There must be some doubt of this, for Wollenberg's typical case,[208] reported from Westphal's clinic in the Charité in 1890, was examined neurologically by Oppenheim, and the diagnosis lay between a tumor of the cerebellar hemisphere and tabes dorsalis.

† It is of interest to recall Rokitansky's[151] statement made in 1848 in regard to neuromas to the effect that they may occur in all nerves except the olfactory, optic and acoustic, a statement to which Virchow in 1863 first took exception so far as the VIII$^{th}$ is concerned.

‡ A chronological bibliography of the more important experimental studies is appended to Luciani's monograph on "Das Kleinhirn," in the *Ergebnisse der Physiologie* for 1904.

important paper[174] appeared, and in the same year von Monakow[129] reported a case of neurofibroma or fibrosarcoma of the acusticus which had been correctly diagnosed and localized during life. He not only fully described the essential symptom complex, but suggested, on the basis of the postmortem appearances, that such lesions might be favorable for operative removal,* and it is probable that this opinion had much to do with the reawakening of interest in the surgical aspects of these lesions in the next few years.

In 1902 Hartmann,[77] from Anton's clinic in Gratz, assembled 26 cases from the German literature and gave an excellent description of the symptomatology of the tumors situated in what he called the recessus acusticocerebellaris, and since then the general designation of "recess tumors" has been occasionally used. In the same year, however, Henneberg and Koch,[78] in an important paper in which a case with bilateral acoustic tumors was described in detail, introduced the term cerebellopontile-angle tumor ("Kleinhirnbrückenwinkeltumor"), and despite its cumbersomeness and the fact that it refers to an anatomical region rather than to the point of origin of the lesion, the term has been used as a blanket for all tumors of the region and has almost completely superseded the designation of "acoustic tumor" which up to that time had been employed for the growths in this region appearing to arise from the VIII$^{th}$ nerve.

Thus under the awkward designation of "tumors of the cerebellopontile angle" there have since been included in the more important articles on the subject all tumors of the region which involve the cerebral nerves of the locality, those which primarily arise from the acusticus and those which come to involve it secondarily or not at all.† In 1903 Ziehen attempted to introduce as a substitute the terms "angulus pontis" and "receptaculum pedunculorum," and two years later[214] the still more brief "acoustic region," and many French writers adhere to the designation of *tumeurs cérébello-protubérantielles*, but the cerebellopontile angle seems to have come to stay.

More or less unsatisfactory attempts have been made by Henschen and others to bound this region centering about the flocculus where brachium pontis, eminentia olivaris and other structures join hands. Certainly by the time a tumor is present the so-called angle or corner has disappeared and its confines distorted beyond recognition.

In this country wide attention was first drawn to the subject of these tumors by Fraenkel and Hunt's report of a series of five cases in 1903, and in the following year Stewart and Holmes published in *Brain* their important study in which the symptomatic distinction between intra- and extracerebellar tumors was clearly drawn, many of the latter being tumors of the acusticus, though all subtentorial growths which originated from the extracerebellar structures were grouped together for the purposes of their clinical investigation.

---

* At this period, as may be recalled, it was claimed on the basis of autopsy findings that no more than seven per cent of all intracranial tumors could be considered operable lesions, and it is interesting to note that 30 of the 468 verified brain tumors in the author's series, namely, 6.4 per cent, represent acoustic tumors alone.

† Orzechowski[135] emphatically expressed the belief as late as 1908 that the acusticus itself bears only an accidental relation to the tumors so commonly found in this region, which in his opinion arise from a congenital rest in connection with the medial wall of the recess.

During these early years of the century, though the surgery of cerebral tumors was in considerable disrepute, due largely to the publication of von Bergmann's discouraging views on the subject, the first operations upon undoubted acoustic tumors in any considerable number began to be undertaken, and in 1903 Horsley appears to have had a series of six cases at the National Hospital, at least one of which* made an unusually perfect recovery.

Though much progress in the clinical appreciation of these lesions was made during the next few years, there was still much confusion regarding them and they were usually grouped with other tumors of the region. Thus Henschen's important dissertation in 1910[79] comprised all of the posterior fossa tumors, though it gave special attention to those of the cerebellopontile angle. His more recent paper,[81] however, was restricted to tumors of the angle, with special emphasis on those originating from the acusticus. In 1909 and 1910, in an excellent series of papers built up around the report of a single "glioma of the acusticus," Alagna[3] of Palermo pointed out the various histological diagnoses which might be made in a series of these lesions, and urged that for these distinctive growths the original designation of "acoustic tumor," which had largely fallen into disuse since 1902, be again resumed. To this Henschen has also subscribed, and one argument in its favor, as Verocay points out, lies in the fact that the acoustic neurofibromas not only have their own distinctive individuality, but that most of the tumors of the angle are of this origin.

Among the many other contributors to the subject should be mentioned Alquier and Klarfeld,[8] who in 1911 gave a thorough résumé of the *tumeurs extraprotubérantielles*, a designation for these lesions often employed in France. In the same year also Jumentié[92] published a valuable thesis relating to a series of eight verified cases studied at the Salpêtrière. In 1915 there appeared an important paper by Fumarola[63] from Mingazzini's clinic in Rome, and also in the same year Henschen's[81] third communication based on observations upon seven new cases, one of them an early tumor. This last article is probably the most valuable communication which has as yet appeared.

Thus in the course of fifteen years the subject has advanced from the diffuse presentation of tumors of the posterior fossa in general, to the clinical differentiation of the intracerebellar from the extracerebellar growths, and particularly of those of the cerebellopontile angle from all others. Finally in the group of cerebellopontile tumors, those originating from the Nervus acusticus have come to stand out with comparative clearness from those which secondarily involve this and the other nerves of the region through pressure.

In this present monograph stress will be laid upon the fact, insufficiently emphasized, that the acoustic tumors, owing to the characteristic chronology of their symptoms, may as a rule be sharply distinguished from all other tumors of the cerebellopontile angle.

## Summary

Scattered reports of undoubted acoustic tumors occur in the literature as early as 1830. The more notable of the early cases in which full clinical notes

* *Cf.* Stewart and Holmes,[177] Case 19, p. 585.

accompany the postmortem findings were recorded by Charles Bell, by Cruveilhier, and by Weiglein. The possibility of the clinical recognition of this condition did not arise until the latter part of the century following the experimental studies of cerebellar function. The diagnosis of subtentorial tumors rapidly became perfected, first of those giving cerebellar symptoms, then of those in the cerebellopontile angle, and finally of those arising from the acoustic nerve. Attempts at surgical removal have slowly followed in the footsteps of the more nearly exact clinical diagnoses.

## CHAPTER II

# CLINICAL MATERIAL

The author's series of brain tumors, from which the acoustic tumors comprising this study have been taken, consists of two groups of cases—a Baltimore series observed during the ten years from January, 1902, to August, 1912, of which the early records from our present standards are more or less imperfect, and a Boston series observed in the four years from September, 1912, to February, 1917.

There were 337 patients with the diagnosis of brain tumor in the Baltimore series, and the nature of the lesion has been verified in 195, or in 57.8 per cent of the cases. There have been 447 cases in the Boston series, the lesion having been verified in 273, or 61 per cent of the cases. Thus of the 784 cases the character of the lesion has been verified, either at operation or at autopsy, in 468 instances.

When a lesion is spoken of as verified it means that its histological character has been established, either from the examination of tissues removed at operation or from those secured at a postmortem examination. The only exception to this is in the case of the gliomatous cysts, whose straw-colored clotting fluid is sufficient to establish a diagnosis without tissue removal. This rigid rule has been adhered to for the reason that only too often one may be deluded as to the character of a growth by external appearances alone, and, as we shall see, this is particularly true of the tumors which may be exposed at operation in the cerebellopontile angle (*cf.* Case XXXVI).

The histological diagnosis in a number of the Baltimore cases which four years ago were catalogued as unverified has since become established by autopsy or by secondary operations, and these cases have consequently been transferred to swell the number of verified Baltimore cases, so that the comparative equality of the verified lesions in the two series, i. e., about sixty per cent, speaks very much in favor of the Boston series, in which a far larger percentage of successful operations has been performed and the patients more closely followed. In all probability in the course of a few years the nature of the lesion in ten or twenty per cent of the 174 unverified cases of this later series will have become established. Thus we should ultimately be able to certify the diagnosis in seventy or eighty per cent of these cases, and it is quite likely that many of the cases now classified as presumptive may in the end prove to be examples of a tumor syndrome due to conditions other than a new growth. Such as they are, however, the present numbers of verified cases are sufficient to give an idea of the relative frequency of the various types of intracranial tumors.

These 784 cases may now be analyzed further. It has been our custom to

subdivide the cases of brain tumor into (1) those with verified lesions; (2) those with indubitable brain tumors, the nature of the lesion remaining uncertified even though it may have been seen at operation; and (3) those with brain tumor syndromes which may or may not prove to be caused by a new growth—tumor "suspects," pseudo tumor, and other conditions. The verified lesions, as already stated, amount to about sixty per cent, the undoubted, though unverified, to about thirty per cent, and the presumptive to about ten per cent of the cases in the series.

There are of course many patients in every large neurological clinic who are not even "suspects," so far as their carrying a brain tumor is concerned. Our clinic has its full share of these overlooked cases and they probably outnumber the cases falsely diagnosed as tumor. Hence there are frequent additions to the column of verified tumors by cases which on a previous admission received a diagnosis other than tumor, usually on the basis of a negative exploration for focal epilepsy or some other condition.

Naturally in the course of time many of the patients in the "undoubted" thirty per cent will move up into the certified group, though unquestionably a certain number of them will in the end prove to have some condition other than tumor. For example, two patients, each with an unlocalizable tumor syndrome, were unrelieved for long by decompressive measures, and subsequent examination showed them to have a torular meningitis.[179] Had they been discharged and no autopsy performed, they would have remained permanently on the list as "cerebral tumor: unverified," though as events proved they did not belong in the tumor group at all.

Unquestionably, therefore, in the subdivision of "presumptive" though less probable cases in the unverified group, there is a preponderance of errors due to conditions such as vascular disease, various forms of chronic meningitis, abscess, cerebrospinal-fluid circulatory disturbances and so on, which have given a tumor-like syndrome. The majority of these cases, of course, are living with or without operation and the final decision can only be made in time.

After this statement regarding our standards of classification we may continue with the analysis of the 784 cases with the end of determining the numerical ratio of acoustic tumors to other intracranial growths. The following table shows the relative frequency of growths arising from the forebrain and hind brain—in other words, those situated above and those below the tentorium.

TABLE 1.—(INCLUDING ALL TUMORS)

| Series. | Fore Brain. | | | Hind Brain. | | | Total. |
|---|---|---|---|---|---|---|---|
| | Verified. | Undoubted. | Presumptive. | Verified. | Undoubted. | Presumptive. | |
| Baltimore | 142 | 71 | 23 | 53 | 34 | 14 | 337 |
| Boston | 192 | 103 | 15 | 81 | 49 | 7 | 447 |
| Total | 334 | 174 | 38 | 134 | 83 | 21 | 784 |

It would appear from this table that supratentorial tumors are between two and three times as numerous as those of the posterior fossa, but it should be pointed out that the forebrain tumors, as classified, include the hypophyseal and pineal growths. Of these there were 39 certified examples in the Baltimore and 89 in the Boston series, including many interpeduncular (suprasellar) congenital tumors and cysts of developmental origin. The present predominance in the clinic of these hypophyseal tumors, and only those are here included which gave neighborhood symptoms, doubtless somewhat modifies the figures from the averages which might pertain in other hospitals.*

The tumors of the hind brain in the above table include all growths involving subtentorial structures, and for the purpose of our present quest, they may be further subdivided into intracerebellar, extracerebellar, and pontile, as in the following table:

TABLE 2.—POSTERIOR LESIONS (MID AND HIND BRAIN)

| Series. | Intracerebellar. | | | Extracerebellar. | | | Pontile. | | Total. |
|---|---|---|---|---|---|---|---|---|---|
| | Verified. | Presumptive. | Suspects. | Verified. | Presumptive. | Suspects. | Verified. | Presumptive. | |
| Baltimore | 24 | 20 | 8 | 22 | 10 | 5 | 7 | 5 | 101 |
| Boston | 45 | 22 | 6 | 34 | 16 | 4 | 2 | 8 | 137 |
| Total | 69 | 42 | 14 | 56 | 26 | 9 | 9 | 13 | 238 |

This tabulation shows that the verified intracerebellar lesions do not greatly exceed the extracerebellar ones (69 to 56), and in fact indicates a much smaller predominance of certified intracerebellar lesions than had been anticipated. A further subdivision of the verified extracerebellar tumors may be made into those which give symptoms indicating an involvement of the nerves in the cerebellopontile angle and those which have not given these recess symptoms. Naturally all of the latter which have not been verified have been included in the list of presumptive intracerebellar tumors in Table 2.

Needless to say, tumors which have obviously originated in pons or cerebellum and have come to secondarily involve extracerebellar structures are not regarded as extracerebellar lesions, though unintentionally one or two of the gliomas whose source of origin was obscure may have become included in this table.

The following table of extracerebellar tumors shows that the verified tumors of the cerebellopontile angle far outnumber (42 to 14) the extracerebellar tumors which originate elsewhere, and, what is more striking, that of the tumors arising in the angle the acoustic tumors outnumber the other certified lesions in the proportion of 30 to 12.

* They represent 27.3 per cent of all the verified tumors, though only 13.6 per cent of the unverified group of 316 cases represent unverified pituitary lesions.

TABLE 3.—EXTRACEREBELLAR TUMORS

| Series. | Tumors of the Angle. | | | | | | | Tumors Elsewhere. | | | | Total. |
|---|---|---|---|---|---|---|---|---|---|---|---|---|
| | Verified. | | | | | | Unverified. | Verified. | | | | |
| | Acoustic neuroma. | Endotheliona. | Glioma. | Papilloma. | Cyst. | Carcinoma. | Acoustic neuroma "suspects." | Endotheliona. | Angioma. | Osteoma. | Glioma (ependymal). | |
| Baltimore..... | 10 | 0 | 3 | 1 | 0 | 1 | 15 | 1 | 2 | 1 | 3 | 37 |
| Boston..... | 20 | 5 | 1 | 0 | 1 | 0 | 20 | 2 | 1 | 0 | 4 | 54 |
| Total..... | 30 | 5 | 4 | 1 | 1 | 1 | 35 | 3 | 3 | 1 | 7 | 91 |

It was shown by Table 1 that there were, all told, 468 verified lesions in the series, and by Table 2 that 134 of these occupied the subtentorial fossa, so that it may be a fair estimate of the acoustic neuromas to say that they represent approximately six per cent of all tumors and over twenty per cent of those of the posterior fossa.

It is of interest to compare these figures with those compiled by Howard H. Tooth[181] from ten years' records of the National Hospital at Queen's Square, comprising 566 cases, of which 258 or 45.6 per cent were verified. Our own series, with 784 cases and 468 (59.7 per cent) verified, includes 171 pituitary or parapituitary tumors, whereas there were only 2 in Tooth's series. Hence if we eliminate these cases from our list, thus making the two series more nearly equal, there remain 613 cases with 340 or 55.5 per cent verified.

In Tooth's series of 258 verified tumors 30 were tabulated as extracerebellar growths, and of these, 24 were diagnosed as "fibroglioma" or "fibroma," in all probability representing acoustic tumors. In other words, there were possibly 24 (9.3 per cent) of the growths in question in the verified 258 in the National Hospital series, and 30 (8.8 per cent) in the verified 340 in our series (excluding the 128 verified pituitary cases)—figures which are sufficiently close to be dependable. Excluding the hypophyseal and parahypophyseal tumors, therefore, it is safe to say that the acoustic neuromas represent from 8 to 9 per cent of all intracranial tumors.

## Summary

In a series of 784 tumor cases observed to February 1, 1917, the lesion has been verified in 468 instances; 134 of these were lesions in the posterior fossa, involving the mid and hind brain; 56 of these were extracerebellar tumors, and 30 of the extracerebellar lesions arose from the Nervus acusticus. The latter tumors, therefore, represent at least 6 per cent of all tumors.

## CHAPTER III

# CASE REPORTS

### Verified Acoustic Tumors

In the following case reports what appear to be the essential points alone will be extracted from the voluminous notes which constitute the hospital records. The story of each case in this abbreviated form makes uninteresting reading, particularly in view of the great similarity of the cases to one another. However, this of itself is not without a certain interest, for the very repetition of the story, stripped of all but the bare facts relating to the lesion, serves to show how characteristic and unmistakable the symptomatology of the acoustic tumors in the long run may be. As indicated by the initials preceding the hospital numbers, the first eleven cases, observed before September, 1912, are taken from the records of the Johns Hopkins Hospital and the subsequent ones from those of the Peter Bent Brigham Hospital.

The first patient was operated upon eleven years ago with a resultant fatality due to pneumonia. The operation was abandoned in the hope of completing it at a second session, for the situation, as now recalled, brings up a picture of the patient's head insecurely held by an assistant, the anæsthetic awkwardly administered to a subject having respiratory embarrassment, and an inexperienced operator attempting to expose the cerebellum in a wobbly and bloody field.

### Case I

J.H.H. Surg. No. 18640. **A right acoustic neuroma (variously diagnosed) producing cerebellopontile symptoms. Post-operative fatality from pneumonia after a first-stage operation. Autopsy.**

*Jan. 12, 1906.* Admission of Henry S., age 43, an asylum superintendent, referred by Dr. J. T. McPherson of College Point, N. Y., with the complaint of headaches.

**Chronology of symptoms.**—For many years deafness in right ear (character of onset not inquired into but supposed to be due to chronic middle-ear disease).

For three years attacks of sudden intense suboccipital pain, occasionally radiating through to orbit and accompanied by a sensation of weakness in the legs, so that he would sink to his knees. These paroxysms have recurred at irregular intervals: they are of variable duration. They usually provoke yawning, which appears to relieve the attack.

For some time neuralgic pain in the left infra-orbital region, for which teeth have been extracted without relief. There has been increasing unsteadiness of gait and he observed that as long as he was moving forward he did fairly well, but on stopping or turning he would have to sit down else he would fall.

For some months progressive failure of vision, some mental impairment, thickness of speech. No history of vomiting. For past month too unsteady to rise from bed.

**Positive neurological findings.**—(A) *General pressure.* Bilateral choked disc with secondary atrophy nearly complete on right, where light reaction practically lost. Relative anosmia. No X-ray studies. Deep reflexes exaggerated and equal.

Fig. 3.—Case I. Showing the foraminal herniation of cerebellum (pressure cone) which may be produced by a recess tumor.

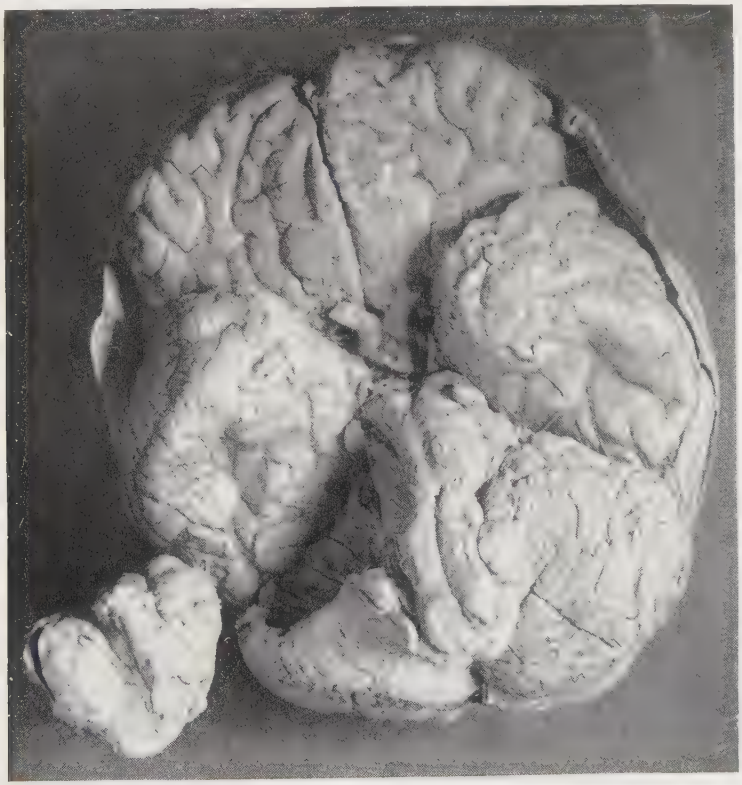

Fig. 4.—Case I. Showing the tumor removed from its bed. Note the characteristic villous herniations over the tips of the temporal lobes: also the typical deformation of the pons and the tumor nest in the cerebellar hemisphere from which the growth has been removed.

(B) *Localizing.* (1) *Cerebellar.* Nystagmus pronounced. Gait very unsteady: especial disability of right side. Romberg positive: falls backward. Coarse ataxia right hand and foot.

(2) *Extracerebellar. Cerebral nerves.* $V^{th}$ = Hypæsthesia to all forms of sensation on right (no note on corneal reflex). Jaw deflects to right. $VI^{th}$ = Internal squint on right. $VII^{th}$ = No evident motor involvement: some loss of taste on right anterior two-thirds of tongue.

$VIII^{th}$ = Complete deafness on right to all forks (AC and BC) and voice sounds, but middle tones of Galton whistle can be heard. No X-ray of porus.

$IX^{th}$, $X^{th}$, $XI^{th}$ = Dysarthria and right ageusia. $XII^{th}$ = Tongue protrudes to right (probably motor $V^{th}$—*cf.* position of jaw).

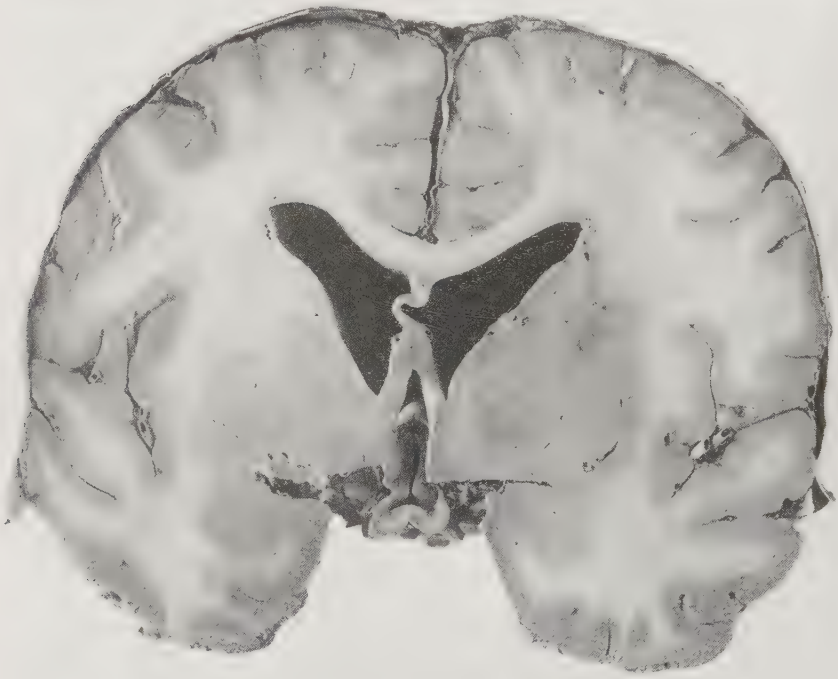

Fig. 5.—Case I. Showing the degree of hydrocephalus produced by an acoustic tumor (reduced).

**Clinical diagnosis.**—Cerebellar tumor. Presumable site not noted.

*Jan. 18, 1906.* **Operation.**—Attempted suboccipital exploration. The anæsthetic was badly taken: irregular and labored respiration with cyanosis was present from the outset. This forced an abandonment of the procedure before the exposure of the cerebellum had been completed. He succumbed to a post-operative pneumonia on the third day.

**Autopsy.**—Anatomical diagnosis: Pneumonia and cerebellopontile tumor. The brain, removed after fixation *in situ,* shows a marked foraminal pressure cone (Fig. 3). No note concerning the condition of the porus acusticus. An enucleable tumor in the right lateral recess (Fig. 4). Relation of tumor to nerves not particularly noted. The growth has produced a marked secondary hydrops ventriculorum (Fig. 5).

Histological report (Mallory): "Dural endothelioma: dense and slowly growing." From another section a diagnosis was made of "glioma," as structures suggesting glia fibrils were observed. Still another section examined elsewhere was regarded as a "fibroma."

A re-examination of the tumor at the present time shows no evidence on its surface of a defect corresponding with a broken attachment in the auditory meatus. The tumor has rather an unusual shape with a central groove (Fig. 6). It measures 4 by 4 by 3½ cm.

The sections show most beautifully the palisade or regimental alignment of the nuclei in the fibrous zones (Figs. 7 and 8). In many areas there are whorl arrangements of the cells. The tissue in some sections is almost entirely fibrous, but in others a reticular tissue with occasional round cells predominates (Fig. 9). There are swollen cells filled with a lipoid substance and the fibrous bands show some œdema.

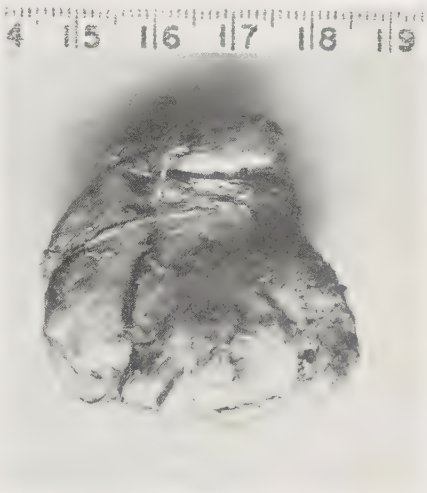


Fig. 6.—Case I. The tumor (nat. size).

**Diagnosis** (1916).—A typical acoustic neurofibroma.



Fig. 7.—Case I. Showing bundle of interlacing fibrous bands with marked palisade arrangement of nuclei; surrounding reticular area (× 80).

**Comment.**—From our present standards the clinical notes on this case are very incomplete and it is only incidentally mentioned, in connection with the examination of the cerebral nerves, that the right ear had been deaf for many years. There is no note as to the presence or absence of tinnitus or of possible vertiginous attacks, but it is of interest that deafness was not absolute. This of course was before the days of satisfactory labyrinthine tests.

The general symptoms were very advanced, with pronounced secondary pressure manifestations and, what was so often true of patients with brain tumors seen in the clinic a decade ago, near blindness had supervened before recourse to an operation was contemplated.

This was my first surgical experience with a recess tumor, and indeed one of the first with a cerebellar exposure for any purpose, and the outcome was



Fig. 8



Fig. 9

Figs. 8, 9.—Case I. Showing (× 300) the fibrous area with palisade arrangement of nuclei separated by zones of collagen fibrils. On the right, typical reticular tissue.

not encouraging, for the difficulties of position and of anæsthesia seemed almost insurmountable. The experience proved a valuable one, however, for it led to the development of the outrigger with shoulder supports which has since been utilized in all subsequent posterior operations, as will be told in a later chapter.

The confusions relating to the histology of the lesion are, from our present point of vantage, interesting to look back upon, particularly as the characteristic nuclear arrangements in this tumor are so striking. The designation of fibroma was a most natural one.

---

The following case likewise was far advanced and the patient had been subjected before admission to various so-called decompressive cranial procedures in the hope of checking the progressive loss of vision.

## Case II

J.H.H. Surg. No. 18939. **A left acoustic tumor with an advanced local syndrome and general pressure disturbances which had progressed to blindness. Three previous decompressive operations. Partial removal of tumor. Survival three years, eight months.**

*Mar. 25, 1906.* Admission of Albert H. G., age 25, a salesman, recommended by Dr. Frederick Greenbaum of West Frankfort, Ill., with the complaint of "brain tumor."

Trauma eight years or more ago; a fall striking left occiput producing a superficial scalp wound; no serious after-effects.

**Chronology of symptoms.**—For several years defective hearing in the left ear (significance not appreciated). First symptoms associated with existing malady began nine months ago, with dizziness and a sense of rotation, and ringing noises with pulsation in the left ear. He soon noticed a difficulty in climbing stairs and that he "could not walk straight." This was followed by a marked unsteadiness of gait, ascribed to weakness of the left leg. Soon the left arm and hand became involved. Some suboccipital headaches; never severe: subsiding under iodides. Periods of diplopia, and for past month rapid failure of vision, with complete blindness five days before admission.

**Treatment before admission.**—A prolonged course of iodides. On *February 10* a trephine opening over left cerebellar hemisphere without incision of the dura: no relief. On *March 7* another opening over right cerebellar hemisphere with dura unopened. On *March 17* an osteoplastic flap over right cerebellar region with puncture and withdrawal of fluid: dura intact. On same day a small subtemporal decompression with incision of dura: wound not completely healed.

**Positive neurological findings.**—(A) *General pressure.* Optic atrophy with blindness secondary to choked disc. Protrusion of recent small subtemporal decompression. No present headaches or vomiting. No X-ray studies.

Deep reflexes exaggerated with possible increase in left over right: superficial plantar normal.

(B) *Localizing.* (1) *Cerebellar.* Nystagmus, coarser excursions to left. Conjugate movements to either side poorly sustained. A coarse ataxia of entire left side of astonishing degree. Gait and station impossible to test.

(2) *Extracerebellar. Cerebral nerves.* $V^{th}$ = Hypæsthesia over entire left trigeminal field: areflexa cornealis. Jaw deflects to left. $VI^{th}$ = Negative: history of diplopia. $VII^{th}$ = Weakness of expressional movements on left: imperfect winking reflex. Taste not tested.

$VIII^{th}$ = Complete left deafness. No X-ray: no caloric tests.

$IX^{th}$, $X^{th}$, $XI^{th}$ = Considerable dysarthria. $XII^{th}$ = Tongue protrudes to left (probably from trigeminal motor palsy and deflection of jaw).

**Clinical diagnosis.**—Tumor of left lateral recess.

*April 3, 1906.* **Operation.**—Through a "cross-bow" incision giving a bilateral exposure with chief removal of bone on the left, the angle was well exposed. The growth, together with the cerebellar hemisphere, which had been covered by a protecting pledget of cotton, were both retracted to the right so that the lesion, which at first was completely overlooked, was not seen until the search, which had been carried nearly to the auditory meatus, was about to be abandoned. A nodular, encapsulated, movable growth was finally disclosed. In the attempt to enucleate it intact, it was broken in two and possibly only about its lower half was removed. The upper fragment was left in place.

**Post-operative notes.**—The patient made a good surgical recovery despite a temporary increase in his dysarthria with some difficulty in swallowing. There was otherwise no change in the local neurological findings. The wound healed *per primam.* He was discharged *April 26, 1906.*

**Pathological note.**—Sections of the tissue show for the most part a fibrous basis (Figs. 10 and 11) with some tendency in places to palisade and whorl formation. There are large

areas of sparse round cells in a reticular meshwork. Many of these cells are large with abundant protoplasm containing a large nucleus, and they suggest ganglion cells.

**Subsequent notes.**—The patient was lost track of until the appearance of a paper by

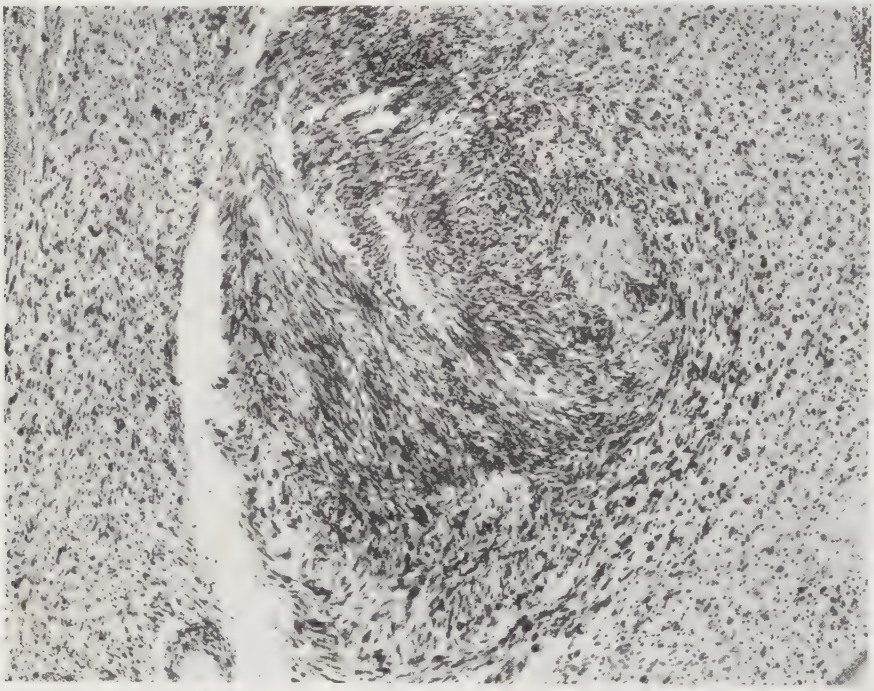

Fig. 10.—Case II. Showing interlacing fibrous bands in the center of the field with zones of the loose reticular tissue to the right and left (× 80).

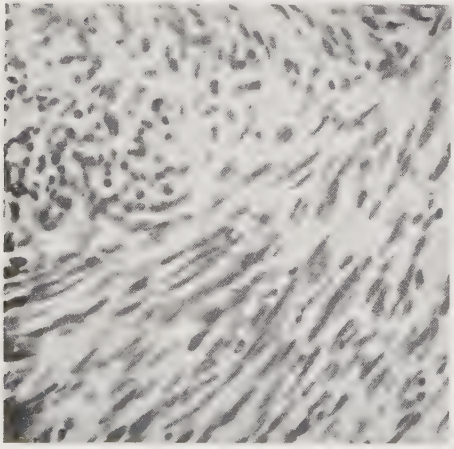

Fig. 11

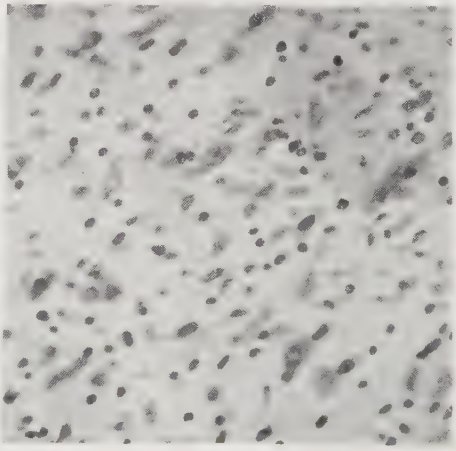

Fig. 12

Figs. 11, 12.—Case II. Showing interlacing fibrous bands and area of young fibrous tissue with nuclei of varying sizes surrounded by cytoplasm (× 300).

Dr. Julius Grinker in 1910,[76] in which his case was reported. His death occurred suddenly while conversing over the telephone on *Dec. 2, 1909*, three years and eight months after the operation. "He had a peculiar seizure, in which he fell backward, striking the ground with his head and becoming unconscious." Coma supervened and he died in two hours.

Postmortem examination showed a recent hemorrhage filling the subarachnoid cyst around a large growth, obviously, from the photograph, an acoustic tumor. The growth was reported to be a "glioma."

**Comment.**—This is one of the few cases in which there was a definite history of local injury. In this respect the acoustic tumors differ from many other forms of intracranial tumor, particularly the endotheliomata, in which trauma so frequently figures as an apparent predisposing cause. The significance of the initial auditory disturbances was not appreciated when this patient was seen, and it is not improbable that they were of long standing and accompanied by vertiginous attacks. These matters were not thoroughly inquired into, and the fact of his unilateral deafness was only casually mentioned among the notes of the physical examination.

With our present experience it is quite possible that a total enucleation of this favorable tumor might have been accomplished.

The following is another example of an advanced tumor with the patient nearly blind at the time of the operation.

## Case III

Private Hospital. **A right cerebellopontile syndrome of four years' duration, becoming advanced. Bilateral suboccipital decompression and partial removal of growth. Survival three years, seven months.**

*Sept. 14, 1906.* Jane L., aged 42, a patient in the care of Drs. J. J. Putnam and E. A. Codman of Boston.

**Chronology of symptoms.**—1902: Deafness of right ear. 1903: Ataxia of right hand, so could not write or sew. Dizziness brought on by dancing. Soon dragging of right foot noticed. Occipital headaches.

1904: Beginning loss of vision with "blind spells."

1905: Practically complete loss of vision and hearing. Later marked dysarthria. Diagnosis of brain tumor made.

1906: Vomiting. Amenorrhœa. Prolonged antiluetic treatment.

**Positive neurological findings.**—(A) *General pressure.* Choked disc with secondary atrophy. Light perception only retained. No X-ray studies.

(B) *Localizing.* (1) *Cerebellar.* Suboccipital pain and tenderness. Nystagmus: slower to right. Marked incoördination of right arm. Gait and station not tested: patient bedridden.

Deep reflexes greatly increased. Slight hypæsthesia of left side of body.

(2) *Extracerebellar. Cerebral nerves.* $V^{th}$ = Slight hypæsthesia of right face and mucous membranes. $VI^{th}$ = No note. $VII^{th}$ = Slight expressional weakness on right.

$VIII^{th}$ = Complete right nerve deafness. No caloric tests.

$IX^{th}$, $X^{th}$, $XI^{th}$ = Characteristic dysarthria. $XII^{th}$ = Tongue in mid line.

*Sept. 15, 1906.* **Operation.**—Bilateral suboccipital craniectomy. Easy exposure of growth in right recess. Intracapsular extirpation of large portion of tumor. Closure without drainage.

**Post-operative notes.**—Convalescence was uninterrupted. There was marked improvement in her symptoms—even in her vision—according to letters received. The wound must have been insecurely closed, for the protrusion became large, especially on the right side. By December the ataxia had subsided sufficiently to enable her to feed herself and she was able to walk without assistance.

**Subsequent note.**—She lived in comparative comfort, with preservation of some vision and good health for over three years, until *April 28, 1910,* when after a few days of some deglutitory difficulty sudden death occurred from respiratory failure.

**Pathological note.**—An autopsy was performed and a portion of the hind brain together with the growth was forwarded for examination. As the tumor had not been fixed *in situ,* the gross anatomical relations, aside from the fact that the lesion occupied the recess, were largely lost. The tumor (Fig. 13) is unusually large for an acoustic tumor and weighs 71 grams. It shows no sign of the original seat of the partial enucleation, but there is a defect on the outer surface corresponding with what must have been the situation of the porus.

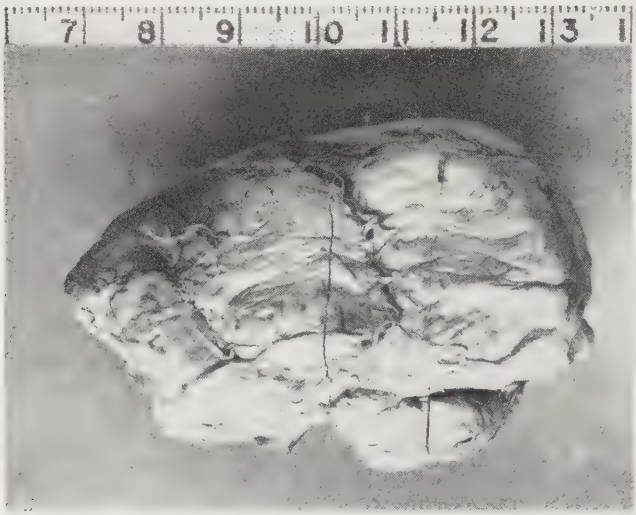


Fig. 13.—Case III. Showing size (71 grams) which may be attained by an acoustic neuroma when room for growth is afforded by a decompression. (*Cf.* Fig. 4.)

The surface of the growth is otherwise intact. On section it shows a dense fibrous structure (Fig. 14) with a few minute cystic areas.

*Histological examination* of the tissue shows it to be made up chiefly of dense fibrous bands and whorls. There are some areas of hyaline degeneration and a few distinct patches of the characteristic loose reticular glia-like tissue. In some areas there is considerable hemorrhage. Hyaline degeneration, particularly around the blood vessels, is extensive. (Tissue too poorly fixed for photographic purposes.)

**Comment.**—In view of the advanced symptoms the results in this case were as good as might be expected, with three and a half years of fairly comfortable life. Had the operation been carried out the year before, when the diagnosis was first made, or even a few months earlier, so that the unfortunate woman might have enjoyed life with vision, the results would have been still more gratifying.

It is notable that even after a fragmentary removal with opening of the capsule, the growth showed no tendency to invasion, and this is true of all of these tumors even though, as will be pointed out, they possess suggestive gliomatous elements.

The unusually large size which the growth attained was doubtless permissible owing to the decompression. The growth may be contrasted with that

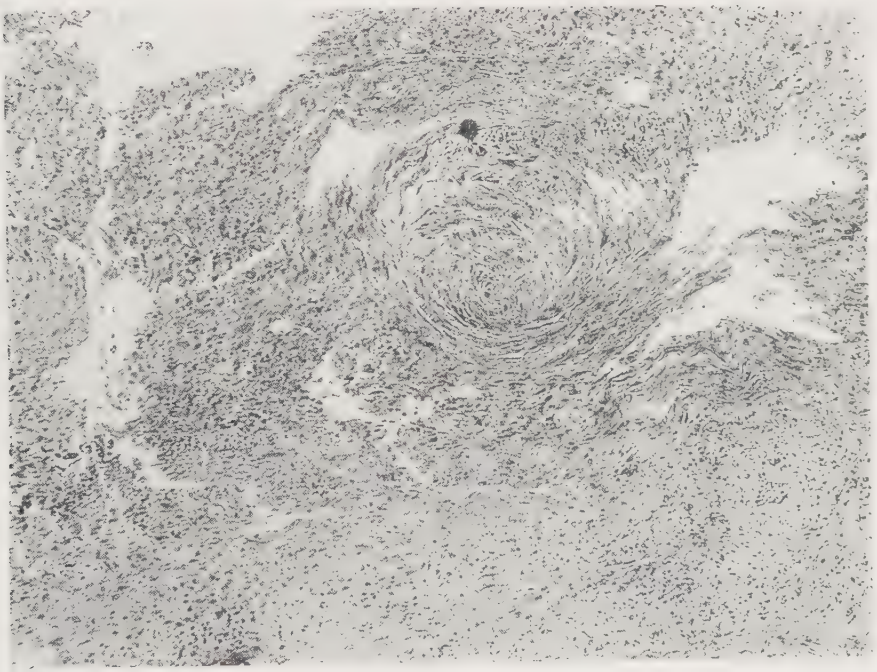

Fig. 14.—Case III. Low power (× 80) of poorly fixed specimen, showing, however, characteristic fibrous structure.

of Case I (Fig. 4), which was about as large as may be accommodated within an unopened skull without producing fatal compression.

A long interval elapsed between the foregoing and the next experience with the attempted exposure of one of these tumors. During this three years' period, according to my records, out of seventy-seven cases with a diagnosis of intracranial tumor there were eighteen cerebellar lesions, and the diagnosis was histologically verified in twelve of these eighteen cases, all intracerebellar but one—a choroid papilloma of the lateral recess.

Of the remaining six, in four a presumptive diagnosis of cerebellopontile tumor was made, and a present review of the histories makes this diagnosis still seem to be the most probable one, but as they all recovered following the negative suboccipital exploration and decompression the diagnosis remains unverified. One of the four cases, owing to the practical certainty of the

clinical diagnosis even though no fragment of the tumor was removed to certify its histological nature, may be worth including here, for it gives an opportunity of enlarging on the hazards of these explorations when they are undertaken after evidences of medullary implication have appeared.

Even with our present experience with the clinical identification of these lesions and their surgical exposure we may occasionally fail to disclose the tumor at the time of operation, as some of the cases of the 1915–1916 series will show.

### Case IV

J.H.H. Surg. No. 23706. **Advanced left cerebellopontile-angle syndrome with medullary implication. Operation under artificial respiration. Evacuation of arachnoid cyst capping tumor. Recovery.**

*Mar. 4, 1909.* Admission of Mrs. F. S. McC., age 49, referred by Dr. George S. Eyster of Rock Island, Ill.

**Chronology of symptoms.**—For nine years (since 1899) a loss of hearing on the left, with early tinnitus, vertigo, and a back-and-forth movement of objects with the sensation of falling, regarded as Ménière's syndrome.

Seven years ago fluctuating paræsthesias, chiefly of left face, but at one time said to have involved the entire left side of the body. These sensory disturbances subsequently subsided.

For four years paroxysms of suboccipital pain brought on by exertion or excitement and of late accompanied by nausea and vomiting.

For two years, dimness of vision: increasing: worse in right eye.

For one year there has been some paræsthesia ("burning") of the right face as well as the left: a relative anosmia: occasional diplopia: a lowered sense of taste.

Of late there have been marked dysarthria and dysphagia, and so-called "vagal" or "cerebellar" attacks have been a pronounced feature. They occur nearly every hour, with considerable retraction of the neck and pain radiating down the spine. Latterly some of these attacks have been very critical, with profound alteration of the pulse, which may register as low as 44 and with Cheyne-Stokes respiration. Any effort accompanied by straining will precipitate an attack.

**Positive neurological findings.**—(A) *General pressure.* Marked extracranial vascular dilatation. Bilateral exophthalmos. Choked disc: more advanced on right, 3½ D.: left, 1 D.: macular exudates. Vision 18/40 O. D.: 15/40 O. S. Anosmia. No X-ray studies.

(B) *Localizing.* (1) *Cerebellar.* Head tilted toward left mastoid. Suboccipital tenderness and stiffness, with cerebellar attacks. Nystagmus: coarser to left. Ataxia of left hand. Deep reflexes equally exaggerated with tendency to clonus. Tests for gait and station not possible. A history of deviation and falling to left.

(2) *Extracerebellar. Cerebral nerves.* $V^{th}$ = Hypæsthesia over skin and mucous membranes of left trigeminal area. Paræsthesia on right. No deflection of jaw. $VI^{th}$ = Negative: a history of diplopia. $VII^{th}$ = Facial weakness on left.

$VIII^{th}$ = Deafness complete on left. No labyrinthine tests.

$IX^{th}$, $X^{th}$ and $XI^{th}$ = Dysarthria and dysphagia: vagal attacks with slow pulse (?). $XII^{th}$ = Tongue protrudes to left.

(3) *Medullary.* Attacks of respiratory difficulty with slow pulse: pressure cone effects (?).

**Clinical diagnosis.**—Left extracerebellar tumor.

*Mar. 6, 1909.* **Operation I.**—*Bilateral cerebellar exposure. Cessation of breathing: operation continued under artificial respiration. Release of pressure cone after forty minutes. Resumption of spontaneous respiration. Closure.*

The patient had one or two of her serious attacks during the preparation for operation, and soon after the procedure was started she ceased breathing. Artificial respiration by Schäfer's method, without change of position, was instituted and the opera-

tion was resumed with no further anæsthesia. The usual bilateral defect was hurriedly made with removal of the posterior margin of the foramen. There was troublesome bleeding throughout owing to the venous stasis.

The dura was widely opened and the incision was carried down in the median line to the upper margin of the atlas. The cerebellum protruded markedly, and its herniated lips, which constituted a marked pressure cone, were then gently drawn up from the spinal region and a large amount of fluid escaped from the spinal canal. Spontaneous respiratory movements were immediately resumed, the interval of artificial respiration having been just forty-five minutes, during which period the pulse rate had slowed from 120 to 80 beats.

In a moment or two the patient began to respond to questions. Further exploration seemed inadvisable, and under primary anæsthesia the wound was securely closed.

**Post-operative notes.**—There were no complications. There was an immediate im-

Fig. 15 Fig. 16

Figs. 15, 16.—Case IV. Photographs on patient's discharge, four weeks after operation.

provement in her pressure discomforts and a fairly rapid subsidence of the choked disc. No further "vagal" attacks occurred. There was a marked gain in other respects and a month later she was able to walk about with some support. The notes say that there was a slight subjective return of hearing in the left ear, but no tests were made to verify this.

*April 23, 1909.* **Operation II.**—*Exposure and evacuation of large cyst of left recess.* The wound was reopened. Cerebrospinal fluid was secured from the spinal region, releasing the pressure cone sufficiently to permit of a moderately free exploration of the left recess. A bulging, somewhat thickened arachnoid membrane such as usually caps a recess tumor was encountered and a large amount of clear fluid was evacuated on puncturing it. No further effort was made to expose the underlying tumor and the wound was again closed without a drain.

**Post-operative notes.**—No complications. Healing again without reaction (Figs. 15, 16). Her general condition improved greatly and she was discharged May 28, 1909, at

which time there were still some dysarthria, nystagmus, unsteadiness of gait, clumsiness of the left hand, and persisting left deafness.

**Subsequent notes.**—*Oct. 15, 1913.* Reports for examination after four years, showing slight abducens palsy and complete left deafness. Also anosmia. Romberg positive and gait somewhat unsteady, particularly when turning, but she does remarkably well. "General health never better."

*Aug. 22, 1916. Readmission for examination* after seven years: continues well and active despite some unsteadiness of gait. Complete paralysis of the acusticus persists. No reaction to caloric tests. The X-ray examination shows marked secondary changes in the sella (Fig. 17) and pressure absorption of the pyramidal bone, with apparent enlargement of the porus acusticus internus.

FIG. 17.—Case IV. Showing marked secondary sellar absorption and what was regarded as a dilated porus acusticus internus. External and internal meatus superimposed and condition impossible of interpretation without stereoscopy.

**Comment.** There are three particularly notable features of this story. One concerns the so-called cerebellar seizures, characterized by radiating suboccipital pain, retraction of the neck, and occasionally by extreme opisthotonos and loss of consciousness. In only one other case of the cerebellar series have similar tonic seizures been equally pronounced (Case XXXVI), though in lesser degree several of the patients have suffered from them. To what these attacks may be attributed is not entirely clear, nor whether they are related to Jackson's tonic "cerebellar fits" which he observed in connection with tumors of the vermis, or to the seizures described by Mills, but it is my impression that the attacks under consideration are of medullary

origin. It is true that they are associated with a slowing of pulse and respiratory difficulties, which may justify Starr's designation of "vagal" attacks, but it hardly seems probable that a unilateral irritation of the vagus could account for them, and it is also probable that pressure upon the group of nerves at the jugular foramen sufficient to produce such symptoms would be accompanied by a vocal cord paralysis and by symptoms referable to the accessorius, both of which are rare.

I am inclined to attribute these seizures to changes in fluid tension in the cerebellar cisternæ, but, whatever may be their actual cause, they are most distressing things to see, for they are accompanied by excruciating pain and a sense of impending dissolution. They have been produced, in the cases that I have seen, by the slightest physical effort, such as that required to change the position or to evacuate the bowels, or by the act of coughing, and are somewhat similar in this respect to the accession of root symptoms which may accompany spinal cord tumors during similar acts.

The second matter of chief interest in this case concerns the conduct of the operation under artificial respiration. Fortunately in the face-down attitude on a cerebellar table having a properly constructed outrigger, the position is an ideal one for Schäfer's method of artificial respiration.

It might be assumed that intratracheal anæsthesia would be desirable in all these cases, particularly when deglutitory disturbances or dysarthria foretell the likelihood of a difficult and hazardous anæsthetization, and Heuer[83] advocates this as a routine method. However, if intratracheal anæsthesia is to be used, the patient must be anæsthetized before being placed on the table and rather profoundly anæsthetized before there is sufficient relaxation to introduce an intratracheal tube. Usually these operations are well under way before such a stage of anæsthetization is reached, and I believe that in the long run the importance of having the patient in a comfortable position on the table before the anæsthesia is started far outweighs the possible advantage of having an intratracheal tube in position in case artificial respiration should be needed.

There have been in the series of cerebellar cases a number of similar experiences, none of them, however, in connection with cerebellopontile tumors. In one patient, whose respiration had suddenly ceased in the ward the day of admission, artificial respiration was immediately instituted and an operation hurriedly prepared for and performed, with resumption of spontaneous breathing on the evacuation of a gliomatous cyst after fifty minutes of artificial respiration: this occurred eight years ago and the patient recovered and is still living.

The third matter of interest concerns the dilatation of the porus acusticus internus disclosed on her recent admission, seven years after the operation, a finding which serves greatly to strengthen the presumptive diagnosis in this particular case, though, unfortunately, despite Henschen's hopeful views, it proves, as we shall see, to be a condition difficult of demonstration in patients with acoustic tumors.

---

Such as it was, the experience gained by the partial subcapsular extirpation of the growth in Cases II and III, though the operation as a whole

amounted to little more than a decompression, nevertheless encouraged me to attempt a more radical excision in the following case:

## Case V

J.H.H. Surg. No. 24119. **Left acoustic tumor invading the cerebellopontile angle. Symptoms of long duration. Operation with intracapsular extirpation. Recovery. Return of symptoms. Second operation after three years. Recovery.**

*May 19, 1909.* Admission of Mrs. A., age 33, referred by Drs. M. J. Synnott and M. Allen Starr of New York, with the diagnosis of cerebellar tumor.

**Chronology of symptoms.**—Since 1902 has had poor health: was considered a neurasthenic. Occasional periods of unsteadiness of gait and headache. In 1904 blurring of vision with diplopia. In 1905 a period of severe pain in left suboccipital region, with cervical stiffness, lasting for several months. These symptoms all subsided.*

Fig. 18.—Case V. Site of operation after 3 weeks.

In 1907 her present group of symptoms began with daily periods of left tinnitus ("noise of a sea-shell" and later of "escaping steam"), accompanied by severe bitemporal headaches. Patient pregnant at the time. She miscarried and the attacks disappeared for three months: reappeared for a time: again subsided.

In *May, 1908*, "optic neuritis" and nystagmus were observed, but she was unusually well until the fall, when tinnitus, pain and sense of pressure returned. Since October, 1908, there has been impairment of hearing and more or less unsteadiness of gait and station has been present since the onset of symptoms in 1907.

Of late paroxysms of pain have been associated with cerebellar-like seizures, accompanied by tonic spasms, vomiting, dyspnœa, difficulties of articulation and of swallowing. She has been subjected to the usual course of antiluetic treatment.

---

* These disturbances all seem to have been premonitory. Indeed on careful questioning it appears that she has had some static ataxia for thirteen years, for at that time (1896) she attempted to learn to play golf but was unable to stand steadily enough to address the ball.

**Positive neurological findings.**—(A) *General pressure.* Bilateral choked disc of 5 D. Dilatation of extracranial vessels. No X-ray studies.

(B) *Localizing.* (1) *Cerebellar.* Forced flexion of neck painful. Nystagmus, coarser to left. Conjugate movements to left fatiguing. Positive Romberg. Staggering gait with deviation to the left and falling. Considerable incoördination of left arm.

(2) *Medullary* (?): Weakness of left arm and leg and paræsthesia of left arm and thigh. Definite "cerebellar seizures." Deep reflexes hyperactive and equal.

(3) *Extracerebellar. Cerebral nerves.* $V^{th}$ = Negative except for loss of left corneal reflex. $VI^{th}$ = Negative. $VII^{th}$ = Occasional left weakness following paroxysms.

$VIII^{th}$ = Left tinnitus followed by supposedly complete deafness (no accurate tests).

$IX^{th}$, $X^{th}$, $XI^{th}$ and $XII^{th}$ = No detailed observations recorded.

**Clinical diagnosis.**—"Left cerebellopontile tumor."

*May 21, 1909.* **Operation I.**—Bilateral cerebellar exposure. Marked tension. Foraminal herniation. Exposure of tumor in left recess capped by large arachnoid cyst. Attempted complete tumor enucleation: probably subcapsular in upper portion. Very little bleeding. Closure.

**Post-operative notes.**—Primary healing (Fig. 18). Immediate marked improvement subjectively and objectively. Discharged at the end of four weeks "with some return of hearing."

**Pathological note.**—The tumor (Fig. 19) measures 2½ cm. in diameter: largely an intracapsular enucleation with only a portion of the capsule attached. Fragments sent to Dr. Mallory were diagnosed "endothelioma."

Fig. 19.—Case V. The tumor after intracapsular enucleation (nat. size).

On renewed study the tissue shows interlacing bands of fibrous tissue (Fig. 20) with no especial tendency to palisade arrangement of nuclei. Large amount of hyaline change about vessels. Larger part of section composed of sharply circumscribed areas of reticular tissue (Fig. 22) resembling glia, and in one small focus containing definite fibrils.

**Subsequent history.**—The patient continued to do well for the next two years and the case after ten months was reported by Dr. Starr,[173] who then regarded it as the single example in his experience of a tumor extirpation with apparent cure and disappearance of all former symptoms.

She continued to do well until *March, 1912,* when she again became pregnant, and as there was some return of her former symptoms, the pregnancy was terminated in October, at the end of seven months.

Her former cerebellopontile syndrome nevertheless all gradually reappeared with an increase of symptoms over those originally present, and she was admitted to the Corey Hill Hospital for a secondary operation.

*Nov. 19, 1912. Readmission.* Examination discloses marked suboccipital pain aggravated by movement. Occasional vomiting spells. A bilateral choked disc of 5 D. Incoördination so great that she is completely bedridden. Dysphagia and dysarthria of pronounced degree. Involuntaries.

The cerebral nerves on the left from the $III^{rd}$ to the $XII^{th}$ show more or less involve-

ment. The deep reflexes very active throughout, with a positive Babinski on the right. Corneal reflexes absent, both right and left: and a considerable exophthalmos of the left eye.

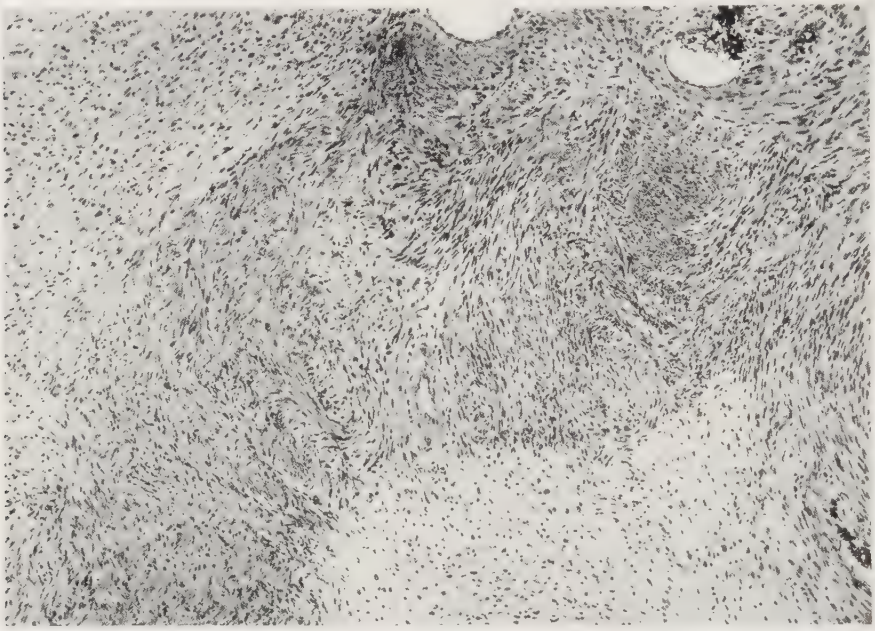

FIG. 20.—Case V. Showing zone of interlacing fibrous bands sharply demarcated from reticular areas (× 80).

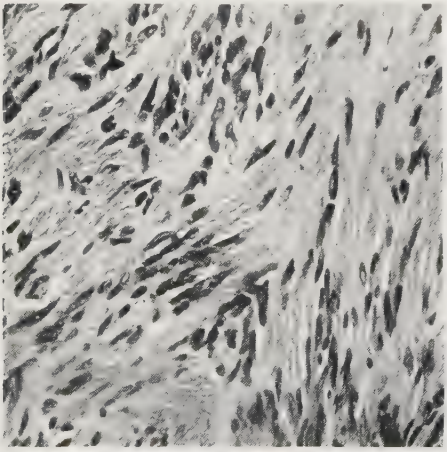

Fig. 21

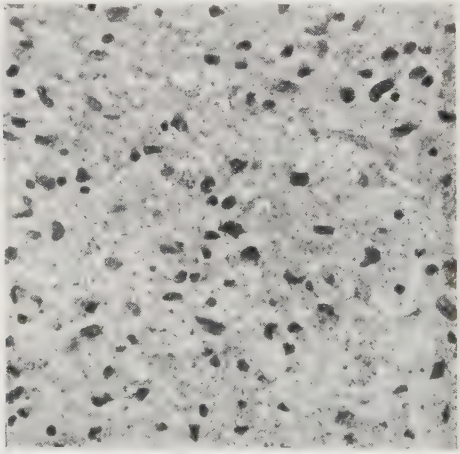

Fig. 22

FIGS. 21, 22.—Case V. Showing architecture of fibrous and reticular areas (× 300).

*Nov. 21, 1912.* **Operation II.**—Usual bilateral exposure. Transection of left hemisphere, exposing tumor. Owing to tension a puncture of the left ventricle was necessitated.

About as extensive an intracapsular enucleation was performed as at the first operation. Closure without drainage.

**Post-operative notes.**—Convalescence unexpectedly uneventful. Healing *per primam.* Marked improvement in all respects. Discharged *Dec. 18, 1912.*

**Pathological note.**—The histological examination of the tissue in comparison with that removed at the first operation three years previously shows a lesion of exactly the same character as before.

**Subsequent notes.**—Though the cerebellar manifestations continued more or less in evidence, she has had a fairly comfortable life. *Oct. 5, 1916* (seven years since the first operation), states that she has gained greatly in weight, walks alone though unsteadily; local symptoms except for deafness much less marked; articulation fair; no headache or vomiting. *Feb. 21, 1917.* Letter from attendant: "All her symptoms have abated, she walks and talks better, is well nourished and her physical status is excellent."

**Comment.**—The case is of special interest in view of the long duration of symptoms—possibly thirteen years—and their fluctuating character with definite periods of remission. Attention may also be called to the exacerbation of symptoms which accompanied her pregnancies, an association which has been observed in several other patients in the brain tumor series.

From a surgical standpoint the result in this case must be considered about as good as may be expected in one of these difficult problems. I can hardly believe that tumors which have reached a size sufficient to make their victims seek an operation are capable of complete enucleation within the capsule, in the way that spinal cord tumors may be enucleated, without the production of such a degree of damage as to leave the patient anything but seriously crippled. It will be seen in the course of relation of the succeeding cases that the extirpation in all has remained largely subcapsular, as it proved to be in this case even though a complete extirpation was undertaken. Whether or not it may be possible to acquire sufficient skill to remove the capsule after the contents have been largely scooped out, I do not know. It has been attempted once or twice with serious consequences. Hence in all cases a continuance of the growth may be expected, but fortunately it takes place slowly. In this particular patient a survival of seven years since the first operation must be considered relatively good. It is the only case in which a second extirpation has been undertaken after so long an interval and it is not inconceivable that a third attempt may in time become necessary.

As in Case II of the series the patient whose history follows had been subjected before admission to an incomplete operation elsewhere, which considerably complicated the ease of exposure, and the adhesions were so extensive as to make a transcerebellar rather than the preferential extracerebellar exposure seem necessary. Like the foregoing, this patient also did well for a period of three years following the intracapsular excision.

## Case VI

J.H.H. Surg. No. 25339. **Left acoustic tumor with cerebellopontile neighborhood symptoms. Previous unilateral decompression. Operation with partial intracapsular extirpation. Survival six years, seven months.**

*Jan. 24, 1910.* Admission of Alphonso J. B., a farmer, age 49, referred by Dr. H. M. Thomas of Baltimore, who first saw the patient in 1907 and then recommended operation.

**Chronology of symptoms.**—For five years auditory symptoms with staggering gait, later accompanied by diplopia and left parageusia. For three years occipital pains and spells of vomiting. For two years numbness of left face and incoördination of left hand and foot. Some neuralgic pains in gums. One year before entrance a suboccipital decompression had been performed by Dr. Stewart Atkinson in Pittsburgh, with considerable temporary relief. Of late some dysarthria.

*Examination* reveals a T-shaped suboccipital scar with a unilateral bone defect and a marked bulging over the left suboccipital region (Figs. 23, 24).

**Positive neurological findings.**—(A) *General pressure.* Bilateral choked disc receding with atrophy; 1 D. left; 2 D. right. No X-ray studies.

Deep reflexes: right not obtained, left inactive.

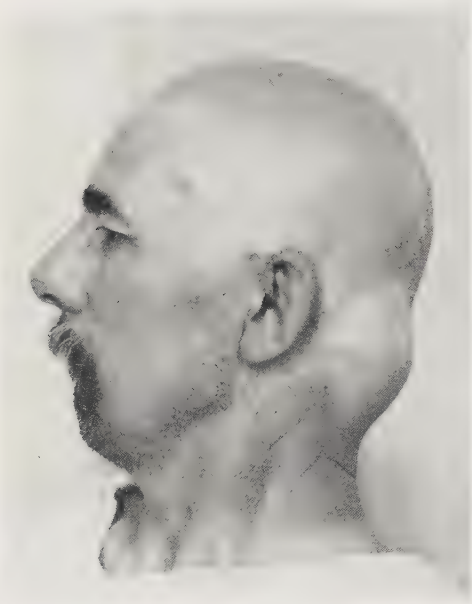

Fig. 23

Fig. 24

Figs. 23, 24.—Case VI. Showing condition on admission: old T-shaped scar with protrusion on left from insecurely closed wound.

(B) *Localizing.* (1) *Cerebellar.* Constant nystagmus, much coarser to left. Romberg with falling apparently always to right. Gait very unsteady. Considerable incoördination of left extremities.

(2) *Extracerebellar. Cerebral nerves.* $V^{th}$ = Numbness of entire trigeminal field on left with corneal areflexa and loss of palatal reflex. Jaw deflects to left. $VI^{th}$ = Negative: history of diplopia. $VII^{th}$ = Slight expressional weakness left face and lowered sense of taste in tongue.

$VIII^{th}$ = Air conduction lost on left; bone conduction present (?).

$IX^{th}$, $X^{th}$, $XI^{th}$ = Considerable dysarthria. $XII^{th}$ = No note.

**Clinical diagnosis.**—Tumor of cerebellopontile angle.

*Jan. 27, 1910.* **Secondary operation.**—The line of the old cicatrix was necessarily followed, making a low T-shaped incision. The bone was removed from over the right hemisphere and also from the posterior rim of the foramen, where a large arachnoid cistern was

evacuated on opening the dura, thus relieving tension. Several large communicating encysted collections of cerebrospinal fluid were found in the left hemisphere, which was transected. At the depth of the incision a dilated cistern which formed a fluid cap over the tumor was brought into view and evacuated. A good exposure of the tumor was secured and a fairly thorough intracapsular extirpation was made. Careful repair in layers of the former insecurely closed wound. No drainage. A prolonged four-hour operation.

**Post-operative notes.**—Uneventful convalescence. Perfect wound healing (Figs. 25 and 26). Immediate improvement in all respects except for persistence of left deafness and nystagmus. Station and gait much better. Discharged *Feb. 24, 1910.*

**Pathological note.**—Diagnosis at the time, "endothelioma." A re-examination of the tissue shows a typical acoustic tumor (Fig. 27) with interlacing fibrous bands (Fig. 28) and interspersed reticular areas (Fig. 29). There are many thin-walled blood vessels and comparatively little hyaline change.

Fig. 25 Fig. 26

FIGS. 25, 26.—Case VI. Three weeks after operation. (*Cf.* Figs. 23, 24.)

**Subsequent notes.**—His condition was very greatly improved and he returned to work. Despite occasional dizziness produced by looking upward and some unsteadiness in gait he considered himself reasonably well for a period of nearly three years.

Early in 1913 there was a return of suboccipital headaches with occasional vomiting and increased instability. He re-entered the Johns Hopkins Hospital *Mar. 4, 1913,* at which time Dr. Dandy's examination showed in addition to definite left cerebellar symptoms a slight haziness of the discs with 20/40 vision, nystagmus slow to the left, poorly sustained conjugate movements to the left; left V$^{th}$ hypæsthesia; slight left facial weakness with loss of taste; left deafness complete; slight dysphagia and equal and active deep reflexes. No further operation was advised.

He died *Aug. 10, 1916,* a few days before the arrival of a letter of inquiry sent in connection with the preparation of this report. For the preceding year there had been a progressive failure.

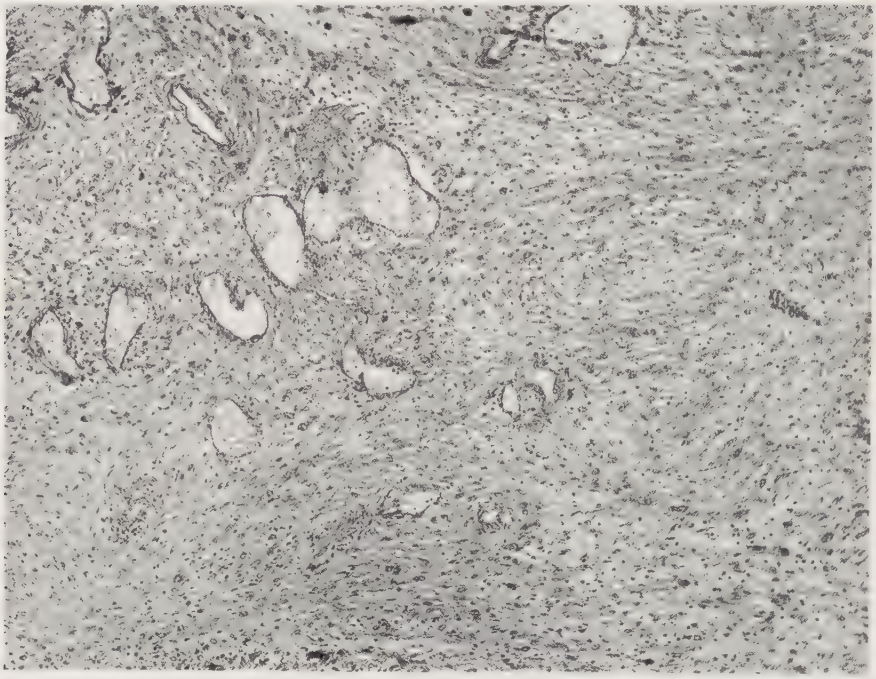

Fig. 27.—Case VI. Showing area of tumor with abundant vessels and hydropic fibrous bands (× 80).

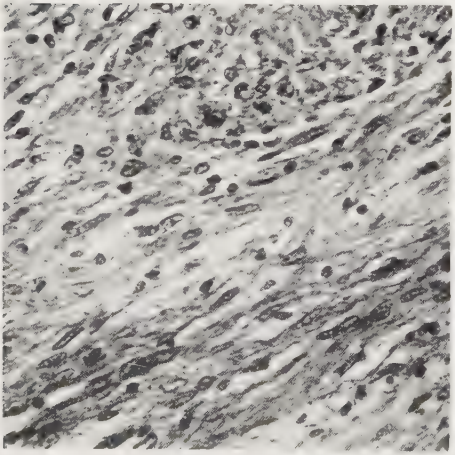

Fig. 28

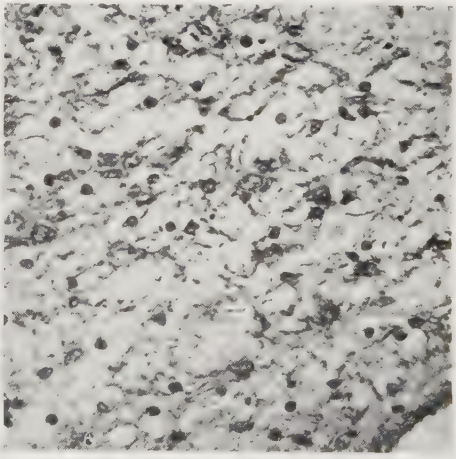

Fig. 29

Figs. 28, 29.—Case VI. Showing œdematous fibrous and reticular areas.

**Comment.**—The fact of a previous unilateral operation made the operative exposure in this case difficult, particularly as the wound had been so insecurely closed as to permit of a large protrusion. This early operation, however, had doubtless served to save vision.

It is worthy of note that the obstructed cerebrospinal fluid had penetrated through the cerebellum, making a large multilocular cyst, and had it not been for the clear rather than straw-colored fluid this could easily have been mistaken for a gliomatous cyst and further search for a recess tumor abandoned.

The patient's survival for six years is probably as long as could be expected without a secondary operation such as was conducted in the preceding case, and it is regrettable that a repetition of the partial enucleation was not undertaken when he reported in Baltimore in 1913. From this and the foregoing case it may be estimated that a wide suboccipital decompression with extensive intracapsular enucleation of the tumor may give a period of three years' relief and that without further measures to relieve the returning symptoms, another three years of failing health may be expected.

---

Reference to the foregoing several cases will make it apparent that auditory symptoms are apt to be the initial ones even though the patients themselves may have attached no significance to this important feature of the chronology. In the following case, however, the tinnitus and deafness, according to the record, did not appear until a year after other symptoms, though possibly the vertiginous attacks, of which the record is not particularly clear, may indicate early symptoms referable to the radix vestibularis. At the time of admission some hearing was still preserved.

## Case VII

J.H.H. Surg. No. 26006. **Small right acoustic tumor. Exploratory operation. Tumor not disclosed. Later cerebral operation elsewhere with fungus cerebri and death. Autopsy.**

*May 26, 1910.* Admission of Nannie S., age 43, referred by Dr. A. E. Morrison of Virginia Beach, Va., complaining chiefly of loss of vision.

The history records that in 1906 she sustained a severe cranial trauma from a fall, striking on the back of the head. An old chronic otitis media on right.

**Chronology of present symptoms.**—Onset 18 months ago with frontal headaches accompanied by paræsthesias of the entire right trigeminal area: these have since subsided. With the more severe headaches there were attacks of vertigo with occasional falling.

During the year she became very unsteady—a drunken gait. Failing vision and diplopia. A gain in weight of forty pounds has occurred since the onset.

For only three or four months have tinnitus and subjective loss of hearing been observed by the patient.

**Positive neurological findings.**—(A) *General pressure.* Bilateral choked disc with secondary atrophy and binasal blindness*: V. O. S. 6/200; V. O. D. 10/20.

(B) *Localizing.* (1) *Cerebellar.* No tenderness, stiffness or suboccipital discomforts. No nystagmus. Station somewhat unsteady with variable tendency to fall to right. Gait

---

* This case has been previously reported with C. B. Walker from this aspect of binasal hemianopsia.[49]

fairly good with but slight staggering. Possible slight incoördination of right hand and arm.

(2) *Extracerebellar. Cerebral nerves.* $V^{th}$ = Corneal areflexa right. Possibly slight hypæsthesia of right face. $VI^{th}$ = Slight weakness left (?): history of diplopia. $VII^{th}$ = Negative.

$VIII^{th}$ = Tinnitus right; central hearing impaired (?), an old chronic otitis media with some retraction of drum. No labyrinthine tests. No X-ray of porus.

$IX^{th}$, $X^{th}$, $XI^{th}$ and $XII^{th}$ = No detailed observations.

**Clinical diagnosis.**—"Presumable right cerebellopontile tumor."

*June 4, 1910.* **Operation.**—Usual bilateral exposure. A normal appearing cerebellum was disclosed: no undue tension. Investigation of the extracerebellar recess on each side failed to disclose a tumor. Closure.

Fig. 30.—Case VII. Condition of the wound at the time of the patient's discharge.

**Post-operative notes.**—The patient improved in all respects except for her vision, which continued to fail. Healing perfect (Fig. 30). Discharged *June 29, 1910.*

Some months later, on the assumption that we had been mistaken in our diagnosis, an exploration of the right cerebral hemisphere was made at her home by other hands. The bone from the flap was removed and an extreme herniation due to the secondary hydrocephalus resulted.

In the next few months she had many convulsions and deteriorated rapidly.

*April 4, 1911.* Readmission in very poor physical state. Loss of forty-five pounds weight. Severe parietal headaches: frequent vomiting: blind. Marked mental impairment with disorientation. Left hemiparesis and asteriognosis. Marked cerebral herniation. Involuntaries.

Though the clinical picture was obviously greatly confused by the secondary operation over the brain, the symptoms referable to the left side were so much more pronounced than those usually seen even with a large and unprotected cerebral hernia that we, too, had misgivings as to the correctness of the earlier diagnosis. An exploration of the right hemisphere was made on *April 10* with negative findings except for an extreme degree of hydrocephalus (250 cc. withdrawn). Tension became subsequently so great that the wound parted, a cerebrospinal fistula developed, and she succumbed to meningitis on *April 30, 1911.*

**Postmortem examination.**—A right acoustic tumor about the size of a hickory nut (Fig. 31) indenting markedly the right side of the pons. Internal hydrocephalus. Many cerebrodural herniations. Post-operative herniation of right hemisphere with cerebrospinal fistula and meningitis.

The surface of the tumor is crossed by three or four branches of the basilar artery, which would have rendered its enucleation without injuring these vessels practically impossible. There is no evidence on the surface of the tumor of any point of attachment of the growth within the porus. The $V^{th}$ and $VII^{th}$ nerves are considerably elongated and lie on the upper

surface of the growth. The VIII$^{th}$ can be detected only at its pontile attachment, where it is quickly lost in the tumor substance. In all probability this tumor arose from the intracranial portion and not from the intracanalicular portion of the nerve.

*Histologically* the tumor (Fig. 32) shows the usual architecture with fibrous bands and areas of reticular tissue (Fig. 34). There are large fields showing hyaline degeneration (Fig. 33), though the hyaline change about the vessels, which are few in number, is not great. There are many hydropic areas with some small cysts. The tumor has undergone extensive fatty infiltration (Fig. 204), and there are many young fibroblasts with distinct cytoplasm and sharply staining nuclei.

Fig. 31.—Case VII. Showing the tumor overlain by branches of the basilar artery (nat. size).

**Comment.**—This, then, is one of the few cases in the series (*cf.* Case XXII) in which acoustic symptoms were definitely recorded as late rather than early manifestations. The tumor was a relatively small one and yet general pressure symptoms, with loss of vision, were advanced. This was probably due to the early obstruction of the iter from the marked indentation of the pons which was found. The cerebellar symptoms were inconspicuous and there was no characteristic nystagmus.

These unusual clinical features led another surgeon to regard the lesion as

Fig. 32.—Case VII. Showing (× 80) fibrous area which has undergone extensive fatty infiltration (phosphotungstic acid hæmatin).

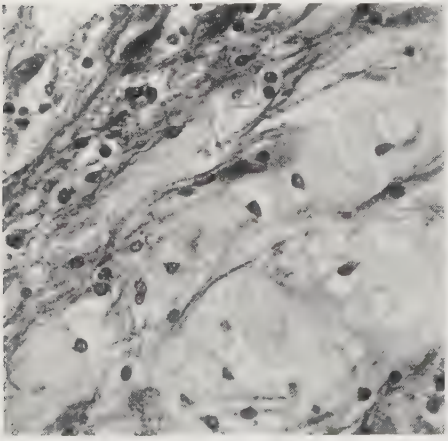

Fig. 33

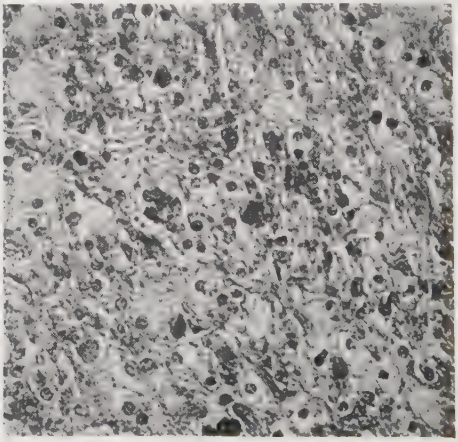

Fig. 34

Figs. 33, 34.—Case VII. Hyaline degeneration in fibrous area: reticular area.

cerebral and after his exploration the symptom complex became so confused as to lead us also into the belief that the original diagnosis might have been erroneous. We shall see later on that mistakes in localization have led many to explore these cases for presumed cerebral symptoms or to decompress them over the cerebrum, as in the example cited by Kennedy,[95] and as in Cases X and XXIV of this series.

On her last admission, frontal symptoms with marked mental impairment were pronounced, a matter which will be considered more fully when the general subject of diagnosis of these lesions is taken up.

The surgical experience shows how easy it is to overlook one of these tumors in a suboccipital exploration, which doubtless accounts for the considerable number of unverified though presumable acoustic neuromas in the series of cases as recorded in Chapter I.

---

The three succeeding cases from a surgical standpoint were most discouraging ones, each of them resulting in an operative fatality due unquestionably to the fact that our comparatively successful partial enucleations in Cases II, III, V and VI had led us to make radical attempts to completely extirpate the growth. The following case is of considerable clinical interest in view of the bilaterality of the cerebral nerve symptoms, which suggested a possible bilateral recess tumor.

## Case VIII

J.H.H. Surg. No. 26651 et seq. **Left acoustic tumor with neighborhood symptoms. Primary operation with prolonged respiratory failure. Two subsequent attempts to extirpate tumor. Death.**

*Sept. 29, 1910.* First admission of Francis P. K., a banker, age 38, referred by Dr. M. Allen Starr, with the diagnosis of a left acoustic tumor.

**Chronology of symptoms.**—Always more or less subject to sick headaches. For two and one-half years has noted deafness in left ear when using telephone: also that stooping produced a throbbing pain in back of head and tinnitus. For two years dizziness and vertigo on arising. For one year, with sudden onset, a reeling gait with deviation to right. Soon a bilateral numbness of the face, with loss of sense of taste: the sensation soon returned on the left and less completely on the right. Of late, morning headaches with vomiting.

*Examination.*—A dark-complexioned young man with a few soft cutaneous fibromas and a number of pigmented moles.

**Positive neurological findings.**—(A) *General pressure.* Early choked disc of two diopters. No note of X-ray studies.

(B) *Localizing.* No stiffness of neck. (1) *Cerebellar.* Nystagmus, coarser to right. Positive Romberg. Gait unsteady with deviation. Sensation of revolution of objects to left on turning head. Slight incoördination of hands. Deep reflexes overactive with suggestive clonus on left and positive Babinski (frequent observation).

(2) *Extracerebellar. Cerebral nerves.* $V^{th}$ = Neuralgic pains in right lower jaw. Subjective sensation of numbness but no hypæsthesia demonstrable except corneal areflexa both sides. $VI^{th}$ = Negative. $VII^{th}$ = Negative.

$VIII^{th}$ = Deafness on left. Both semicircular canals appear to respond to caloric stimuli, though less well on left.

$IX^{th}$, $X^{th}$, $XI^{th}$ and $XII^{th}$ = Observations unrecorded.

**Clinical diagnosis.**—Left cerebellopontile tumor, possibly bilateral with generalized neurofibromatosis. Operation postponed; discharged.

*Jan. 1, 1911. Readmission* owing to increase of symptoms. Accentuation of cephalalgia: pain referred to left forehead. Greater unsteadiness: feels as though "walking a tight-rope and unable to catch himself." A ringing tinnitus in left ear, and on leaning forward a "roaring sensation" like an elevated train. Increased numbness of left face with drooling due to marked dysphagia. Hiccoughing frequent.

*Re-examination* shows a choked disc: now of 7 diopters. Nystagmus greatly increased: oscillations coarser to left. Incoördination (left) more marked. Left facial weakness. Deflection of jaw to left: tongue protrudes to left. Hypæsthesia over entire left trigeminal skin field, with areflexa cornealis. Ageusia on left tongue. Falling backward and to the left. Thickness of speech and dysphagia marked. Deep reflexes active, more so on left: abdominal absent.

Frequent cerebellar seizures with sensation of rush of blood to head and

Fig. 35.—Case VIII. Wound 18 days after second operation.

numb sensation "as though head did not belong to him," followed by left supraorbital pain and nausea. Has twice lost consciousness in these attacks. One of them occurred the morning of operation.

*Jan. 4, 1911.* **Operation I.**—Bilateral suboccipital craniectomy: dura very tense: marked foraminal pressure cone: very little fluid obtained: tumor disclosed in left recess capped by arachnoid cyst: extirpation postponed for a second session: closure: cessation of respiration: artificial respiration continued for some time without avail: wound reopened: median incision carried down to spine of axis and posterior arch of atlas removed: dural incision carried down to top of axis, exposing cord below lower edge of cerebellar pressure cone; abundance of fluid escaped with immediate resumption of spontaneous breathing one hour after its cessation: prompt return of consciousness: wound again closed.

**Post-operative notes.**—There were occasional periods of rhythmic respiration throughout the remainder of the day and he was not removed from the table for many hours. Aside from recurring attacks of prolonged hiccoughing and more or less persistent nausea for several days, the convalescence was far better than expected. Healing was perfect. Subsidence of all pressure discomforts, but neighborhood signs remained as before. Gait and station very unsteady.

*Mar. 6, 1911.* **Operation II.**—Re-exposure of cerebellum and re-evacuation of distended arachnoid cistern in left recess. Good exposure of lower hemisphere of tumor. Attempted complete intracapsular extirpation (as in Case III). A bleeding point at side of pons finally controlled by tissue implantation. Closure.

**Post-operative notes.**—Continued occasional hiccoughing and vomiting with drooling and dysphagia. Convalescence otherwise excellent. Healing perfect (Fig. 35). At the

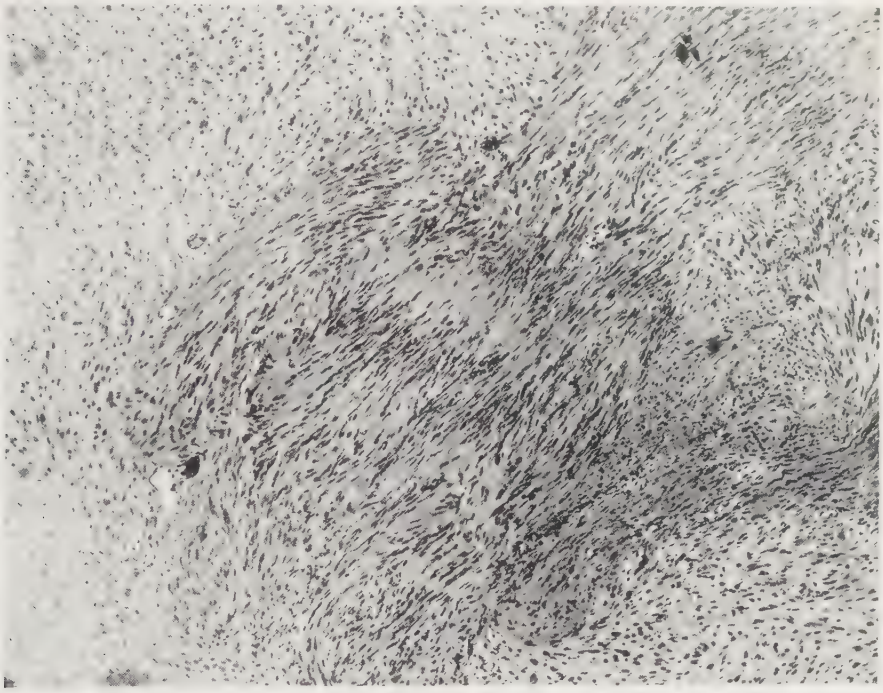

Fig. 36.—Case VIII. Low-power photographs (×80) of typical fibrous bands sharply marked off from reticular areas (phosphotungstic acid hæmatin).

end of three weeks of continued improvement he had a severe upset following an attack of sneezing due to getting some food above his palate.

Under the delusion that removal of the remaining fragment of the tumor might benefit his condition, a final attempt was decided upon.

*April 1, 1911.* **Operation III.**—The wound was reopened: troublesome bleeding from the outset: fall in blood pressure: transection of left cerebellar hemisphere, exposing upper pole of growth. Bleeding from vessels on surface of tumor: incomplete digital enucleation: hemorrhage considerable but finally controlled. Closure.

**Post-operative notes.**—Immediate return of consciousness. Marked increase in cerebellar and cerebral nerve symptoms, with complete V$^{th}$, VI$^{th}$, VII$^{th}$ and XI$^{th}$ paralysis on the left. Gradually increasing stupor with coma and death after thirty-six hours.

**Postmortem examination.** —A small fragment of tumor remains in left recess alongside of the pons, which shows considerable traumatic softening. V$^{th}$, VII$^{th}$ and VIII$^{th}$ nerves torn away during the operation. No tumor in right recess. Internal hydrocephalus.

*Histological* report on a small fragment of the tumor (Mallory): "There is no question but that it is a cellular, fairly rapidly growing dural endothelioma, though misleading owing to its œdematous condition, which changes the appearance of the cells to some extent."

More recent studies (1916) show a typical acoustic tumor with bands of fibrous tissue containing whorls and a tendency of the nuclei to parallel arrangements (Figs. 36 and 37). Sharply circumscribed from this and constituting the larger mass of the tissue is a loose meshwork of cells (Fig. 38), varying in number and size, associated with imperfect glia fibrils (phosphotungstic acid hæmatin stain). The blood vessels in places are numerous, without marked hyaline degeneration. The fibrous tissue in many areas shows extensive hydropic change.

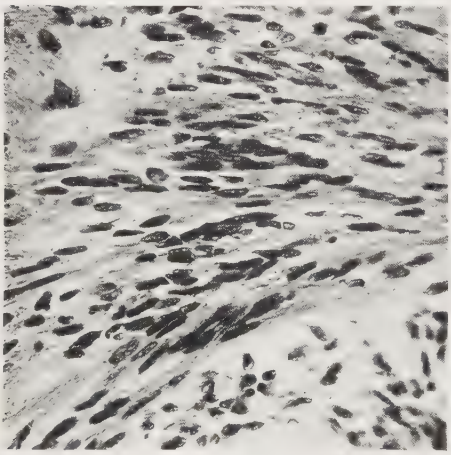

Fig. 37

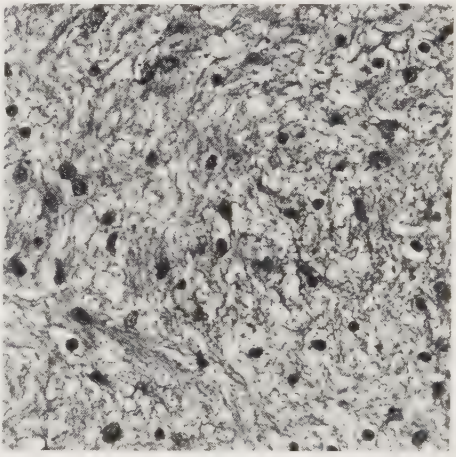

Fig. 38

Figs. 37, 38.—Case VIII. Showing characteristic fibrous and reticular areas.

**Comment.**—This was a disastrous performance which, let us hope, might have been avoided today, for what are now obvious technical errors were committed. At the time, the value of a ventricular puncture when an exceedingly tense cerebellum has been exposed was not appreciated; had it been, it is quite possible that the respiratory failure recorded in connection with the first operation might have been avoided and the tumor possibly exposed with safety at the first session, which is always desirable.

As in Case IV, there was a period of respiratory cessation, though in this instance it did not occur until after the completion of the operation, but it was, so far as I recall, the first experience which I had then had with the liberation of the medulla by removal of the arch of the atlas in order to get below the lower margin of a marked cerebellar pressure cone. In emergencies this may be a life-saving procedure, as I have since had ample opportunity to learn.

It was unquestionably bad judgment to undertake the first operation so

soon after a severe cerebellar paroxysm, though as a matter of fact the operation was precipitated by our anxieties lest there be a repetition of the seizures with a fatality. From our present point of view, not only is a cerebellar operation in two stages far from desirable, but in the light of our existing knowledge the attempt at a total extirpation which was made at the second session is a hazardous and futile one. The experience, however, taught us its lessons.

There is one other matter of some clinical uncertainty which was not cleared up until the postmortem examination—namely, the possibility of a bilateral lesion in connection with a generalized neurofibromatosis, for, as will be recalled, the physical examination revealed a number of cutaneous pigmented moles and soft fibromas. Though the auditory symptoms were unilateral, the bilateral numbness of the face and the pain in the trigeminal region on the side contralateral to the side of deafness made this clinically possible. Unsuspected bilateral tumors have been encountered during or after operation by Horsley, Garré and others. This subject will be taken up more in detail later on in connection with the topic of generalized neurofibromatosis.

The following is another example of early respiratory failure after operation. The foolhardiness of attempting a total extirpation was not yet fully realized despite the experience with Case VIII as just related.

## Case IX

J.H.H. Surg. No. 26742. **A right acoustic tumor with advanced neighborhood and general pressure manifestations. Operation. Attempted extirpation. Early respiratory failure. Death.**

*Oct. 11, 1910.* Admission of Thomas E. B., a farmer, age 30, referred by Dr. J. Norden of Anderson, S. C., with a typical history.

The patient had never been vigorous and suffered more or less from headaches all of his life and for many years from spells of vomiting.

**Chronology of present symptoms.**—For about ten years a gradual loss of hearing on right, with tinnitus "like running water": deafness complete for two years. For four or five years numbness of the right face and unsteadiness of gait. Eye-sight always poor: failed about two years ago with loss of reading vision. A period of diplopia two years ago. Of late considerable mental impairment. Marked loss of weight.

**Positive neurological findings.**—(A) *General pressure.* Choked disc receding with atrophy: very low vision at present. No X-ray studies recorded.

(B) *Localizing.* Marked right suboccipital stiffness and tenderness: holds head tilted to right mastoid. (1) *Cerebellar.* Nystagmus in all directions, slower and coarser to right. Marked static ataxia: unable to stand with feet together even with eyes open. Falls to right. Marked incoördination right. Slight hypæsthesia right side of body: deep reflexes, more active right.

(2) *Extracerebellar. Cerebral nerves.* $V^{th}$ = Right areflexa: trigeminal sensitivity greatly lowered throughout. Jaw deviates to right. $VI^{th}$ = Slight internal squint on right. $VII^{th}$ = Lessened expressional movements on right lower face: lowering of taste perception on right tongue.

$VIII^{th}$ = Deaf to air conduction right: no labyrinthine tests recorded.

$IX^{th}$, $X^{th}$, $XI^{th}$ and $XII^{th}$ = Recorded as negative.

**Clinical diagnosis.**—"Right cerebellopontile tumor."

*Oct. 17, 1910.* **Operation.**—A large right recess tumor extending somewhat lower than

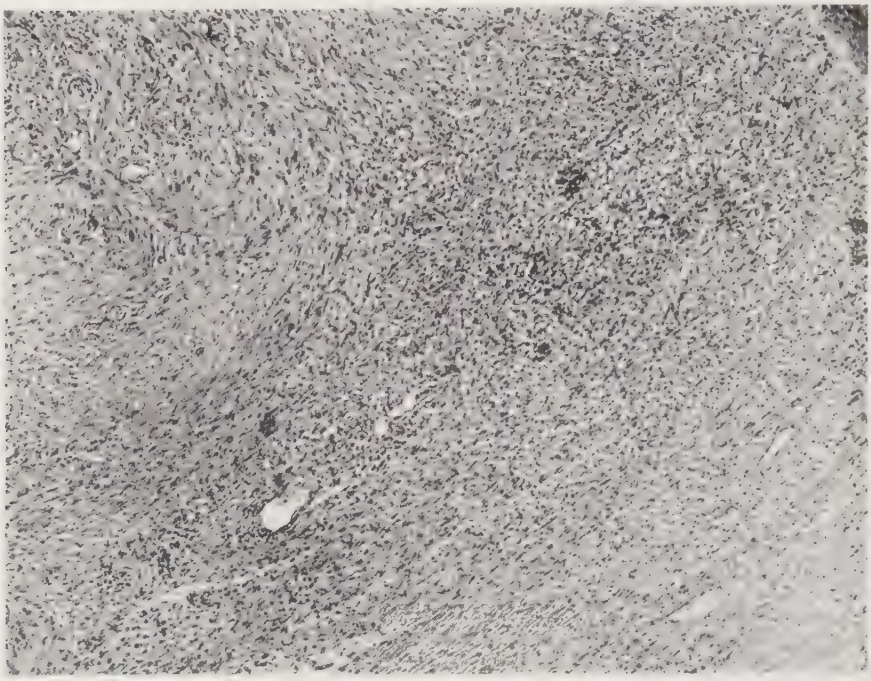

Fig. 39.—Case IX. Showing (× 80) the fibrous area of the tumor with marked hydropic change (hæmatoxylin eosin).



Fig. 40

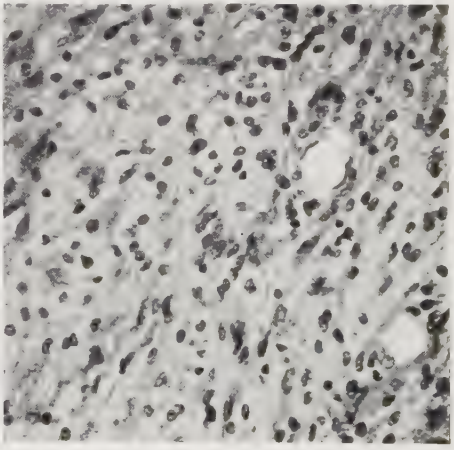

Fig. 41

Figs. 40, 41.—Case IX. Œdematous bands showing fibroglia fibrils: reticular area (× 300).

usual and covered by large vessels was readily exposed. A total enucleation was attempted but was abandoned owing to a tendency to bleeding. An extensive intracapsular extirpa-

tion was then made. The wound was closed and there was a prompt recovery from the anæsthetic.

The moment he was taken from the table, however, and turned on his back to apply the final dressings, respiration ceased. He was replaced on the table and under artificial respiration the wound was reopened and the medulla fully exposed. It was feared that there had been some bleeding but nothing was found to account for the respiratory failure: spontaneous breathing was not resumed.

**Autopsy.**—The brain was removed in its envelopes after fixation *in situ*. No evidence of post-operative bleeding: no apparent contusion of brain stem. The upper pole, possibly one-third of the tumor, remains in position. The growth is very irregularly nodular and in addition to the general dislocation of the pons to the left from the pressure of the growth, one of the nodules projects far into the side of the pons, making a deep indentation.

Sections of the tumor were originally diagnosed as a cerebellopontile "endothelioma," but on recent re-examination it proves to be a typical acoustic tumor which shows the usual fibrous bands (Figs. 39 and 40) and well demarcated areas of loose reticular tissue resembling glioma (Fig. 41). The striking thing about this particular growth is the wide-spread hydropic degeneration with tendency to cyst formation. There are many vessels and in some areas extensive hyaline degeneration.

**Comment.**—No apprehension concerning the patient's condition was felt at the close of the operation, which had been a relatively simple and uncomplicated one. He was practically out of his anæsthetic by the time the wound was closed and no respiratory embarrassment had been observed. The prompt respiratory failure which occurred the moment he was turned from the face-down position and placed on his back has since then led us to be very cautious about placing patients, after a cerebellar operation, in the dorsal position until they are quite conscious and we are assured that their respiration is free and unaffected. To this we shall return in the discussion of the operation.

One more fatality was apparently needed to drive the lesson home that at least until our skill is greater or these tumors are operated upon at an earlier period before the brain stem is so greatly deformed, a total extirpation of the growth within its capsule is too hazardous to be justified. The following is the third of the series of consecutive fatalities attributable to overradical procedures.

## Case X

J.H.H. Surg. No. 27679. **Left acoustic tumor with undeveloped cerebellopontile syndrome. Previous subtemporal decompression with two years' relief. Usual suboccipital operation. Attempted tumor extirpation. Death from pneumonia. Autopsy.**

*April 23, 1911.* Admission of Joseph H., age 28, a merchant, referred by Dr. John L. Yates of Milwaukee, with the diagnosis of a cerebellopontile tumor.

A definite occipital trauma received twenty years before, the head striking against the corner of a table: followed by vomiting, but no serious sequels.

**Chronology of symptoms.**—Four years ago, in 1907, periods of intermittent pain in left ear: never any tinnitus. The paroxysmal pains increased and radiated to the frontal region and eye. Three years ago sudden total deafness in left ear. During 1908 severe headaches accompanied by choked discs, so that on *Sept. 9, 1908*, a right subtemporal decompression was performed by Dr. Yates, with subsequent marked improvement for over two years.

Recently discomforts have returned: chiefly pain in left ear and eyeball with occa-

sional attacks of dizziness and vomiting. Occasional numbness and twitching of left arm and leg.

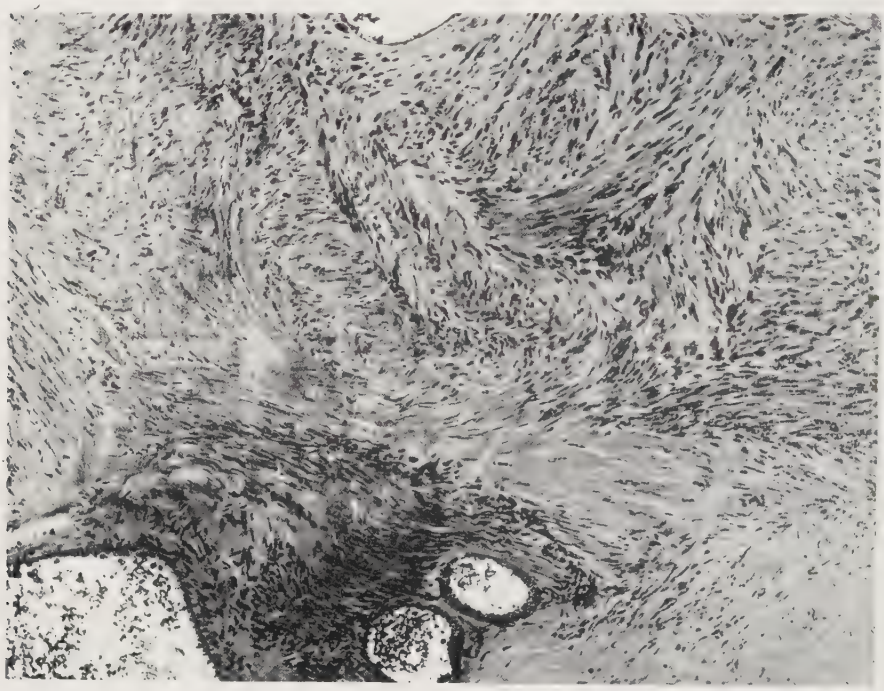

FIG. 42.—Case X. Interlacing bands in fibrous areas with zones of degeneration (phosphotungstic acid hæmatin (× 80).



Fig. 43

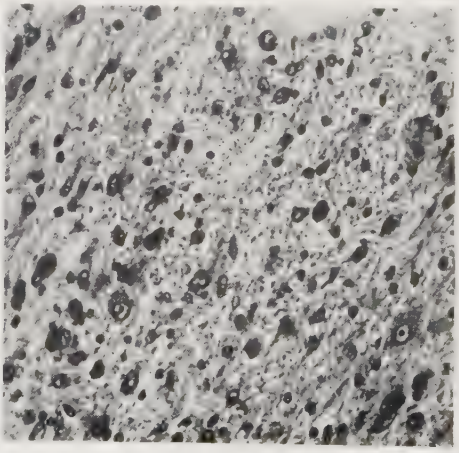

Fig. 44

FIGS. 43, 44.—Case X. Showing (× 300) fibrous and reticular areas.

**Positive neurological findings.**—(A) *General pressure.* Protrusion of subtemporal decompression, size of half an orange. Choked disc of 5 D. left: 4 D. right. No X-ray studies.

(B) *Localizing.* (1) *Cerebellar.* Nystagmus more marked and coarser to left. Gait and station unimpaired. No ataxia.

(2) *Extracerebellar. Cerebral nerves.* $V^{th}$ = Negative. Corneal reflexes equally active. $VI^{th}$ = Negative. $VII^{th}$ = Negative.

$VIII^{th}$ = Left ear deaf: Bárány tests show total loss of left labyrinthine reactions.

$IX^{th}$, $X^{th}$, $XI^{th}$ and $XII^{th}$ = Regarded as negative.

*April 27, 1911.* **Operation.**—Usual bilateral exposure. Marked pressure cone, though fluid was finally secured after an unsuccessful attempt to puncture the lateral ventricle. Final good extracerebellar exposure of high recess tumor: thorough and supposedly total extirpation in fragments. No operative complications. Closure in usual layers without drainage.

**Post-operative notes.**—Deglutitory difficulties; hiccoughing and vomiting; excessive mucoid expectoration; all pronounced. On *May 1* a friction rub developed followed by lobar pneumonia and death on the sixth day.

**Autopsy.**—In the upper angle of the recess a small fragment of the tumor remains; considerable contusion of the side of the pons. Internal hydrocephalus.

*Histology* of tumor. Operative fragments sent to Dr. Mallory, who reported "a fairly rapidly growing fibroma or, perhaps better, fibrosarcoma. The cells show fibroglia and collagen fibrils. They do not correspond in any way with similar tumors in other parts of the body, but this may be due to the type of fibroblasts from which they come. I think I have called similar tumors in the past endotheliomata."

A recent re-examination of the tissues shows that different areas of the tumor differ greatly in appearance. Predominant are the typical fibrous bands (Figs. 42 and 43) with indications of whorls and palisade disposition of nuclei. Many areas show extensive degeneration: the zone of hyaline change about the vessels is marked (Fig. 206) and there is considerable pigmentation. One small area shows the characteristic loose reticular tissue resembling glioma (Fig. 44), but no fibrils positively demonstrated. The appearances fully justify Dr. Mallory's diagnosis, but the growth is unquestionably an acoustic tumor.

**Comment.**—The case is notable chiefly for the reason that the tumor was a comparatively small one with an undeveloped cerebellopontile-angle syndrome. The extracerebellar symptoms were confined to the acoustic nerve, in which the loss of function had been abrupt and without antecedent tinnitus. The cerebellar symptoms likewise were very inconspicuous and were limited to a variable nystagmus. There, however, was sufficient pontile deformation to have produced an internal hydrocephalus with choked disc which the subtemporal decompression had served to temporarily forestall.

No case in the entire series could have been more favorable for a total operative removal, if such a procedure without some more perfected operative methods is ever justifiable. The attempt led to such a degree of contusion, doubtless with resultant œdema of the side of the pons, as to precipitate what are the usual terminal symptoms—namely, aggravated dysarthria, dysphagia and an inhalation pneumonia.

A simple suboccipital decompression even without touching the tumor would probably have given this poor fellow several years of comfortable life, and a successful intracapsular enucleation many more.

In the following case, consequently, though it was one far more advanced than the foregoing, the procedure was limited to an extensive intracapsular

extirpation. However, this was done through a transcerebellar approach whereby considerable pontile contusion with marked aggravation of symptoms was produced.

## Case XI

J.H.H. Surg. No. 27700. **Left acoustic tumor with advanced cerebellopontile-angle symptoms. Two operations. Extensive intracapsular extirpation. Recovery.**

*April 25, 1911.* Admission of Mary C. B., age 23, referred by Dr. R. M. Wiley of Salem, Va., owing to intracranial trouble. Thirteen different diagnoses had been made of her malady.

**Chronology of symptoms.**—Four years ago, following a severe attack of whooping cough, she became hoarse owing to a left vocal cord paralysis, and this has persisted. Since this time she has suffered from "sick headaches," usually suboccipital, followed by nausea and vomiting.

Two years ago oncoming deafness was first noted in left ear: increasing: occasionally accompanied by tinnitus. Photophobia with blurring of vision, and latterly periods of amaurosis.

For one year unsteadiness with dizziness. Also incoördination of extremities, particularly of left arm.

For three or four months dysarthria. For two months loss of smell and taste; occasionally periods of diplopia.

**Positive neurological findings.**—(A) *General pressure.* Bilateral choked disc with beginning secondary atrophy. Complete anosmia. No X-ray plates.

(B) *Localizing.* Suboccipital pain and tenderness, particularly left. Tilting of head to left. (1) *Cerebellar.* Nystagmus, vertical and lateral: coarser to the left. Marked incoördination, particularly of left arm and hand, with dysmetria and adiadococinesia. Positive Romberg. Staggering gait. Deep reflexes increased: suggestive clonus.

(2) *Extracerebellar. Cerebral nerves.* $V^{th}$ = Loss of corneal and palatal reflexes. $VI^{th}$ = Slight internal squint on left: periodic diplopia. $VII^{th}$ = Nasolabial fold less deep on left: left palpebral cleft wider than right. Gustatory sense impaired on left.

$VIII^{th}$ = Left deafness with former tinnitus; no labyrinthine tests.

$X^{th}$ = Complete paralysis of left vocal cord. $IX^{th}$, $XI^{th}$ and $XII^{th}$ = Negative, except for some dysarthria and dysphagia.

**Clinical diagnosis.**—"Left cerebellopontile tumor."

*May 1, 1911.* **Operation I.**—Usual bilateral procedure. Suboccipital bone greatly thinned. Marked pressure cone. Dry posterior cistern. Considerable protrusion of hemispheres. Tumor, as finally exposed, thought to be too deep in recess to justify extracerebellar manipulations. Transection of left hemisphere, with exposure of tumor and a fragmentary extirpation. Closure as usual, without a drain.

**Post-operative notes.**—Considerable increase in all cerebellar symptoms, in addition to marked deglutitory difficulties and thickness of speech. Healing without reaction. As her symptoms showed no sign of improvement at the end of a month's interval, a more thorough enucleation as a desperate resort was determined upon.

*June 2, 1911.* **Operation II.**—The wound was reopened and the tumor re-exposed, a large part of the overlying cerebellar hemisphere being sacrificed in the process. The tumor capsule was incised transversely and as much of the growth as possible was scooped out in fragments with a blunt spoon curette. An attempt was made to preserve the capsule, but it was largely detached in the process of the enucleation, and a portion of it, measuring when spread out about 5 cm. in diameter, was withdrawn, with but little bleeding.

During the course of the operation there were frequent respiratory and cardiac upsets, the pulse occasionally dropping to 40 per minute. Pressure against one particular point (vagus?) of the lower pole of the tumor appeared to elicit these symptoms.

**Post-operative notes.**—Increased difficulty in swallowing, so that for several days

nasal feeding was instituted to forestall a possible inhalation pneumonia. There were palsy of the left face and complete left trigeminal anæsthesia. Also marked increase

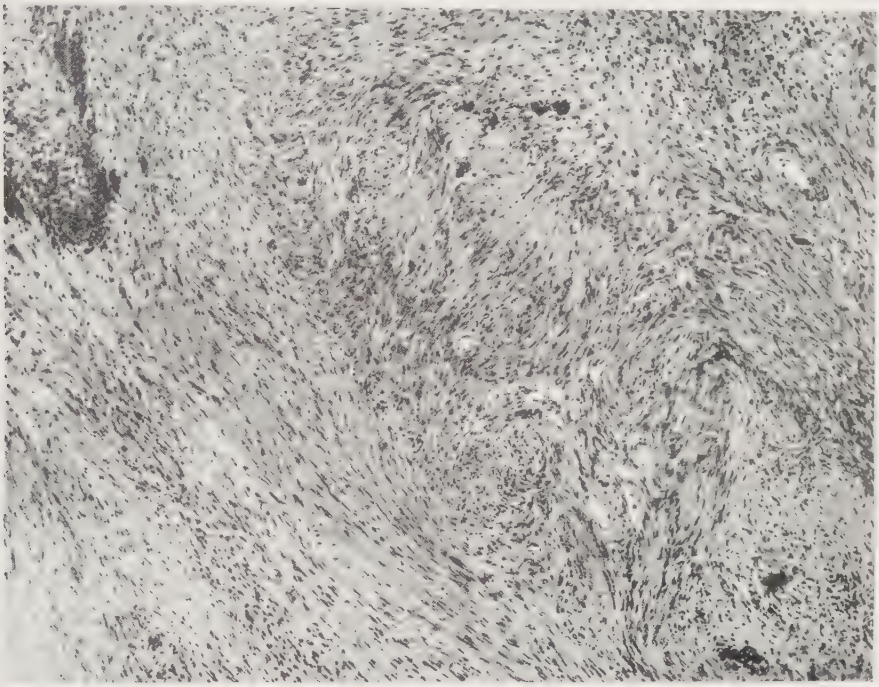

Fig. 45.—Case XI. Area of tumor showing (× 80) the characteristic architecture of the fibrous areas (hæmatoxylin eosin).

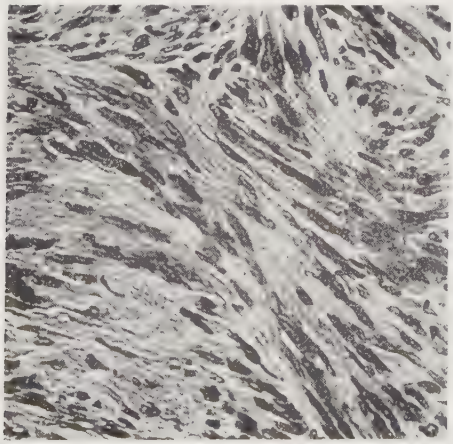

Fig. 46

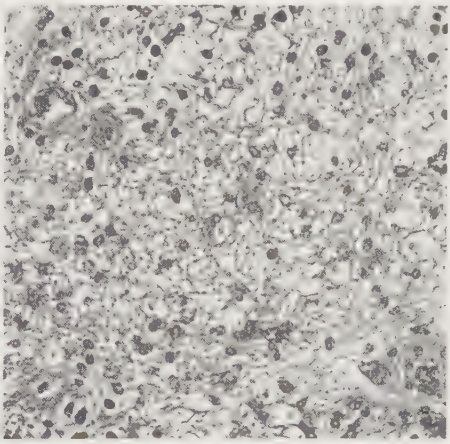

Fig. 47

Figs. 46, 47.—Case XI. Characteristic architecture of fibrous and reticular areas (× 300).

in ataxia in left extremities. Gradual subsidence of these symptoms during the following six weeks.

General condition greatly improved by *July 18:* return of movement and sensation in left face. Restoration of sense of smell. Vision of right eye reduced to counting fingers. Persistence of left deafness. She was discharged *Aug. 11, 1911.*

**Subsequent notes.**—Last report *Jan. 22, 1917*, after five years. Has been remarkably well, though she remains practically blind and is deaf in the left ear. Has learned the Braille method of reading and writing. Numbness of left trigeminal area persists, with loss of taste on the left. Able to walk only with support. Has gained forty pounds in weight. Is free from all pressure discomforts.

**Pathological note.**—A diagnosis of fibrosarcoma was made from the tissues at the time by Dr. Mallory. A present re-examination of the tumor, which bears a close histological resemblance to the preceding, shows the tissue to be essentially composed of interlacing fibrous bands (Figs. 45 and 46), with a tendency of the nuclei to dispose themselves in whorls and parallel arrangements. There is a considerable tendency to hydropic changes. The few blood vessels show characteristic hyaline walls. There are some areas of typical glia-like tissue without demonstrable fibrils (Fig. 47).

**Comment.**—The operative procedures in this case were evidently too radical, and a transcerebellar, in contradistinction to an extracerebellar, approach should always be avoided if possible. Nevertheless the outcome, so far as tumor extirpation and prolongation of life are concerned, served to show what might prove to be the best way of attacking these lesions if, in the future, an extirpation was to be contemplated—namely, to remove its contents and then to peel the capsule away from its enveloping structures. However, the V$^{th}$ and VII$^{th}$ nerves were permanently injured in the process, and in view of their intimate relation to the tumor capsule it is hard to see how this can be avoided in the removal of a growth of any magnitude.

This unfortunate girl, fortunately possessed of a buoyant disposition despite her affliction, is cut off from most of the enjoyment she might have had even in her crippled state were her vision preserved, as it might have been had the operation been performed earlier.

One unusual feature of the clinical picture lies in the vocal cord paralysis. Whether this was coincidental or actually due to the pressure of the tumor against the vagus is not clear, though one would have expected an accompanying accessorius palsy if it had been produced by the growth.

---

This is the last of the Baltimore series of cases, the operative results of which had been far from encouraging, with four deaths out of eleven attempted tumor removals—a 36.3 per cent mortality—and this exclusive of Case VII, in which death followed an operation based on an erroneous localization. Much had been learned, however, by the varied experiences, and some optimism was retained owing to the three following reasons: (1) that the results of operations for cases in the series with intracerebellar tumors were far better; (2) that there were fifteen patients under the suspicion of carrying a recess tumor who had been greatly benefited by a suboccipital decompression, though the nature of the growth remained unverified; and (3) that the mortality, high as it was, contrasted favorably with the 70 per cent mortality recorded from other clinics.

In the following cases, constituting the Boston series, the clinical

studies have been more exact, particularly in regard to the Bárány tests and X-ray studies. The surgical results also have been more promising, with only two deaths out of nineteen partial tumor removals—a 10.5 per cent mortality. The operative end results, moreover, have been increasingly better, though in the first case of the new series, like the last one (Case XI) of the old, pontile contusions resulting in an increase in local symptoms with dysphagia of a degree necessitating temporary nasal feeding, were produced by a too radical and a repeated effort to completely remove the lesion.

## Case XII

P.B.B.H. Surg. No. 295. **Right acoustic tumor giving an advanced cerebellopontile-angle syndrome. Partial intracapsular enucleation in two sessions. Recovery.**

*Aug. 4, 1913.* Admission of Miss Caroline B., 50 years of age, referred by Dr. David Percy of Arlington Heights, Mass.

**Chronology of symptoms.**—For twenty-one months increasing deafness of right ear: no tinnitus. For fourteen months unsteadiness of gait, first observed by others. For eight months occasional headaches and vertigo: also incoördination of right hand, with dropping of objects. For four months occasional periods of diplopia; blurred vision; numbness of right face.

**Positive neurological findings.**—(A) *General pressure.* Choked disc of 7 D. with hemorrhages and much new tissue. X-ray shows evidences of increased tension and secondary absorption of dorsum sellæ.

(B) *Localizing.* (1) *Cerebellar.* Nystagmus variable: at times oscillatory movements: coarser to the right: rotary on looking up. Positive Romberg with falling to right and back. Gait very ataxic. Marked incoördination of right hand, with adiadococinesia, dysmetria, etc. Deep reflexes exaggerated, slightly greater on right.

(2) *Extracerebellar. Cerebral nerves.* $V^{th}$ = Considerable right hypæsthesia with corneal areflexa: also motor involvement, with deviation of jaw to right. $VI^{th}$ = Negative: history of diplopia. $VII^{th}$ = Slight asymmetry with flattening of nasolabial fold on right. Definite right ageusia.

$VIII^{th}$ = Complete right deafness, corroborated by caloric tests. No responses from right labyrinth. X-ray of porus inconclusive.

$IX^{th}$, $X^{th}$, $XI^{th}$ and $XII^{th}$ = Considerable dysarthria and dysphagia.

*Sept. 3, 1913. Readmission.* Increasing impairment of vision: choked disc subsiding with secondary atrophy. Condition otherwise much as on previous examination a month before.

*Sept. 6, 1913.* **Operation I.**—It was impossible to dislocate the cerebellum sufficiently to expose the recess, so that a transverse incision in the hemisphere was made and carried down to the tumor, whose posterior pole was fully exposed. Intracapsular extirpation of possibly the lower half of the growth. Closure as usual in layers without drainage.

**Post-operative note.**—Considerable post-operative deglutitory difficulty with increase of dysarthria. Temporary recourse to nasal feeding owing to fear of inhalation pneumonia. Healing *per primam.* Subsequent improvement in general condition. Neighborhood symptoms practically unchanged.

It was unwisely decided to undertake a second and more radical procedure in the hope of completing the extirpation.

*Oct. 17, 1913.* **Operation II.**—The wound was reopened, the tumor was again exposed, and about as much of the intracapsular contents as on the former occasion was removed from what seemed to be the posterior and inner portion of the growth. The tissue was cheesy and was easily peeled away from the capsule. Considerable twitching of the accessorius musculature produced during the manipulations. The impression was gained that the por-

tion of the tumor which had not been successfully removed was its caudad portion, which probably had been pressing against the medulla, producing the dysphagia and dysarthria.

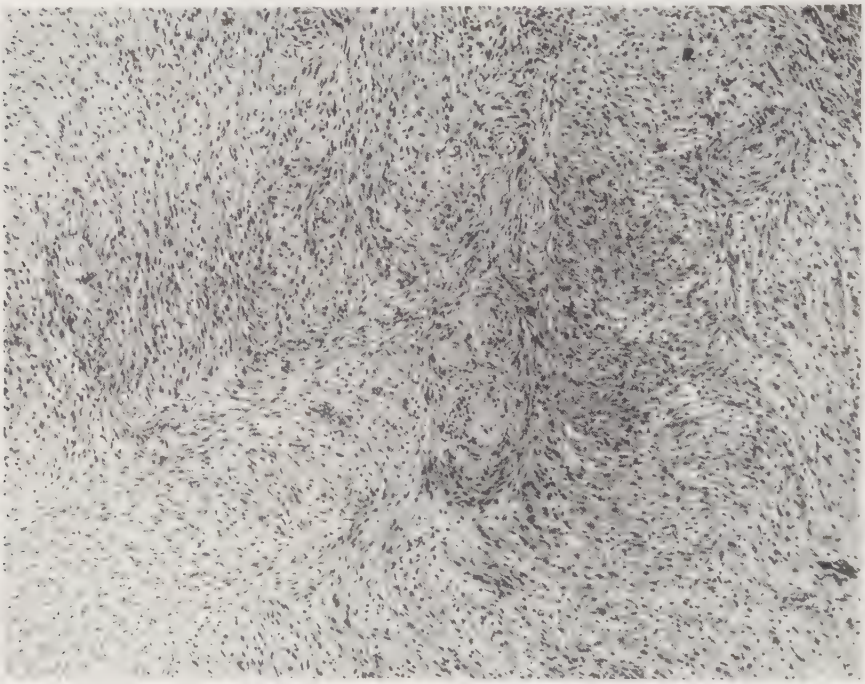

Fig. 48.—Case XII. Low power (× 80) of characteristic fibrous area (hæmatoxylin eosin).



Fig. 49

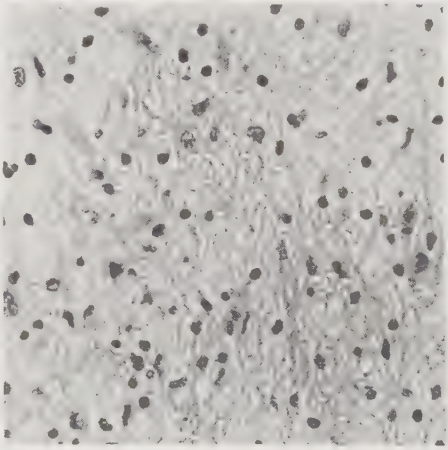

Fig. 50

Figs. 49, 50.—Case XII. Hydropic fibrous area: reticular area (× 300).

**Post-operative notes.**—Marked improvement after this operation. Healing was perfect, but there was considerable tension, necessitating the withdrawal of fluid by tapping on

two occasions. Local symptoms remained as before. Subsidence of choked disc, with pallor and lowering of vision to light perception only. Discharged on *Dec. 3, 1913.*

**Subsequent notes.**—There was considerable improvement after her discharge, but she remains helpless owing to near blindness and incoördination of movements on right. She has been free from all pressure symptoms: deafness persists. Last report *January, 1917.*

**Pathological note.**—The fragments of tumor when assembled in a compact mass measured about 3 cm. in diameter. A histological diagnosis of "fibroma" was returned at the time.

A subsequent re-examination of the tissue shows the growth to be a very hydropic tumor. It is composed of the usual fibrous bands with a tendency of the nuclei to form whorl arrangements (Fig. 48). The bands are very œdematous in places (Fig. 49) and fat globules appear between the collagen fibres. Between the fibrous zones are the characteristic areas of loose reticular tissue in which pseudo-glia fibres are found (Fig. 50). No hyaline degeneration observed: no cyst formation.

**Comment.**—The end result in this case from a surgical point of view leaves much to be desired, although the patient's life has doubtless been prolonged. It is a pity that the operation was postponed until it was inevitable that blindness would ensue.

Had a ventricular puncture been performed, a sufficient dislocation of the hemisphere to the left might have been permitted to give an extracerebellar exposure of the growth, and a transection of the cerebellum thus been avoided. This latter procedure, just as in Case XI, doubtless added to the post-operative complications, for had the lesion been properly exposed and attacked primarily from below, the bulbar symptoms might have been forestalled and the second operation rendered unnecessary.

---

The surgical experiences in the foregoing six cases were most discouraging, but the lessons were taken to heart and in the following two cases the less radical procedure carried out in Cases V and VI was again resorted to, with more promising results.

## Case XIII

P.B.B.H. Surg. No. 697. **Right acoustic tumor with characteristic cerebellopontile-angle syndrome. Auditory symptoms for seven years. Intracapsular enucleation. Recovery.**

*Dec. 17, 1913.* Admission of Miss Myrtle S., age 29, a school teacher, referred by Dr. Charles Ball of St. Paul.

**Chronology of symptoms.**—For seven years a noticeable and increasing impairment of hearing on the right, without initial tinnitus. Complete right deafness for past six months.

For five years increasing incoördination and weakness of right hand, first noticed when writing on blackboard.

For two years a staggering gait with especial awkwardness of right foot.

For one year tinnitus in left ear: also diplopia when looking to right.

For six months occipital pains, with cervical soreness,stiffness and tenderness. Also nausea and occasional vomiting: blurring of vision: dizziness.

**Positive neurological findings.**—(A) *General pressure.* Choked disc of 3 D. X-ray shows some secondary absorption of dorsum sellæ (Fig. 51). No enlargement of venous channels.

(B) *Localizing.* (1) *Cerebellar.* Marked constant oscillatory nystagmus. Romberg positive with falling to right and back. Gait unsteady, with deviation usually to right. Motor incoördination on right to usual tests: diadococinesia, dysmetria, etc. Deep reflexes active, slightly more so on right.

(2) *Extracerebellar. Cerebral nerves.* $V^{th}$ = Hypæsthesia throughout right trigeminal area: also motor weakness with deflection of jaw to right. $VI^{th}$ = Weakness on right, with diplopia. $VII^{th}$ = Slight weakness of lower right face apparent on emotional movements: loss of sense of taste on right.

$VIII^{th}$ = Paralysis of cochlear and vestibular nerves complete on right: confirmed by caloric tests: present tinnitus referred to left: X-ray studies of porus inconclusive.

$IX^{th}$, $X^{th}$ = Some dysarthria and dysphagia. $XI^{th}$ = Slight weakness of right accessorius group. $XII^{th}$ = Tongue protrudes to right (*cf.* position of jaw).



Fig. 51.—Case XIII. Showing secondary pressure thinning of dorsum sellæ.

**Clinical diagnosis.**—"Right cerebellopontile endothelioma."

*Dec. 23, 1913.* **Operation.**—Usual suboccipital exposure. Cerebellum dry. Marked pressure cone. Exploration of right recess disclosed an arachnoid cyst, on opening which about 15 cc. of fluid escaped. Further investigation revealed a subjacent tumor in angle. It was fully exposed, its capsule incised with a blunt dissector, and the growth bisected. The intracapsular portion of the growth was removed as completely as possible from each half of the bisected growth. Sharp bleeding was occasioned at one point, requiring implantation of a small piece of muscle. Closure. A four-hour operation.

**Post-operative note.**—Some temporary increase in cerebellar symptoms. Uneventful recovery: usual reactionless healing (Fig. 52). Cessation of discomforts. Subsidence of choked disc. Extracerebellar symptoms unmodified. Discharged *Feb. 2, 1914.*

**Subsequent notes** (by letter).—*May 7, 1914.* Great improvement in all respects. *Oct. 28, 1915.* Able to walk four miles without fatigue. *Aug. 25, 1916.* Condition

remains excellent. Vision is unimpaired. Right deafness persists. The former ringing tinnitus on the left has subsided: now replaced by a sound like that of a sea-shell. No numbness of the face. Slight unsteadiness occasionally experienced on turning quickly. No pressure symptoms. Able to do her own housework: served as saleswoman in a bookstore the past winter.

*Feb. 27, 1917* (by letter). Continues well. Teaching kindergarten and acting as children's governess.

**Histological note.**—Fibrous elements in cellular rows and whorls, mixed with a looser tissue resembling glioma containing fairly definite neuroglia fibrils. The pathologist at the time considered the tumor from its histological appearance to be a "slow-growing glioma."

A present re-examination of the tissue reveals the characteristic structure of an acoustic tumor. The usual bands of fibrous tissue appear in which the nuclei tend to be arranged in rows or whorls (Figs. 53 and 54). Between these bands are quite sharply demarcated areas of a loose reticular tissue suggesting glioma (Fig. 55). There are masses of collagen fibres with fairly perfect neuroglia fibrils among them (Fig. 201) though for the most part these fibrils are short, broken, and imperfectly differentiated. There are many vacuolated cells. The walls of the blood vessels are extensively hyalinized (Fig. 207).

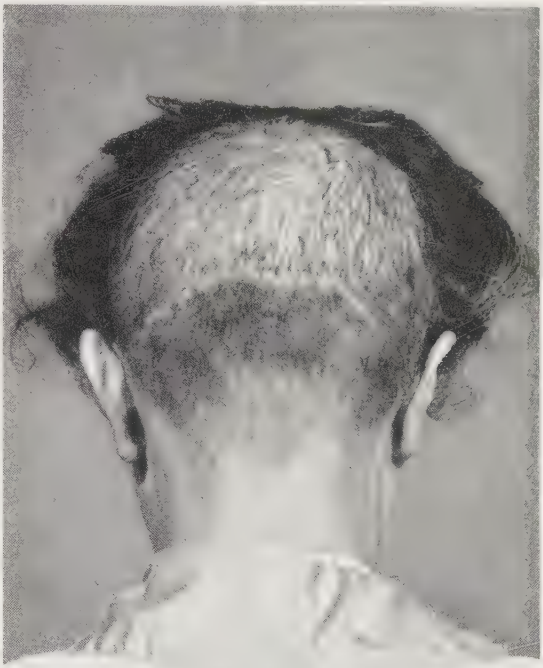

Fig. 52.—Case XIII. Condition of wound on 18th day.

**Comment.**—This was a straightforward and uncomplicated surgical experience with the best result up to this time with the possible exception of Case V. The tumor in both instances had been attacked intracapsularly, and, as the end of the three-year period is at hand in this patient, we may look for a return of symptoms ere long which may necessitate a repetition of the procedure.

This was the first of the cases in which the diagnosis of glioma began to be returned owing doubtless to the more careful studies to which the tissues were subjected and to the fact that glia-like fibrils were observed. From a clinical standpoint we realized, of course, that the appearance and manner of growth of the lesion belied the histological diagnosis, at least on the basis of the behavior of the usual infiltrating tumor of a gliomatous character.

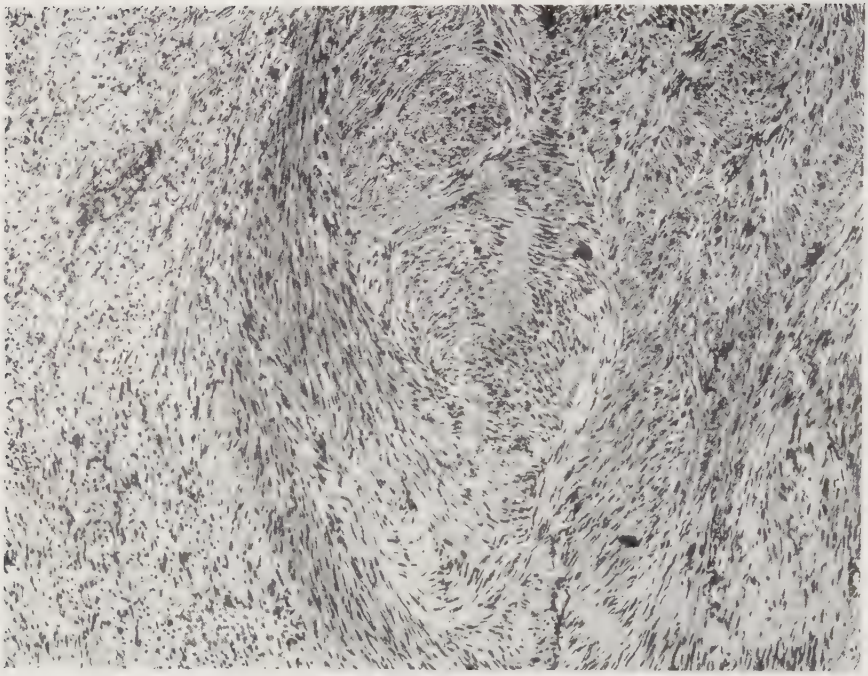

FIG. 53.—Case XIII. Showing (× 80) the masses of interlacing fibrous bands and, to the left, an area of the loose reticular tissue with scant round cells (phosphotungstic acid hæmatin).

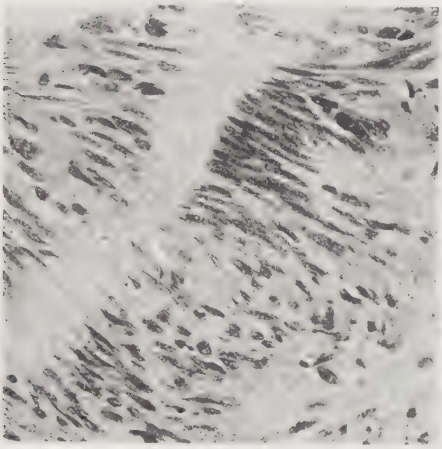

Fig. 54



Fig. 55

FIGS. 54, 55.—Case XIII. Palisade arrangement of nuclei: reticular area (× 300).

The record of the next patient shows how readily one may be misled in regard to the chronology of the symptoms of these lesions, for according to her original story the suboccipital discomforts were the antecedent symptoms, and not until long after her operation did she recall the fact that there had been "peculiar noises in her ear" and "occasional dizzy spells" for several months preceding.

## Case XIV

P.B.B.H. Surg. No. 2047. **Right acoustic tumor with an advanced recess syndrome. Operation. Partial intracapsular enucleation. Recovery.**

*Nov. 6, 1914.* · Admission of Rose C. N., age 42, a mill hand, referred by Dr. LaSalle Archambault of Albany, with the diagnosis of a cerebellopontile tumor. She has been addicted more or less to headaches all of her life.

Fig. 56.—Case XIV. Post-operative plate of left pyramidal bone with poorly shown pori. Note characteristic pressure absorption of dorsum sellæ.

**Chronology of symptoms.**—About two years ago onset, with tinnitus in right ear and occasional sudden dizzy attacks, during which she would "walk slantwise." The tinnitus was a "ringing" sound for about six months: later a "buzzing" and again "like a steam engine," so loud that it seemed others must hear it. After some months there was gradual loss of hearing and she was treated by an aurist for long without avail.

Eighteen months ago there appeared occipital discomforts unlike her former headaches, associated with stiff neck and tenderness, which soon forced her to stop work. At the same time there were considerable nausea and paroxysmal vomiting.

For sixteen months there have been dizziness and a staggering gait, and for four months she has been unable to walk without support.

For twelve months periods of amaurosis and for four months rapid failure of vision. Reading vision lost for three months.

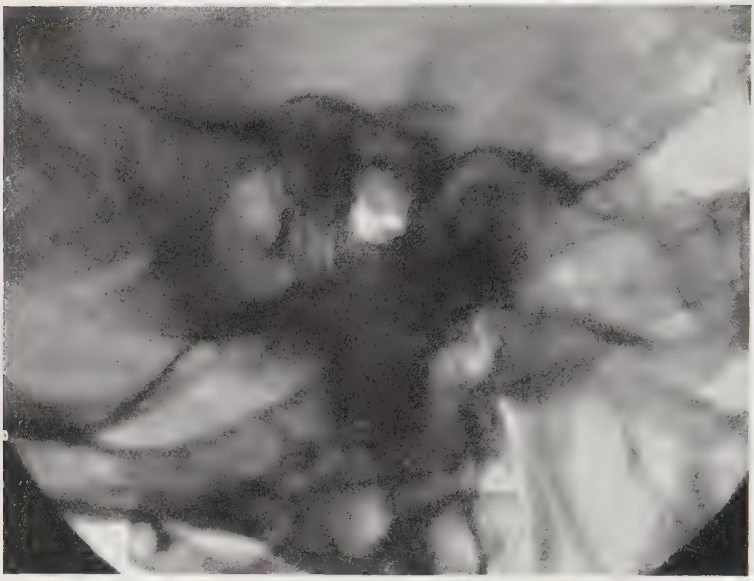

Fig. 57.—Case XIV. Poorly disposed plate of superimposed right pori, showing what was regarded as extensive bone absorption around the porus internus.

Fig. 58.—Case XIV. Patient after operation, showing the divergent squint.

**Positive neurological findings.**—(A) *General pressure.* Advanced choked disc with near blindness on left: vision 20/200. Pupillary reactions sluggish. X-ray shows (Fig. 56) marked secondary erosion of sella and posterior clinoids and greatly distended venous channels of skull.

(B) *Localizing.* Suboccipital tenderness, more on left. (1) *Cerebellar.* Nystagmus: coarser to right. Some incoördination on right, with slight dysmetria, diadococinesia, and ataxia (varies with different examinations). Romberg positive with eyes open: falls to right. Gait ataxic: deviates to right and falls.

Exaggerated deep reflexes with suggestive clonus on right.

(2) *Extracerebellar. Cerebral nerves.* $V^{th}$ = Bilateral hyporeflexa cornealis: equa right and left. $VI^{th}$ = Weakness on right. $VII^{th}$ = Negative.

$VIII^{th}$ = Complete deafness right, confirmed on irrigating left ear. No labyrinthine reaction movements on right. X-rays of porus acusticus inconclusive but suggest (Fig. 57) an enlargement on the right.

$IX^{th}$ = Considerable deglutitory difficulty. $X^{th}$, $XI^{th}$, $XII^{th}$ = Negative.

(C) *Misleading.* A divergent squint (Fig. 58) with weakness of right abducens and left oculomotorius, producing a marked restriction of movements to right.

**Clinical diagnosis.**—"Right cerebellopontile tumor: endothelioma (?)."

*Nov. 10, 1914.* **Operation.**—Usual exposure. Marked tension relieved by early puncture of lateral ventricle. Partial intracapsular removal of a right recess tumor which was exposed with somewhat more difficulty than usual, high in the angle. During the partial extirpation the shoulder twitched several times, showing the proximity of the manipulations to the IX$^{th}$, X$^{th}$ and XI$^{th}$ nerves. Closure as usual in layers.

**Post-operative notes.**—Marked temporary hoarseness, probably from a vocal cord palsy. This disappeared after a week. No other complications. Usual perfect wound healing (Fig. 59). Discharged *Dec. 14, 1914,* greatly improved in all respects except for her vision, which became still further reduced (V. O. D. 30/200: V. O. S. 6/200), during the subsidence of the choked disc.

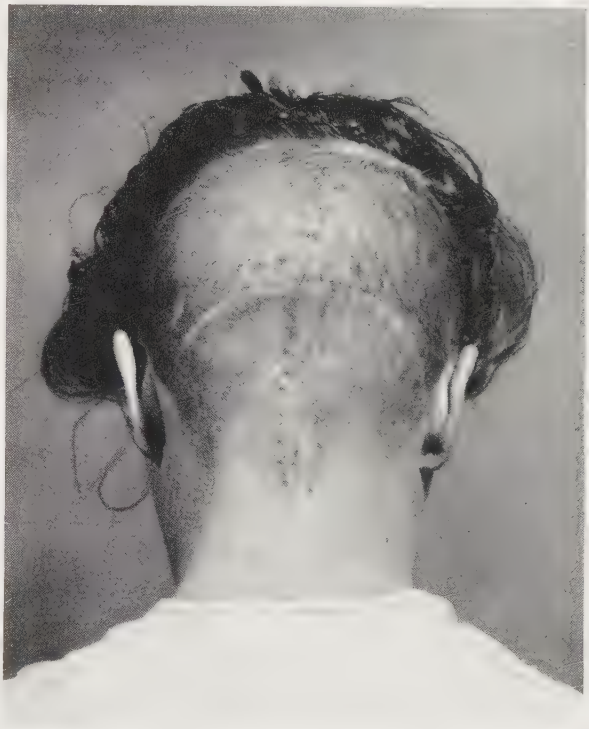

Fig. 59.—Case XIV. Showing wound after two weeks.

**Subsequent notes.**—*July 29, 1915.* Readmission for examination (after six months). Healthy and robust: gain of 30 pounds' weight. Vision poor (V. O. D. 20/200: V. O. S. nil): discs white and flat. Some buzzing tinnitus persists in the right ear, which is apparently deaf. Some unsteadiness, though walks well. No ataxia upper extremities. Nystagmus as before.

*Sept. 1, 1916.* Readmission for examination (after two years). Condition remains excellent and further improvement apparent. Aside from a positive Romberg, cerebellar symptoms are practically wanting: no nystagmus. All cerebral nerves intact except the II$^{nd}$ and VIII$^{th}$. The vision is very low and the acusticus remains paralyzed to sound perception and caloric tests. Further X-rays of the porus, taken in several positions, at this time were inconclusive.

*Feb. 22, 1917.* Reports by letter: no change: condition remains good: leading an active life despite low vision.

**Pathological note** (November, 1914).—Sections of the tumor (Figs. 60–63) disclosed bundles of fibrous tissue with numerous vessels showing mural hyaline degeneration. One area was very suggestive of reticular glia tissue with cyst-like spaces and some definite fibrils. A diagnosis of "glioma" was made, but was subsequently changed to "endothelioma." Dr. Councilman's note added at the time to the pathological report is of considerable moment:

"The main interest in the tumor attaches to the presence of the glia-like tissue within

it. In this there are very few fibrils which correspond to glia fibrils, but they seem to be undoubted. Moreover the tumor in other respects is different from the ordinary meningeal

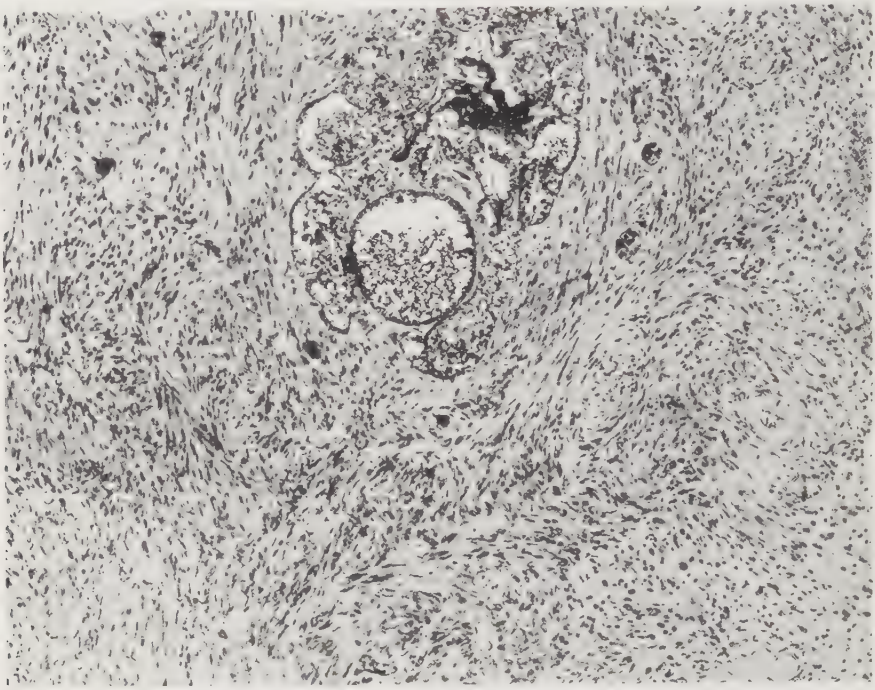

Fig. 60.—Case XIV. Showing (× 80) characteristic fibrous area (phosphotungstic acid hæmatin).

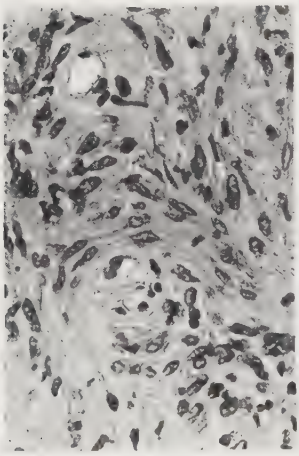

Fig. 61

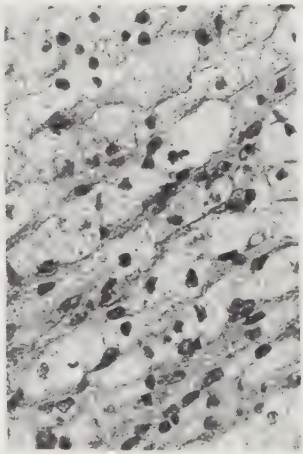

Fig. 62



Fig. 63

Figs. 61, 62, 63.—Case XIV. Showing (× 300) whorl arrangement of nuclei in fibrous area: fatty infiltration of fibrous bands: reticular area.

endothelioma. All of the operative fragments have been cut, and although in areas it is typical endothelioma, even showing the whorls of cells, in other places this is lost. There

are also numbers of large cells filled with fat, suggestive of the compound granule cells in cerebral softening. It would seem possible that this tumor, although essentially a glioma, and originating in the meninges, may in places have impinged upon the brain and possibly penetrated it, and that the glia tissue represented in the tumor is really due to this. Against this is the fact that these endotheliomata have not shown any tendency to invade, nor has there been in association with them any glia reaction."

A recent re-examination of these and other sections shows them to be typical of the other acoustic tumors in the series (Fig. 60). With ordinary stains there is a resemblance to certain of the endotheliomata, but with Mallory's connective-tissue stain the fibrous bands and the intervening reticular areas become sharply demarcated. In the fibrous areas the cells and their nuclei are less elongated than usual, owing possibly to the œdema of the tissue. There is some tendency of the cells to whorl formation.

With Mallory's connective-tissue stain the fibrous bands have a purplish tone and the collagen fibres are well marked. The walls of the blood vessels are extensively hyalinized and take a brilliant blue color. There is considerable hydropic degeneration with the formation of cysts.



Fig. 64. Case XV. Before operation, showing skew deviation of eyes and position of head characteristic of a left recess tumor.

**Comment.**—Here again was a typical story of an acoustic neuroma which was clinically fairly well understood but concerning which there was still confusion on a histological basis, owing to the presence of pseudo glia fibrils. The surgical procedure was an uncomplicated one, and after four fairly successful cases we had begun again to feel some assurance in regard to these recess operations, but this was effectively dampened by the experience with the next patient, in whom a large tumor eluded exposure even in two explorations.

## Case XV

P.B.B.H. Surg. No. 2112. **Pronounced left cerebellopontile-angle syndrome of recent onset. Exploration and decompression: tumor not disclosed. Second exploration three months later. Fatality. Autopsy. Large left acoustic tumor.**

*Nov. 21, 1914.* Admission of Louis J. G., 22 years of age, a clerk, referred by Dr. James J. Putnam of Boston, with the diagnosis of a presumptive cerebellar tumor. Notable in his past history is a right otitis media twelve years ago, with subsequent impairment of hearing.

**Chronology of symptoms.**—For two years increasing deafness, though onset, according to patient's interpretation, began sixteen months ago with staggering gait.

One year ago a period of vomiting, headache and fever, diagnosed "stomach trouble": headache and daily vomiting have persisted. Suboccipito-frontal discomforts on left. Failing vision of late with periods of amaurosis. Vomiting frequent and distressing. Slight dizziness: no rotation of objects.

**Positive neurological findings.**—(A) *General pressure.* Advanced choked disc of 3 D., receding with atrophy: vision O. S. 20/200, O. D. 20/70. Periods of amaurosis, The X-ray shows advanced secondary pressure changes in the sella and greatly enlarged venous channels.

(B) *Localizing.* Slight left suboccipital tenderness. Head tilted to right shoulder (Fig. 64), thus relaxing left suboccipital region.

(1) *Cerebellar.* Nystagmus, horizontal and rotary: jerks coarser to right. Romberg slight. Gait somewhat unsteady: wide base: turning awkward: progress on all fours without difficulty. Considerable ataxia left arm and leg, with diadococinesia and dysmetria.

Fig. .—Case XV. Condition one month after the first operation.

Deep reflexes all hyperactive and equal.

(2) *Extracerebellar. Cerebral nerves.* III$^{rd}$ = Definite skew deviation (Fig. 64). V$^{th}$ = Hyporeflexa left, with slight hypæsthesia left face. Jaw deviates to left. VI$^{th}$ = Left abducens palsy with diplopia. VII$^{th}$ = Slight droop right face.

VIII$^{th}$ = Deafness on left without tinnitus: impairment on right (*cf.* old otitis). Caloric and spinning tests give no reaction movements from the left labyrinth. The X-ray of the porus acusticus internus is inconclusive.

IX$^{th}$, X$^{th}$, XI$^{th}$ and XII$^{th}$ = Considerable dysarthria and dysphagia.

**Clinical diagnosis.**—"Left cerebellopontile-angle tumor."

*Nov. 23, 1914.* **Operation I.**—The usual bilateral suboccipital exploration. An unusual degree of bleeding occurred during the approach, necessitating an early ventricular puncture. Bone very thin and perforated by many vascular emissaries. Marked pressure cone. An unsatisfactory exploration in each recess failed to disclose a tumor. Closure.

**Post-operative and subsequent notes.**—Usual satisfactory primary wound healing (Fig. 65), but convalescence was protracted and the patient was not discharged until *Jan. 5, 1915,* there having been no obvious improvement in his condition aside from the relief of headaches. It should be stated, however, that further caloric tests on *December 25* showed a return of slight though definite reaction movements to cold in the left ear, and slight sound perception while the right ear was irrigated.

*Feb. 6, 1915. Readmission.* Considerable advance in local symptoms despite general improvement and gain in weight. Bedridden: falls heavily backward when put on feet. Marked dysarthria and deglutitory difficulties. Respiration at times difficult and irregular. Characteristic position of head. Protrusion of decompres-

sion wound. Some tinnitus referred to both ears. Both fork and Galton whistle slightly heard on left. Marked dynamic incoördination of the left arm and leg. Otherwise the cerebellar and extracerebellar symptoms about as before and point definitely to a left recess tumor. Further exploration advised.

*Feb. 12, 1915.* **Operation II.**—The wound was reopened in the line of the original incision. Protrusion and adhesions prevented satisfactory exploration of the angle, so that a

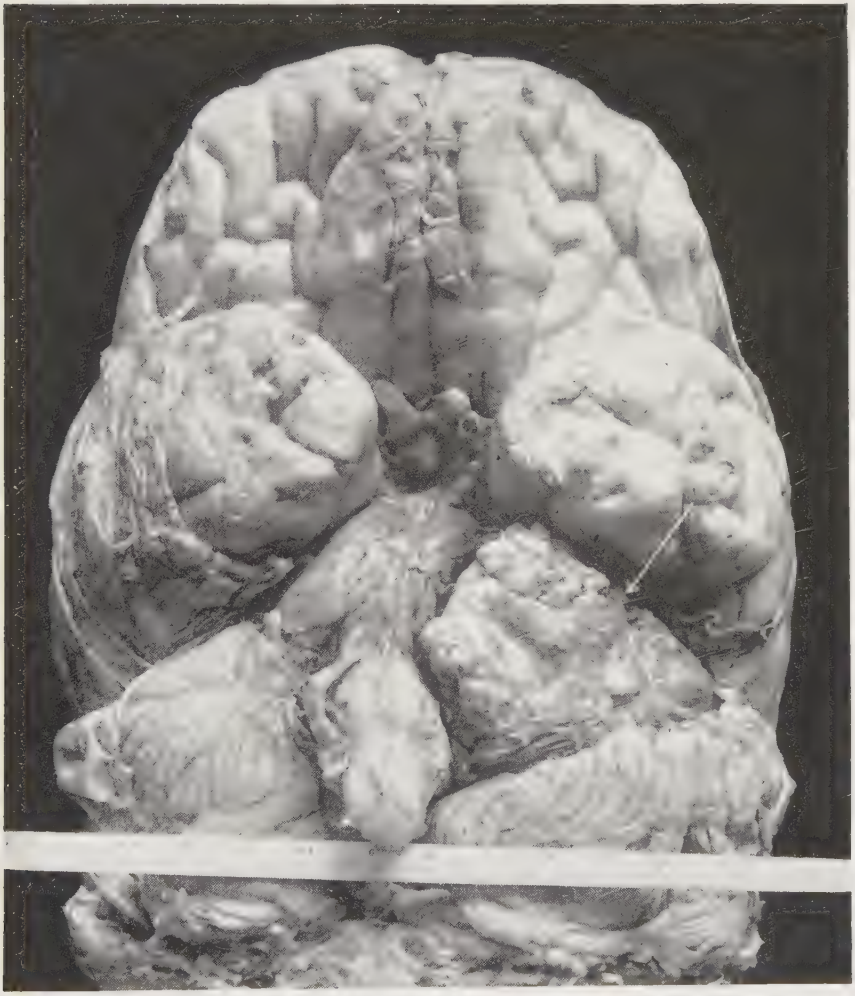

Fig. 66.—Case XV. Showing the base of the brain and the large acoustic tumor *in situ*. Note the small scars of herniations over the temporal lobes: the large size of the cerebellum, to which the soft parts still adhere: the scar of the porus attachment in the outer margin of the tumor (*cf.* Fig. 196).

transcortical incision was made through the left hemisphere in the hope of exposing the tumor, but it lay at such a depth that sufficient exposure for the intended intracapsular enucleation was impossible. The wound was closed.

Owing to respiratory embarrassment the patient was left face down on the operating table for the remainder of the day. He regained consciousness and appeared to be in good

condition. On being removed from the table, however, and placed on his side at 10 p. m., respirations immediately ceased; were restored, but after a time ceased again permanently.

**Postmortem examination.**—Marked pressure changes in the skull, which is thinned and digitated and practically without diploë. Calvarium in places thin as parchment. Porus acusticus not examined. The cerebellum is unusually large. Many villous herniations over the tips of the temporal lobes.

*The tumor* (Fig. 66).—In the left recess is a very large, nodular, cone-shaped acoustic tumor about 5 cm. in its longest diameter, which has crowded the cerebellum and pons away from the angle. Its upper surface corresponds with the under surface of the tentorium and its lower surface to the irregularities of the floor of the posterior fossa. In correspondence with the situation of the porus is a circular defect on the surface where the capsule has been torn from its attachments in the dilated

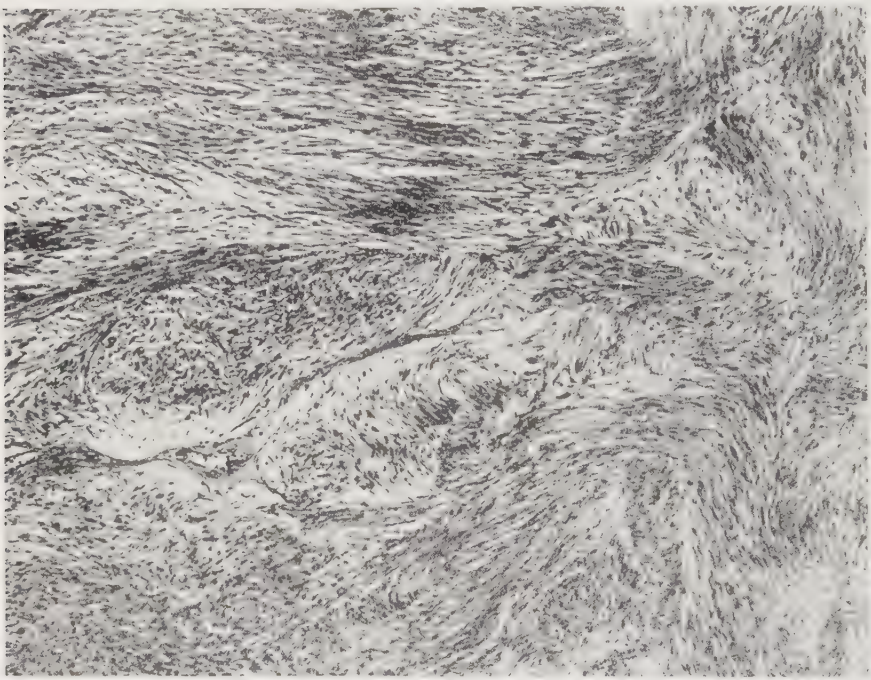

Fig. 67.—Case XV. Showing (× 80) hydropic interlacing fibrous bands (phosphotungstic acid hæmatin).

auditory canal (*cf.* Fig. 196). One special nodule of the growth has deeply indented the medulla in the situation of the olive. On dislocating the tumor outward a delicate attachment to the brain stem, apparently representing the VIII$^{th}$ nerve, can be made out. The VII$^{th}$ and V$^{th}$ are stretched out over the anterior surface and elongated to a length of 8 centimeters. At the posterior pole the IX$^{th}$, X$^{th}$ and XI$^{th}$ are similarly greatly elongated. To this we shall return in Chapter VII when discussing the pathology of these lesions.

*Histologically* the tumor, which might easily have been designated a "fibroma" (Figs. 67 and 68), shows the characteristic varied structure of an acoustic tumor. It is chiefly composed of œdematous interlacing bands of fibrous tissue with a marked tendency to whorl disposition of the cells about the smaller vessels. The collagen fibres are very abundant. Sharply demarcated are the areas of loose reticular tissue (Fig. 69) resembling

glioma with pseudo fibrils. Many cells have undergone a fatty change. There is hyaline about many of the blood vessels. The medulla and cord show a scattering of descending degenerations.

**Comment.**—The chronology of symptoms in this case was not clear and some confusion arose because of the relative bilateral deafness. And it is important to note that despite the large size of the tumor and the complete gross disappearance of the acoustic nerve, some hearing and slight reaction movements had returned after the decompression.

The first operation was difficult owing to great vascularity and extreme tension, and as there was no assurance from the clinical studies as to the character of the lesion, the exploration was doubtless a half-hearted one and the procedure was abandoned with the mere effort to relieve the intracranial



Fig. 68

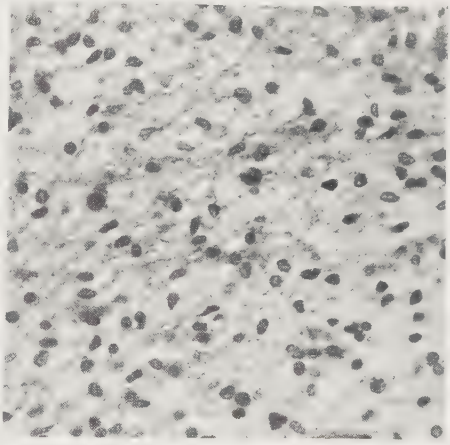

Fig. 69

Figs. 68, 69.—Case XV. Showing very cellular fibrous area and characteristic reticular area (×300).

tension. Even so, it is remarkable that so large a tumor could have escaped observation when the left recess was investigated.

The brief period of relief following the decompression indicates that a palliative suboccipital craniectomy, even with a wide bilateral defect, may give only a brief period of relief from the pressure of a large recess tumor despite the excellent results in many other cases in the series (*cf.* Cases IV, XXVIII, XXXI and XXXII) with presumable though unverified acoustic tumors which have been long benefited by this temporizing measure.

The postmortem study of the tissues from this case have been most instructive and will be further described in the general discussion of the pathology of these lesions.

The following case further illustrates the possible preservation of some auditory function even though the vestibular nerve may appear to be completely paralyzed.

## Case XVI

P.B.B.H. Surg. No. 2913. **An advanced left acoustic tumor with characteristic syndrome. Intracapsular enucleation. Recovery. Primary diagnosis, glioma.**

*May 14, 1915.* Admission of Andrew M. P., 48 years of age, a stone cutter, referred from the Massachusetts Charitable Eye and Ear Infirmary through Dr. James Ayer, with the diagnosis of tumor.

**Chronology of symptoms.**—For eighteen months tinnitus "like escaping steam" in left ear, later in both ears. Loss of hearing on the left.

For twelve months vision failing: unable to read for three months: of late, periods of amaurosis.

For six months attacks of dizziness with stumbling and staggering to right: occasional falling.

For five months periods of severe suboccipital pain accompanied by retraction of the neck. These seizures, which sound like cerebellar fits,

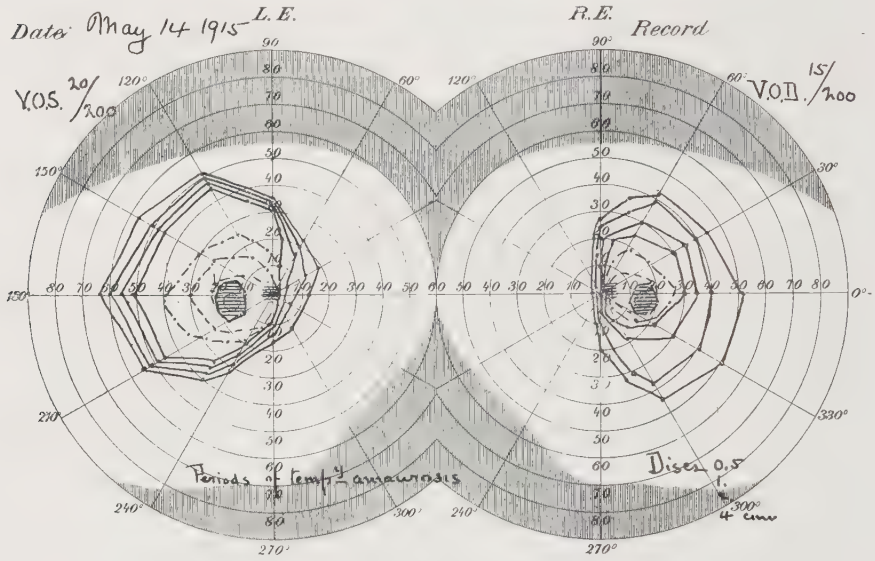


Fig. 70.—Case XVI. A good example of the so-called binasal hemianopsia which may accompany the atrophy secondary to a choked disc following obstructive dilatation of the ventricles.

have often been followed by a loss of consciousness and convulsive movements which involve the entire body. Of late they have occurred as often as four or five times a week.

Despite a negative Wassermann reaction he has had a prolonged antiluetic treatment with salvarsan before entrance, owing presumably to the presence of Argyll-Robertson pupillary reactions.

**Positive neurological findings.**—(A) *General pressure.* Choked disc of 4 D. with exudates and hemorrhages, subsiding with atrophy: vision 20/200. Fields (C. B. Walker) show a binasal hemianopsia (Fig. 70) with hemiopic pupillary reaction. X-ray shows dilated venous channels and secondary pressure absorption of the sella (Fig. 71).

(B) *Localizing.* (1) *Cerebellar.* Suboccipital tenderness. Cerebellar opisthotonoid seizures. Nystagmus in all directions. Romberg positive. Gait unsteady, tends to right. No definite ataxia, station and gait vary greatly from day to day: often normal.

Deep reflexes brisk to exaggeration: greater left than right.

(2) *Extracerebellar. Cerebral nerves.* V^th = Negative, corneal reflexes equal. VI^th =

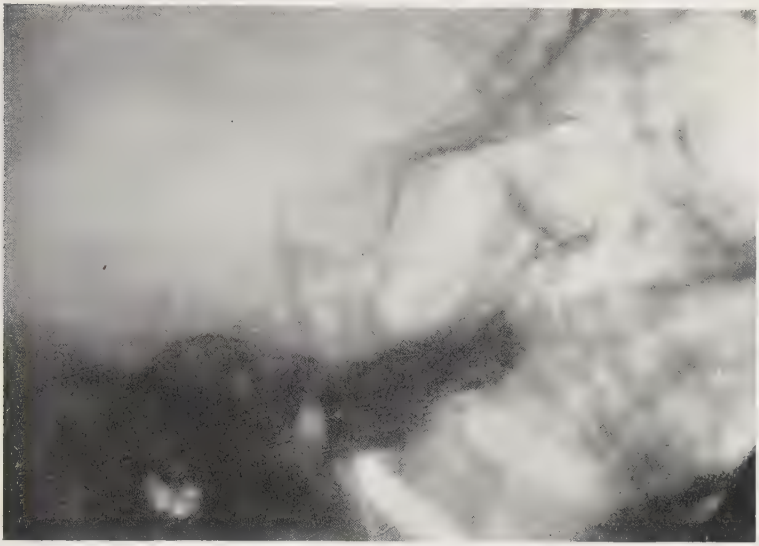

Fig. 71.—Case XVI. Early pressure changes in the sella.

Fig. 72.—Case XVI. Showing post-operative left facial paralysis.

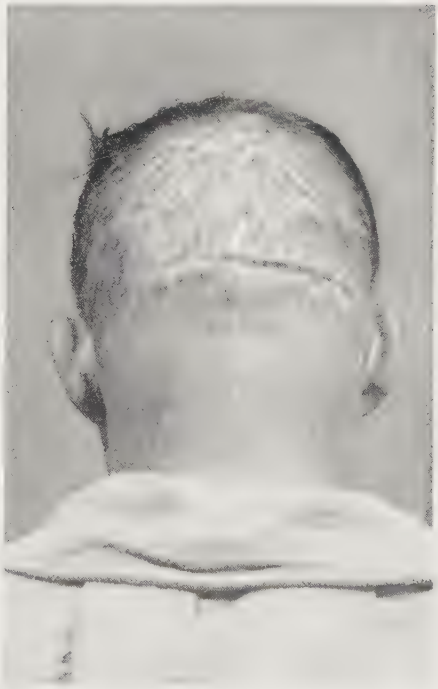

Fig. 73.—Case XVI. Showing wound after two weeks. Note scar of old, unrecorded scalp wound such as is often revealed on shaving.

Negative: history of diplopia. VII$^{th}$ = Slight but perceptible expressional weakness of right lower face.

VIII$^{th}$ = Constant bilateral tinnitus. Apparent complete loss of hearing on left, though fork occasionally heard and possibly some bone conduction preserved. Repeated labyrinthine tests (Bárány) give practically no reaction movements on left: normal responses on right. Left porus acusticus internus reported larger than right (later re-examination makes this doubtful).

IX$^{th}$, X$^{th}$, XI$^{th}$ and XII$^{th}$ = Some thickness of speech and difficulty of swallowing.

(C) *Misleading.* The convulsive attacks. Visual hallucinations with after images. Unequal pupils, left larger than right, with Argyll-Robertson reactions.

**Clinical diagnosis.**—"Extracerebellar tumor of left recess," according to the record.

*May 21, 1915.* **Operation.**—The usual bilateral suboccipital craniectomy. Owing to

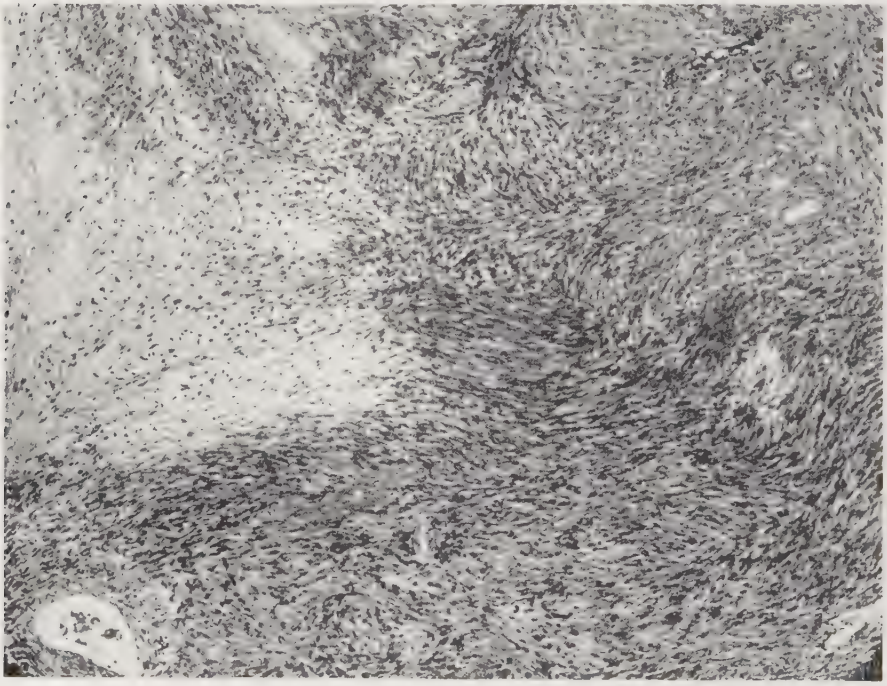

Fig. 74.—Case XVI. Showing dense interlacing fibrous bands on the right and a degenerated hydropic area on the left (phosphotungstic acid hæmatin: ×80).

tension a ventricular puncture was necessitated. Exploration of the left recess exposed what was taken to be a large, thick-walled lateral cistern containing an abundance of yellowish fluid. After the evacuation of this fluid further investigation revealed a typical angle tumor. A radical intracapsular enucleation was carried out without difficulty. Closure without drainage.

**Post-operative notes.**—No dysarthria or dysphagia, but the manipulations had led to a palsy of the left abducens and left facial nerves (Fig. 72). Healing without reaction (Fig. 73). Temporary increase of incoördination of left side with added impairment of gait. Subsidence of choked disc with practical blindness. The general picture, however, improved greatly, and he was discharged *July 18, 1915.*

**Pathological note.**—"The cells are arranged in parallel fashion and in places are massed with whorl formation. Blood vessels with extensively hyalinized walls. Many œdema-

tous areas and patches of degeneration. Numerous pseudo fibrils which stain blue with phosphotungstic hæmatoxylin. Diagnosis: "Glioma."

Recent studies show that the tumor is a typical acoustic growth. There is an abundance of pigment representing old hemorrhagic areas; numerous small, glioma-like cysts in the patches of degeneration; typical fields of characteristic loose reticular glioma-like tissue. Though the degenerative processes are unusually extensive, the character of the tumor is unmistakable (Figs. 74–76).

**Subsequent note.**—*Oct. 1, 1916* (17 months later). A letter from his physician, Dr. Woodruff, of Barre, Vermont, reports marked improvement, even in vision. Facial paralysis improving. Bilateral tinnitus persists: deafness of left ear not absolutely complete. No abnormalities of gait: able to walk long distances without fatigue.

**Comment.**—Attention may be drawn to a few points. The case furnishes a good example of what has been termed a binasal hemianopsia, a form of field distortion which sometimes occurs when a choked disc is sub-

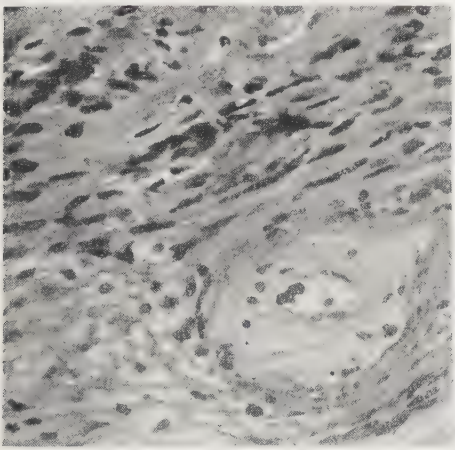

Fig. 75

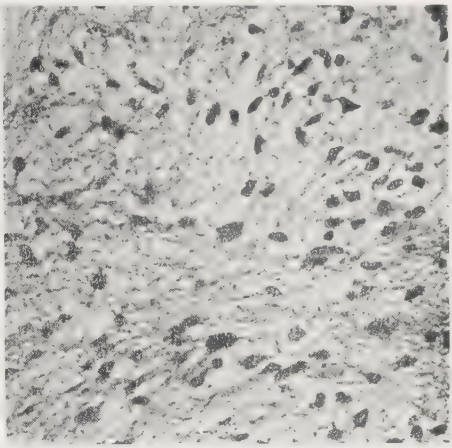

Fig. 76

Figs. 75, 76.—Case XVI. Showing a hyalinized blood vessel at the junction of a fibrous and reticular area: reticular area.

siding with atrophy. The subject has been discussed by C. B. Walker and myself[49] elsewhere, but this is even a better example than was available at the time of our report. It may be added that so far as preservation of vision is concerned, operations are always undertaken at this late stage of a choked disc with discouragement.

The character of the tinnitus referred to the right as well as the left ear suggested a possible bilateral lesion, but the exploration of the right recess was negative. The fact that on the affected side some hearing has been retained, whereas the labyrinthine reactions were lost, suggests, in support of Henschen's view, that the vestibular nerve, in this case at least, rather than the cochlear branch, was the primary seat of the tumor.

The histological diagnosis of glioma which was made, despite the gross appearance of the tumor, shows how confused we still were even a year ago in regard to these growths. The piece of tissue from which the original sections were made and on which the diagnosis was based fully justified the im-

pression, and only as a result of recent and more exacting studies was the true nature of the lesion certified. To this we shall return in the discussion of Case XXII and in subsequent chapters.

The history of the following case shows how misleading may be the gastric symptoms complained of by persons with intracranial disorders, the patient having been admitted to the medical service with a diagnosis of gastric carcinoma. The case is one of the few in the series in which the extracerebellar symptoms were practically confined to the acusticus alone.



Fig. 77.—Case XVII. Showing characteristic position of the head in a right recess tumor. Postoperative right facial palsy.

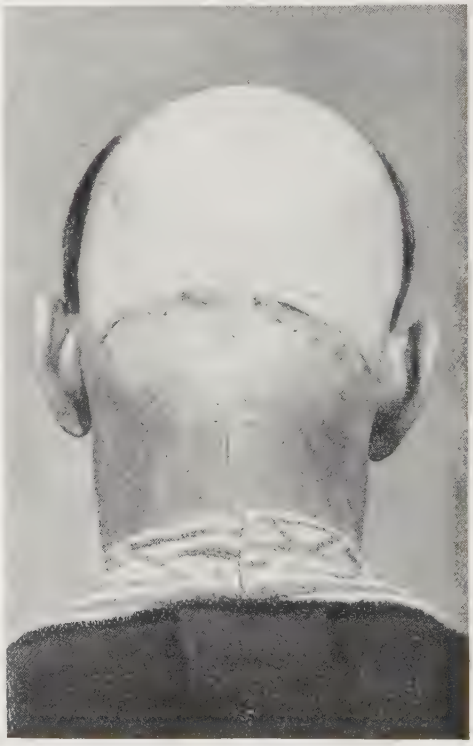

Fig. 78.—Case XVII. Wound on 12th day.

## Case XVII

P.B.B.H. Surg. No. 3032. **Right acoustic tumor with imperfectly developed cerebello-pontile-angle syndrome. Operation. Extensive intracapsular enucleation. Recovery.**

*May 30, 1915.* Admission to the Medical Service of Joseph D. McL., age 53, a wheelwright, for gastric symptoms. Stasis and anacidity were found. *Presumptive diagnosis:* "gastric carcinoma (though X-rays negative) with cerebral metastasis," in view of the choked disc. A diagnosis of "tabes dorsalis" had also been made, until disproved by a negative lumbar puncture. *Transferred* to Surgical Service *June 8.*

**Chronology of symptoms.**—Three years ago noticed roaring and buzzing sounds in the head. After two years the tinnitus became so bad it would keep him awake, and at this time, viz., one year ago, he began to grow deaf in right ear. Soon attacks of dizziness occurred.

For one year occasional fleeting paræsthesias over right face, tongue and teeth. For six months frontal headaches: never severe. For three months failing vision. For two months vomiting and continued tinnitus: he cannot tell in which ear. For six weeks unsteady gait. Worked until two months ago. Loss of twenty-five pounds' weight in four months.

**Positive neurological findings.**—(A) *General pressure.* Choked disc of 4 D. with hemorrhages and pallor of beginning secondary atrophy. Pronounced vomiting. No radiographic evidences of increased pressure.

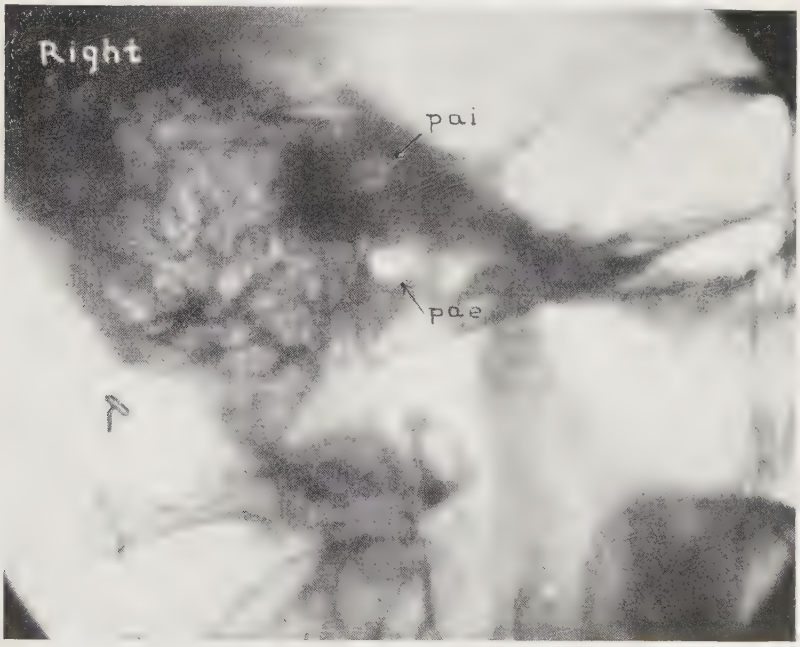


Fig. 79.—Case XVII. X-ray of right mastoid at the second admission. Interpreted as showing obscuration and possible slight enlargement of the porus internus (*p.a.i.*). Porus externus (*p.a.e.*). Note the secondary sellar thinning.

(B) *Localizing.* (1) *Cerebellar.* Fine, poorly sustained nystagmus to right alone. Slight incoördination of right arm and leg, with coarse tremor. Staggering gait deviating to right: variable. Romberg variable: tends occasionally to fall to right.

Deep reflexes sluggish on right: active left.

(2) *Extracerebellar. Cerebral nerves.* $V^{th}$ = Negative. Corneal reflex normal. History of paræsthesias. $VI^{th}$ and $VII^{th}$ = Negative.

$VIII^{th}$ = Complete cochlear and vestibular nerve paralysis. No caloric reaction movements. Responses normal on left. No note of condition of porus acusticus. (Later study negative.)

$IX^{th}$ to $XII^{th}$ = Negative. No dysarthria or dysphagia.

(C) Misleading. Right pupil larger than left. Right leg smaller and weaker than left (old poliomyelitis?).

**Clinical diagnosis.**—"Right cerebellopontile-angle tumor": acoustic lesion not specified.

*June 22, 1915.* **Operation.**—The usual bilateral suboccipital craniectomy. The tension was not great and a ventricular puncture not needed. No cerebellar pressure cone, but a large posterior cistern was present. The tumor, which was capped by encysted fluid, was readily exposed, its position being more posterior than usual and impinging on the bundle of nerves passing into the foramen lacerum, where the growth was distinctly adherent. The capsule was incised and the comparatively non-vascular contents were almost entirely scooped out, leaving the thin collapsed outer shell of the growth in place. Wound closure without drainage. No complications.

**Post-operative note.**—Considerable hiccoughing and some temporary dysarthria. Paralysis of the right facial (Fig. 77) and of right abducens. An extensive herpes developed over the right trigeminal field. Healing *per primam* (Fig. 78). Subsidence of choked disc. Marked improvement in all other respects. Discharged on *July 15* with possibly some return of hearing in the right ear (?).

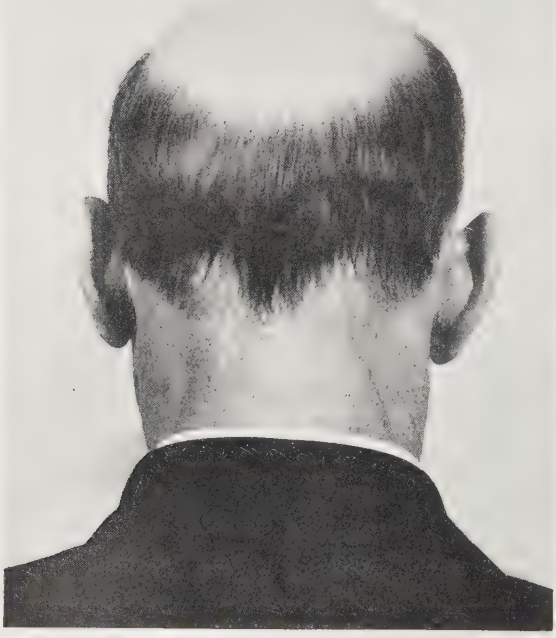

Fig. 80.—Case XVII. Absence of suboccipital protrusion: after two years.

**Subsequent notes.**—*Aug. 21, 1916.* Examination after one year. Very good condition: at work: walks with practically no instability, though Romberg positive. Slight dysmetria of right arm. Facial paralysis still complete, and right deafness also, with no present tinnitus. Corneal reflexes normal. No headaches or vomiting. Reading vision retained. X-rays of pori interpreted as showing a dilated meatus on the right (Fig. 79). Twenty pounds' gain in weight. V$^{th}$ and VI$^{th}$ unimpaired.

*Mar. 23, 1917. Re-examination.* Has been having X-ray exposures of tumor area. General condition remains excellent. No pressure symptoms: no protrusion (Fig. 80). *Cerebellar*: Romberg remains positive; a few nystagmoid twitches to either side. *Cerebral nerves:* Total paralysis of right VII$^{th}$ and VIII$^{th}$ persists. Corneal reflex normal. Stereo-Röntgenograms of the pori show the right meatus internus to be unchanged.

**Pathological note.**—The histological report upon the tumor fragments called attention to appearances resembling a fibro-endothelioma (Fig. 81), whereas in other places the tissue suggested an œdematous glioma. No calcareous (psammoma) masses observed. A diagnosis of "endothelioma" was returned.

A recent review of other fragments of this tissue shows it to be a characteristic acoustic tumor with fibrous bands having whorl dispositions of the nuclei, marked hyaline changes about the vessels, and a few areas of loose reticular structure resembling glioma, though containing no demonstrable fibrils.

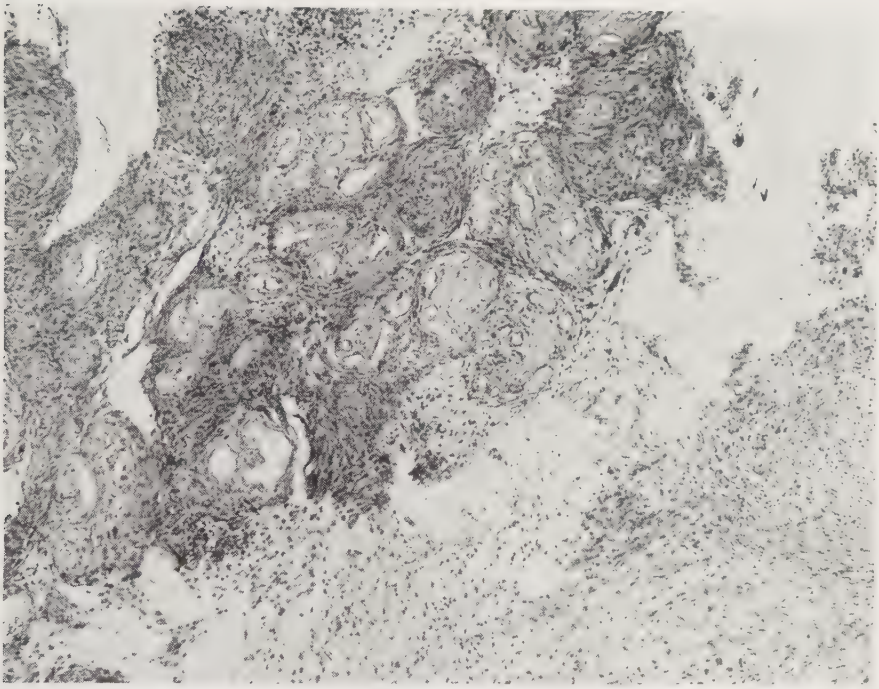

Fig. 81.—Case XVII. Area from tumor giving suggestion of endothelioma from the arrangements of the cells around hyalinized areas. Most of the field of reticular tissue (× 80: hæmatoxylin eosin).

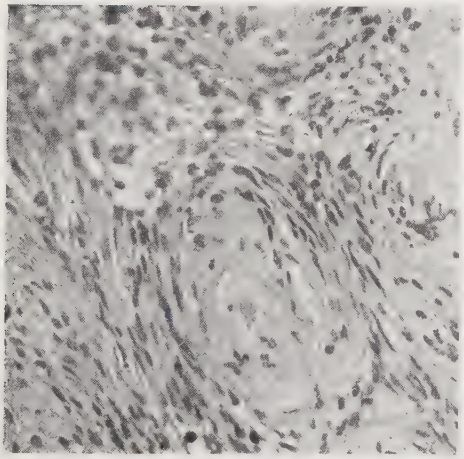

Fig. 82

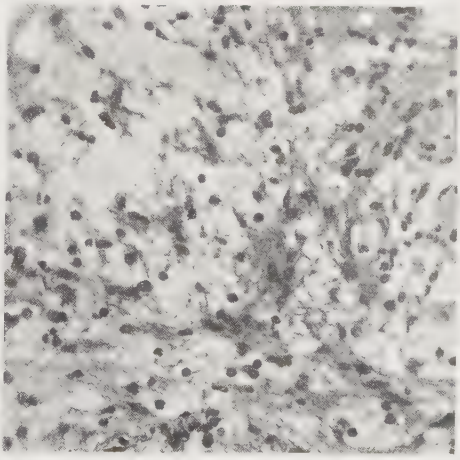

Fig. 83

Figs. 82, 83.—Case XVII. Showing fibrous and reticular areas.

**Comment.**—The case is notable for the fact that the extracerebellar symptoms at the time of admission were confined to the acusticus and, as was true also of Cases X and XVI, there was not even a loss of the corneal reflex. Indeed, the cerebellar symptoms were also inconspicuous. The fact, however, that the VII$^{th}$ nerve was closely incorporated in the capsule of the growth though without functional impairment is shown by its having been permanently damaged by the supposedly intracapsular manipulations during the enucleation. As demonstrated at the operation, the IX$^{th}$, X$^{th}$ and XI$^{th}$ nerves were also stretched by the growth without any interference of function.

The suggested temporary return of some hearing in the affected ear after the operation was possibly largely subjective. It could not be conclusively proven, and at the time of his recent examination the VIII$^{th}$ paralysis subjectively and objectively was again complete.

The following case furnishes a typical example of the full blown symptomatology of an acoustic tumor. It was the first case in the series to be reported as having an unmistakable enlargement of the internal meatus, but later recourse to stereoscopy has shown that this was an error of interpretation. Fortunately the operation was performed early enough to preserve normal vision. The surgical result, as in the two preceding cases, was favorable.

## Case XVIII

P.B.B.H. Surg. No. 3191. **Left acoustic tumor with typical cerebellopontile-angle syndrome. Intracapsular enucleation. Recovery.**

*July 6, 1915.* Admission of Leon G., age 53, a shoemaker, referred by Dr. John Sproull of Haverhill, Mass., with the diagnosis of "a cerebellopontile tumor."

**Chronology of symptoms.**—For four or five years tinnitus of left ear, with impaired hearing advancing to deafness in the course of three years. Frontal headaches from the outset: also attacks of vertigo and dizziness, which have been constant for six months.

For one year numbness of left face and tongue, and loss of taste.

For six months staggering gait, thickness of speech, and deglutitory difficulties.

For four months suboccipital pains radiating through to forehead, chiefly on left and associated with stiffness of the neck. Recent blurring of vision.

**Positive neurological findings.**—(A) *General pressure.* Bilateral choked disc of 4 D. with hemorrhages and exudates. X-ray shows dilated venous channels. Absorption of posterior surface of dense dorsum sellæ (*cf.* Fig. 89).

(B) *Localizing.* Head tilted toward left occiput: hyperflexion painful: some tenderness on pressure. (1) *Cerebellar.* Nystagmus lateral and rotary: equal right and left. Moderate coarse ataxia of left arm and leg, with dysmetria and impaired diadococinesia. Romberg positive. Gait unsteady.

Deep reflexes active and equal.

(2) *Extracerebellar. Cerebral nerves.* V$^{th}$ = Left corneal areflexa with hypæsthesia over entire left trigeminal area. No deviation of jaw. VI$^{th}$ = Negative: history of diplopia. VII$^{th}$ = Widened left palpebral cleft, and corner of mouth droops.

VIII$^{th}$ = Total deafness on left, and complete loss of labyrinthine reactions. X-ray of porus acusticus shows a presumable dilatation of the left internal meatus (*cf.* later note).

IX$^{th}$, X$^{th}$ and XI$^{th}$ = Marked dysarthria and dysphagia. XII$^{th}$ = Tongue deviates to right.

**Clinical diagnosis.**—"Left cerebellopontile tumor."

*June 13, 1915.* **Operation.**—Usual bilateral cerebellar exposure. A large posterior cistern disclosed without definite pressure cone. Exposure of tumor in left recess: partial intracapsular enucleation: chief mass of tumor measured about 3 cm. in diameter (Fig. 84).

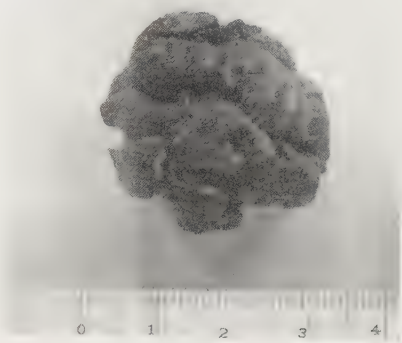


Fig. 84.—Case XVIII. Photograph of chief mass of tumor removed (nat. size).

**Post-operative notes.**—Uneventful convalescence. Patches of herpes on left V$^{th}$ skin field. Healing without reaction (Fig. 85). Marked subsidence of practically all cerebellar symptoms. Improvement also in the extracerebellar group, shown particularly in the V$^{th}$ and VII$^{th}$, though the left acoustic paralysis remained unmodified. Discharged *July 30, 1915.*

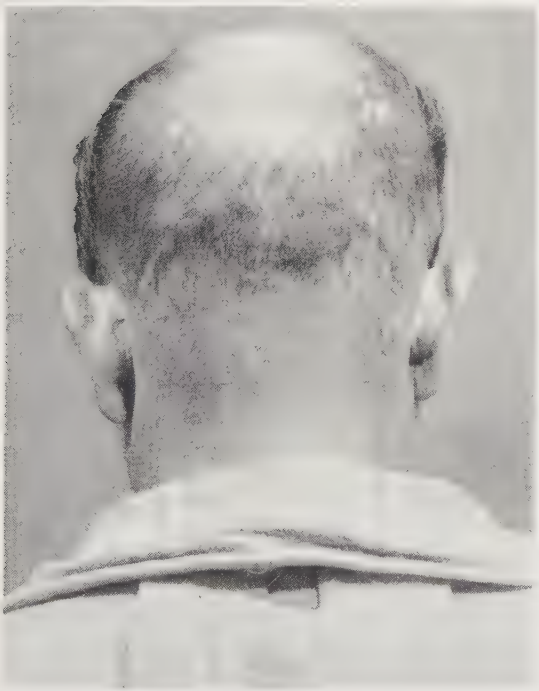

Fig. 85.—Case XVIII. Showing site of operation after three weeks.

**Subsequent notes.**—*Sept. 25, 1915.* Reports for examination: "Well enough to work": some dizziness: some involvement of the V$^{th}$ and VII$^{th}$ persists and the VIII$^{th}$ remains paralyzed.

*Aug. 17, 1916.* Returns for examination. Very well: at work. A gain of 40 pounds in weight (Figs. 86, 87, 88). Vision normal. No diplopia since operation. Disc flat: cup reformed. Practically no cerebellar symptoms. Persistence of left deafness and some numbness of face and tongue, with loss of taste. Further X-ray studies (single plate) of the pyramidal bones show an apparent absorption defect in the region of the left internal meatus (Fig. 89).

*Mar. 23, 1917. Re-examination.* Has been having X-ray treatments directed toward the seat of the lesion. General condition remains excellent. At work: full time, stitching shoes in shoe factory. Practically no symptoms except persistent total paralysis of the VIII$^{th}$ and slight hypæsthesia of the left V$^{th}$. Renewed studies (stereoscopic) of the pori show that the early impression of a dilated porus on the right was unfounded (*cf.* Figs. 228–231).

Fig. 86 Fig. 87 Fig. 88

FIGS. 86, 87, 88.—Case XVIII. Condition after 18 months, showing gain in weight: absence of protrusion: symmetrical expressional movements.

FIG. 89.—Case XVIII. Plate taken (Aug. 17, 1916) in an unfavorable position bringing all four meatus near together on the field. Showing (arrow) what was then mistaken to be an absorption measuring 5 by 10 mm. of the left meatus internus.

**Pathological note.**—Fragments of the tumor were reported as showing mostly fibrous tissue with nuclei arranged in whorls. Diagnosis: "Endothelioma." A later and more

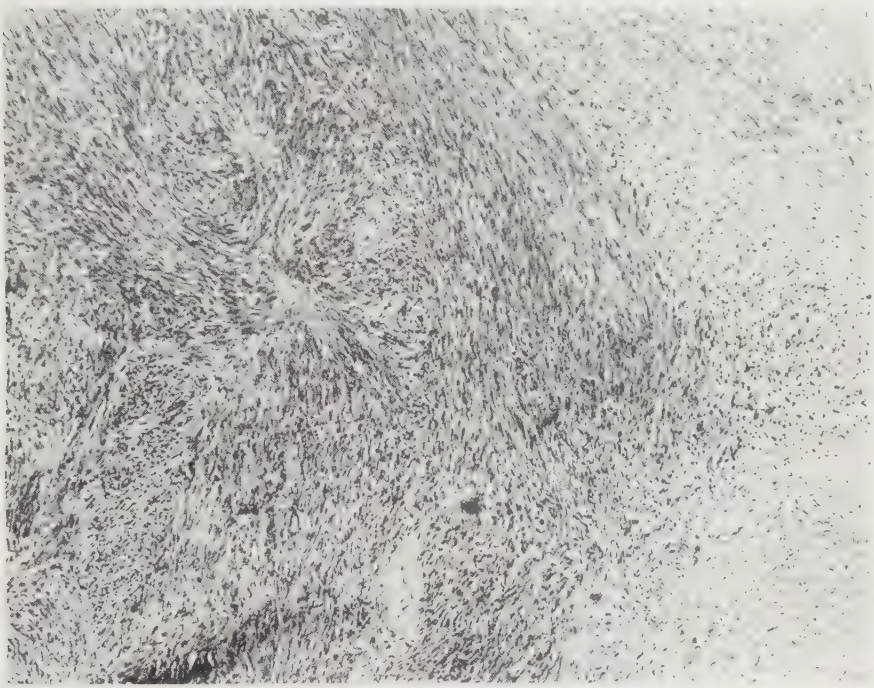

Fig. 90.—Case XVIII. Typical fibrous area to left and loose reticular œdematous field to right (× 80: hæmatoxylin eosin).

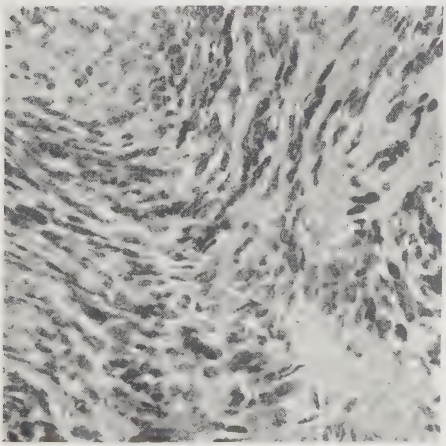

Fig. 91

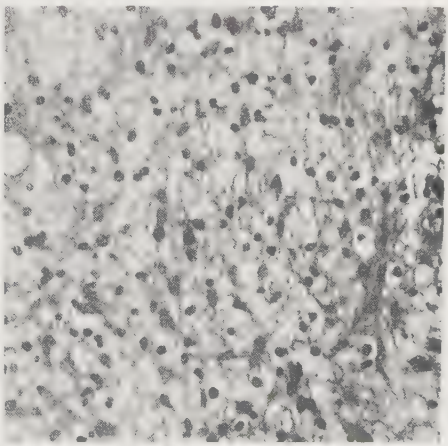

Fig. 92

Figs. 91, 92.—Case XVIII. Showing (× 300) architecture of fibrous and reticular areas.

thorough study has shown the characteristics of a typical acoustic neuroma (Figs. 90, 91, 92). There are sharply demarcated bundles of fibrous tissue with fairly characteristic

dispositions of the nuclei in whorl and palisade arrangements: also many areas of loose reticular tissue, in which, however, no fibrils were demonstrated.

**Comment.**—No more typical example could be given of the symptomatology of one of these acoustic tumors (though it does not include, as we at first supposed, a dilated porus), nor could a more favorable immediate surgical outcome be desired. With the knowledge, however, that the tumor removal is incomplete and the recollection of the experience with the earlier patients in the series (e. g., Case III), the necessity of some further intervention in the course of a few years must be expected. This period is awaited with greater equanimity than in the case of some others in the series, in view of the patient's ability, meanwhile, to resume his occupation owing to his unimpaired vision.

The patient whose history follows, doubtless on the basis of the three foregoing fairly successful and uncomplicated operations, was subjected to a more radical attempt in the direction of a complete enucleation than had been ventured upon since the sorry experiences with the last cases in the Baltimore series.

## Case XIX

P.B.B.H. Surg. No. 3497. **Right acoustic tumor with an advanced cerebellopontile-angle syndrome. Contralateral symptoms pronounced. Attempted radical extirpation. Pneumonia. Death on seventh day.**

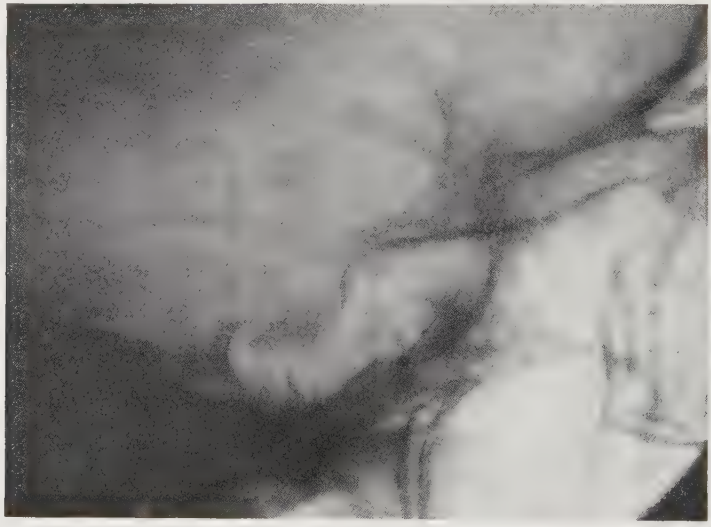

Fig. 93.—Case XIX. Showing secondary absorption changes in sella. Dorsum sellæ represented by a thin plate.

*Sept. 2, 1915.* Admission of Ida M. W., 47 years of age, referred by Dr. C. A. Ball of Muncie, Ind.

**Chronology of symptoms.**—For three years tinnitus on right followed by relative deafness, the intensity of which fluctuated and markedly improved following a period of local treatment.

Fig. 94

Fig. 95

FIGS. 94, 95.—Case XIX. Showing what was interpreted, doubtless erroneously, as a slightly dilated porus acusticus internus on the right. Normal on the left (*p.a.i.*). Position not ideal.

For two years suboccipital discomforts and cervical stiffness: also marked dizziness with falling attacks (vertiginous?).

For eighteen months disturbance of vision, increasing to practical blindness for past eight months.

For one year staggering gait: also a sensation of numbness accompanied by a "drawing up of right face."

For eleven months periods of diplopia: also nausea and much vomiting, projectile in character.

For eight months numbness and neuralgic pains on both sides of face and tongue: in consequence an operation for enlarged turbinates was undertaken without relief.

Of late marked dysarthria; also many distressing opisthotonoid seizures (cerebellar attacks?), lasting several minutes, with rigidity, arching of back and occasionally consciousness is lost. Considerable mental deterioration.

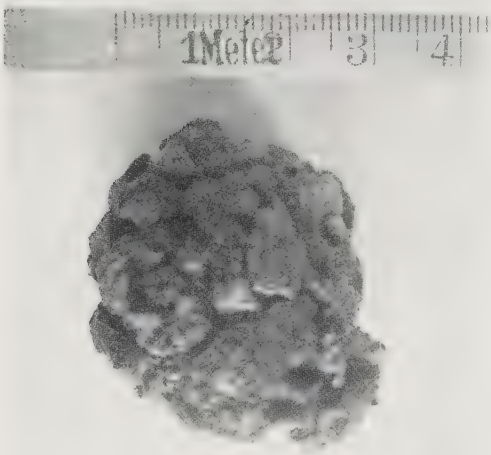


Fig. 96.—Case XIX. Showing the amount of tissue removed. Collected fragments.

**Positive neurological findings.**—(A) *General pressure.* Choked disc: right, 4½ D.; left 6 D.: with hemorrhages and secondary atrophy. Extracranial vascular dilatation with exophthalmos. X-ray: secondary pressure absorption of sella (Fig. 93): enlargement of venous channels. Mentality impaired: drowsiness: disorientation.

(B) *Localizing.* Suboccipital tenderness and discomfort on flexion. (1) *Cerebellar.* Nystagmus very brief: few jerks only. Conjugate deviation poorly sustained in both directions. Romberg positive: falls to right. Gait very unsteady: progression impossible. Marked cerebellar incoördination, particularly of right arm and leg (ataxia, dysmetria, adiadococinesia, etc.).

(2) *Extracerebellar. Cerebral nerves.* $V^{th}$ = Bilateral areflexa; also bilateral hypæsthesia of skin and mucous membranes. Deviation of jaw to left. $VI^{th}$ = Slight weakness of both abducentes. $VII^{th}$ = Paresis of right lower face, shown only on expressional movements: bilateral parageusia.

$VIII^{th}$ = Right deafness with "roaring" tinnitus. Bárány tests give negative labyrinthine responses on right. Right porus acusticus internus appears larger than left (Figs. 94, 95).

$IX^{th}$, $X^{th}$ and $XI^{th}$ = Slurring speech. $XII^{th}$ = Protrusion to left; variable.

**Clinical diagnosis.**—"Extracerebellar tumor, probably of right lateral recess," as recorded.

*Sept. 4, 1915.* Operation.—Usual bilateral exposure. Suboccipital bone found greatly thinned and vascular. Puncture of lateral ventricle to relieve tension. Exposure of tumor extending far down against side of medulla. Thorough intracapsular enucleation (Fig. 96) followed by extirpation of lower two-thirds of the vascular capsule, which was peeled from the side of the pons and medulla with but slight bleeding. Closure.

**Post-operative notes.**—Marked increase of dysarthria with dysphagia. Inhalation bronchitis with subsequent pneumonia and death on *September 10.*

**Autopsy.**—Brain removed after fixation *in situ.* No note on the condition of the porus acusticus. In the right recess is found the upper pole of the tumor (Fig. 97), which consists of little more than a shell of the capsule, from which most of the contents have been scooped out. No evidences of trauma or contusion apparent on the side of pons or medulla. The

Fig. 97.—Case XIX. Base of brain, from which right cerebellar hemisphere has been cut away to expose remaining fragment of anterior shell of tumor consisting largely of capsule (*cf.* Fig. 195).

flattened and greatly elongated trigeminal root is wrapped about the upper surface of the tumor (Fig. 195). No trace found of the acoustic nerve and the facial is practically incorporated in the tumor capsule. The relation of the lower four nerves to the tumor is lost.

**Histological note.**—Sections of the operative fragments, as in some of the other recent cases, were first diagnosed as "glioma" and this was later changed to "endothelioma." On recent re-examination of the tissue, sections clearly show what we now recognize as the distinguishing features of an acoustic tumor: (1) bands of somewhat hydropic fibrous tissue

with some tendency of the nuclei toward a disposition in whorls and palisades (Figs. 98, 99); (2) fields of œdematous-looking reticulated tissue (Fig. 100) resembling glioma in which

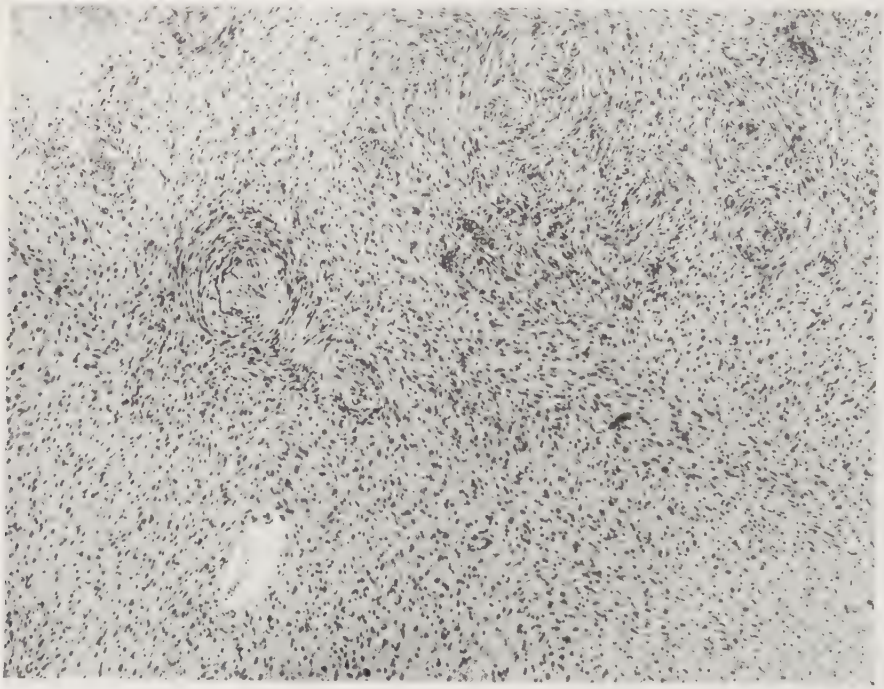

Fig. 98.—Case XIX. Showing œdematous fibrous area with characteristic disposition of nuclei (× 80: phosphotungstic acid hæmatin).

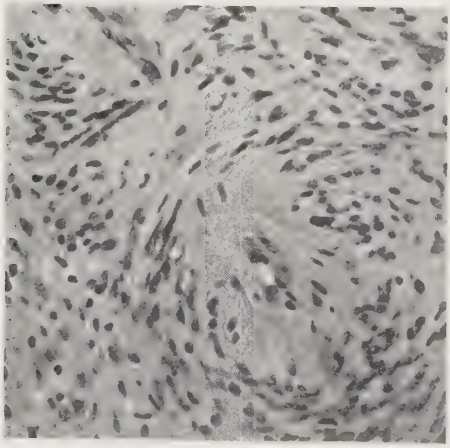

Fig. 99

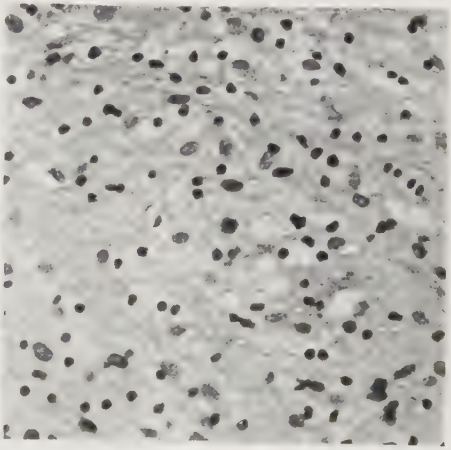

Fig. 100

Figs. 99, 100.—Case XIX. Showing (×300) architecture of fibrous and reticular areas.

occasional pseudo-fibrils may be seen and areas of marked fatty degeneration; (3) hyaline changes about the blood vessels.

**Comment.**—The syndrome in this case was advanced and the bilateral sensory disturbances were more marked than in any other case in the series (*cf.* Case VIII). The right trigeminal root was greatly elongated, but nothing was found in the condition of the left $V^{th}$, as seen postmortem, to account for the contralateral hypæsthesia.

The temptation to carry out such a radical procedure should not have been yielded to, for the marked preoperative dysarthria gave sufficient warning of the hazards which would be run. In spite of the large amount of enucleated tissue it can be seen from the postmortem findings how incomplete these procedures must necessarily be.

---

Doubtless under the restraining influence of the fatality in the last case, the operation in the two succeeding ones amounts to little more than a decompression together with the evacuation of the obstructed lateral cistern. Though in each the underlying tumor was exposed, only enough tissue was removed to certify the nature of the growth.

The syndrome of the following, the first of these cases, was a most typical one, for though there was complete paralysis of the acusticus, there had been no tinnitus and all signs (even of the corneal areflexa) pointing to an involvement of the adjacent nerves were totally absent.

## Case XX

P.B.B.H. Surg. No. 3636. **Right acoustic tumor with undeveloped cerebellopontile-angle syndrome. Operation: fragmentary intracapsular enucleation with decompression. Recovery.**

*Sept. 30, 1915.* Admission of Ada R., age 41, referred by Dr. LaSalle Archambault of Albany with the diagnosis of a left cerebellopontile-angle tumor.

**Chronology of symptoms.**—For four years a gradual loss of hearing in right ear. First noticed complete deafness two years ago when trying to use telephone. No tinnitus at any time.

For eighteen months an increasing uncertainty of gait and station. For about the same period a sense of intracranial discomfort rather than headache: more marked on left: never suboccipital: not constant. No vomiting.

For fourteen months failing eyesight. Seven months ago a choked disc was first observed. A rapid loss of visual acuity during past month. Of late her former tendency to stagger has become less marked.

**Positive neurological findings.**—(A) *General pressure.* Receding choked disc with atrophic pallor; swelling 4 D.: acuity 20/200 left: 20/100 right. X-ray shows a secondary pressure atrophy of the dorsum sellæ (Fig. 101): also an enlarged sphenoparietal sinus.

(B) *Localizing.* Head held tilted to left. No suboccipital tenderness. (1) *Cerebellar.* Nystagmus horizontal and vertical: quick component to left. Coarse tremor of both arms: no true ataxia. Positive Romberg. Gait fairly steady with some deviation to right.

Deep reflexes equal and hyperactive.

(2) *Extracerebellar. Cerebral nerves.* $V^{th}$ = Not involved: corneal reflexes active. $VI^{th}$ = Negative. $VII^{th}$ = Slight apparent left facial weakness (probably an expressional characteristic unrelated to the lesion).

$VIII^{th}$ = Right deafness complete: caloric tests show loss of all responses on the right and diminished left vestibular activity. Comparative X-ray plates of right and left pori inconclusive.

$IX^{th}$, $X^{th}$, $XI^{th}$ and $XII^{th}$ = Negative.

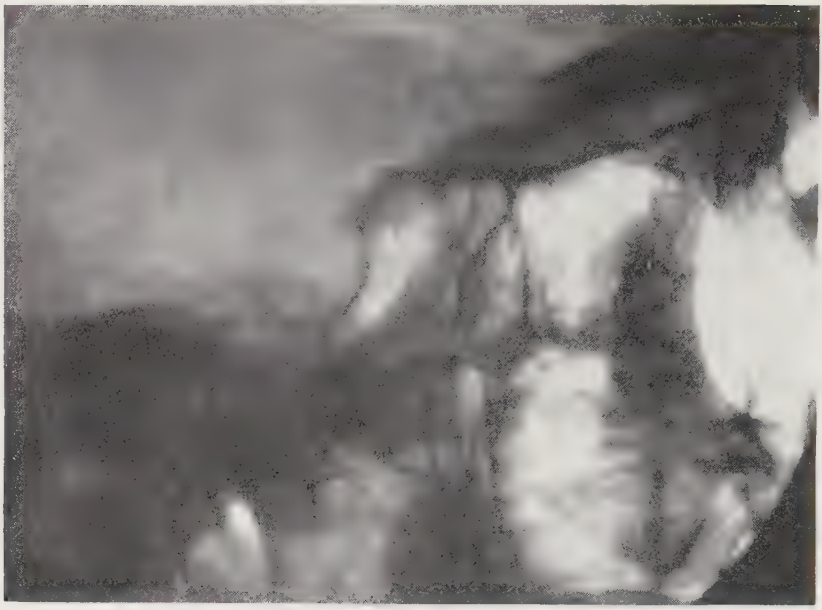

Fig. 101.—Case XX. Showing a large sella with some pressure absorption of the dorsum.

**Clinical diagnosis.**—" Right cerebellopontile-angle tumor—acoustic neuroma."

*Oct. 7, 1915.* **Operation.**—Usual bilateral exposure. Marked tension revealed with foraminal herniation (pressure cone). Left ventricular puncture necessitated. Tumor in right recess underlying a dilated cistern: readily exposed: partial intracapsular enucleation. Closure.

**Post-operative notes.**—Convalescence uneventful except for recurring spells of vomiting. Perfect healing (Fig. 102). Distinctly better in all respects. The choked disc subsided, with preservation of considerable vision on the right. Slight return of hearing on right for loud sounds! Discharged *Nov. 11, 1915*, greatly improved in every way.

**Subsequent notes.**—*Aug. 20, 1916.* Chief complaint: imperfect vision which prevents her reading and sewing. Able to be about alone.

*Feb. 23, 1917.* Report from physician. Condition excellent. Vision 6/30: persistent right deafness complete. Slight unsteadiness: gets about actively. Has had X-ray treatment for her tumor.

Fig. 102.—Case XX. Showing practically invisible wound on 18th day.

**Pathological note.**—A primary diagnosis of "glioma," which was subsequently changed to "endothelioma," was made from the sections. A re-examination of the tissue shows it to be a typical acoustic neuroma with fibrous areas containing nuclei having a disposition to whorl arrangements and considerable infiltration with fat cells. A few loose reticular areas with the architecture of a glioma but no fibrils (Figs. 103–106).



Fig. 103

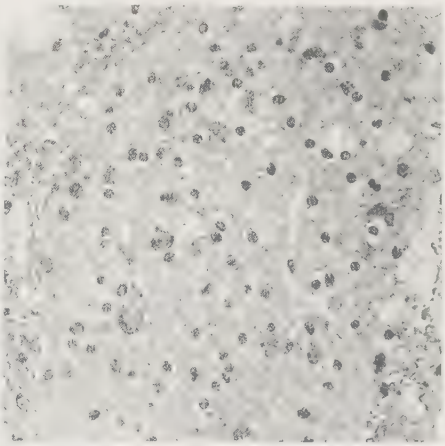

Fig. 104

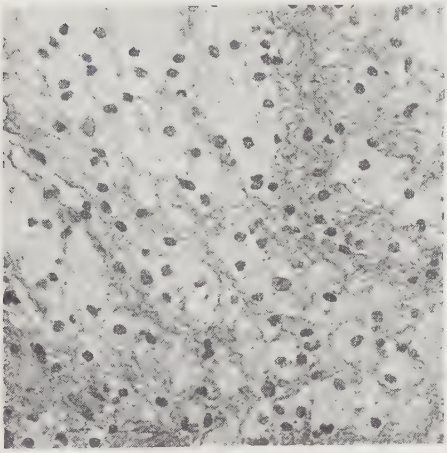

Fig. 105



Fig. 106

FIGS. 103, 104, 105, 106.—Case XX. Showing (× 300) (1) fibrous and (2) reticular areas, (3) infiltration with fat cells, and (4) Alzheimer's stain for fat.

**Comment.**—The striking feature of this case, as already pointed out, was the total absence of involvement, subjective or objective, of any of the adjacent cerebral nerves even though the VIII$^{th}$ showed what appeared to be a total paralysis. That some fibres, however, remained intact was shown (as in Case III) by the partial return of hearing after the operation. The tumor was large enough, nevertheless, to have produced marked pressure changes with secondary changes in the optic nerve which

have permanently affected her vision. Though a choked disc was observed seven months before the operation, there were unfortunately many delays, during which various unavailing medicinal measures were given trial.

As in the preceding case, the operation on the patient whose history follows, aside from the decompression, was limited to the mere fragmentary removal of an intracapsular portion of the tumor for diagnostic purposes.

## Case XXI

P.B.B.H. Surg. No. 3633. **Left acoustic tumor with unmistakable though undeveloped lateral recess syndrome. Fragmentary enucleation with decompression. Recovery.**

*Sept. 30, 1915.* Admission of Mrs. H. E. T., 35 years of age, referred by Dr. M. F. Irwin of Winnipeg.

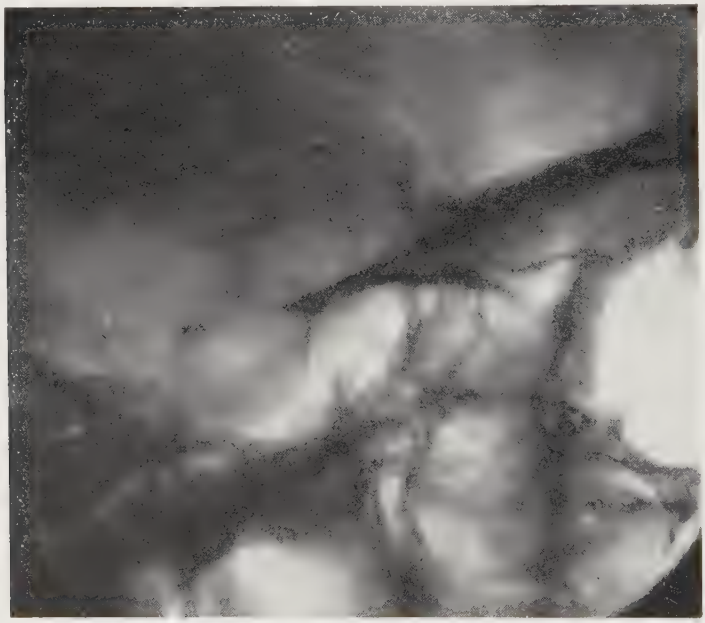

Fig. 107.—Case XXI. Showing secondary pressure changes in the sella turcica.

**Chronology of symptoms.**—Five years ago first accidentally observed a left deafness on putting her finger in her right ear.

For four years headaches, becoming severe for eighteen months, limited chiefly to the left side and extending from frontal into suboccipital region, with stiffness of neck.

For eighteen months tinnitus, described as a "whistling wind."

For six months blurring of vision with occasional periods of diplopia. Some periods of dizziness, which has been ascribed to "biliousness," and at these times she is apt to be unsteady on her feet, objects appear

to revolve about her and she may stagger, but has never fallen. No nausea or vomiting. She has recently been at the Mayo Clinic, where a choked disc was observed in time to prevent an operation for cholecystitis, the diagnosis of which had been made.

**Positive neurological findings.**—(A) *General pressure.* An acute bilateral choked disc of 8 diopters: acuity of vision unimpaired. On X-ray: marked secondary pressure changes in sella (Fig. 107), with dilated venous channels.

(B) *Localizing.* Suboccipital soreness and stiffness, especially on left. (1) *Cerebellar.* Nystagmus slight but present in all directions: quick component to left. Gait and station good. Possibly slight ataxia on left.

Deep reflexes active and equal.

(2) *Extracerebellar. Cerebral nerves.* V$^{th}$ = Left corneal hyporeflexa: sensation elsewhere apparently normal. VI$^{th}$ = Negative: history of diplopia. VII$^{th}$ = Negative.

VIII$^{th}$ = Left: thinks she hears Galton whistle, and some bone conduction apparently preserved, but on irrigating right canal deafness appears to be complete. Caloric tests show some slight labyrinthine responses on the left: right normal. The two pori acustici interni are of equal size and small.

IX$^{th}$, X$^{th}$, XI$^{th}$ and XII$^{th}$ = Negative.

**Clinical diagnosis.**—"Left cerebellopontile-angle syndrome: probably an acoustic tumor."

*Oct. 5, 1915.* **Operation.**—Usual operation: no complications. Exposure of left recess tumor which was surmounted by a large encysted collection of subarachnoid fluid. Only a fragment of the tumor was removed.

Fig. 108.—Case XXI. Photograph after three weeks, showing collection of fluid under solidly healed scalp from imperfect closure of deeper layers.

**Post-operative notes.**—Considerable increase of dizziness, with nausea for some days. Healing without reaction, but perfect result impaired by a collection of fluid which subsequently found its way under the scalp (Fig. 108). The high grade of choked disc subsided with a considerable loss of visual acuity. Discharged *Nov. 13, 1915,* at which time gait and station were less good than on admission, and a tendency to vertigo was marked.

**Subsequent notes.**—*Oct. 29, 1916.* By letter. Following a severe attack of grippe in January with good recovery, there has been a progressive gain in all respects. No further dizziness, nausea, headaches or other discomforts. Unexpected improvement in vision with present acuity of 20/40. Unsteadiness of gait apparent only on turning quickly. The deafness persists. Marked gain in weight. *Mar. 14, 1917.* Continued improvement. Able to do her own housework, and can walk long distances without tiring.

**Pathological note.**—As in Case XX, the fragment of tumor was originally diagnosed as a "glioma" and later this was changed to "endothelioma." Recent study shows that the tissue, though it might possibly be mistaken for a glioma, nevertheless is a typical acoustic tumor with characteristic interlacing and somewhat hydropic fibrous bands (Fig. 110) which in this fragment show no definite whorls or palisade dispositions of the nuclei.

There are hyaline zones about the vessels, and in the reticular areas resembling glioma no definite fibrils are seen. A striking feature of the tissue (Figs. 109 and 111) lies in the unusual number of fat cells, many of which are phagocytic.

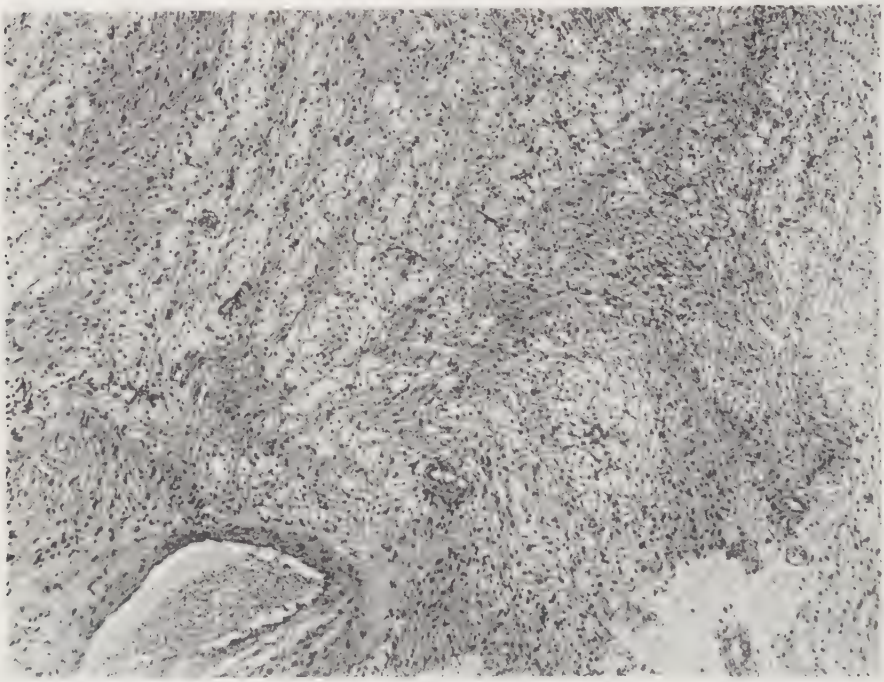

Fig. 109.—Case XXI. Low power magnification (× 80), showing marked fatty transformation of fibrous areas (hæmatoxylin eosin).

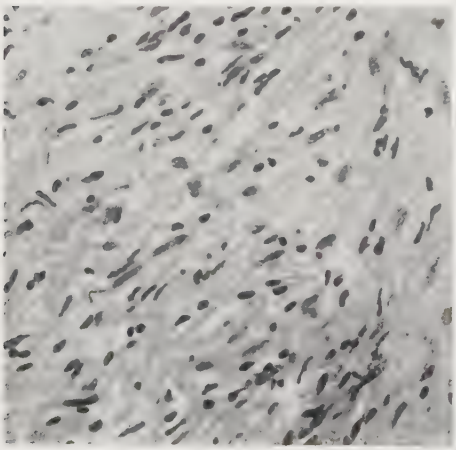

Fig. 110

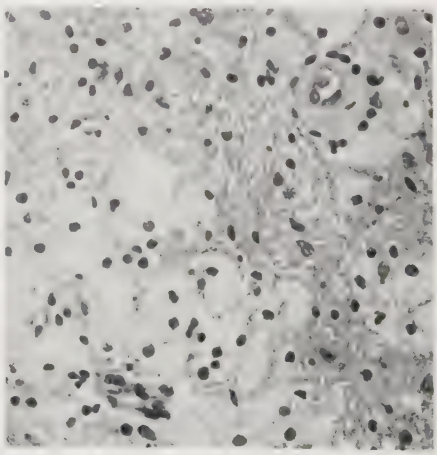

Fig. 111

Figs. 110, 111.—Case XXI. Showing (× 300) hydropic fibrous area and area of fatty infiltration with small hyalinized blood vessel.

**Comment.**—In this case the cerebellar symptoms which had been very inconspicuous were temporarily accentuated by the operation, due unquestionably to the backward dislocation of the hemisphere, through the decompression opening. This is a common sequel of suboccipital decompressions in the presence of tension, but after all, it is a small payment in view of the marked pressure relief, and attention may be called to the subsequent great improvement in this patient's condition.

It is quite probable that a more extensive enucleation would have given still better results, but the fatality in Case XIX had led to a period of renewed conservatism.

---

In the succeeding case a return to a more radical procedure in dealing with the tumor was again instituted, with favorable results. The history is unique in the series in view of the complete post-operative restoration of hearing as well as in the occurrence of the facial spasms, from which aspect the case has been made the subject of a separate report.[46]

The story, furthermore, is of paramount interest for the reason that the tumor was, like others in the series, primarily diagnosed a glioma, and in view of the fact that hearing was completely restored this diagnosis was not questioned, and only by chance was the case finally identified as a primary acoustic tumor rather than as a glioma of the recess with secondary acoustic involvement.

## Case XXII

P.B.B.H. Surg. No. 4139. **A left acoustic tumor resembling glioma. Unusual chronology and character of symptoms with primary facial spasms. Operation. Intracapsular extirpation. Recovery with restoration of hearing.**

*Jan. 17, 1916.* Admission of John C., age 30, a clerk, referred by Dr. Benjamin Fagnant of Springfield, Mass., with the diagnosis of brain tumor.

**Chronology of symptoms.**—For nine years twitching of the left face, beginning as a left blepharospasm and increasing in intensity until for six months the entire left face has become involved (Fig. 112), the spasm occasionally spreading to the arm and leg (?).

For three years periods of stabbing frontal pain: of late some suboccipital pain and stiffness of the neck, especially in the morning hours.

For one year gastric distress with more or less vomiting, occasionally blood tinged. Also staggering gait, increasing so that for past six months patient has been bedridden.

For six months vertigo and dizziness: photophobia and failing vision: also some slight ''ringing'' tinnitus in left ear accompanied by loss of hearing. Occasional hallucinations of smell (uncinate?). For several months increasing difficulty of swallowing and slurring of speech. Also frequent periods of hiccoughing. Of late any slight change in position precipitates suboccipital pain and is apt to produce vomiting.

Various *diagnoses* of stomach trouble: Jacksonian epilepsy: facial tic: cerebral syphilis etc., had been made.

**Positive neurological findings.**—(A) *General pressure.* Bilateral choked disc: 2–3 D.: acuity 20/100. Frequent epistaxis. X-ray shows dilated venous channels with secondary pressure atrophy of the posterior clinoids (Fig. 113). (For reflexes *cf.* below.)

(B) *Localizing.* Characteristic position of head: suboccipital tenderness and stiffness. (1) *Cerebellar.* Nystagmus, vertical and lateral: coarser to left: conjugate deviation well

sustained. Station and gait impossible to test owing to patient's condition. Marked ataxia of left arm and leg.

(2) *Extracerebellar. Cerebral nerves.* $V^{th}$ = Slight subjective left hypæsthesia: rela-

Fig. 112.—Case XXII. Photograph taken during facial spasm.

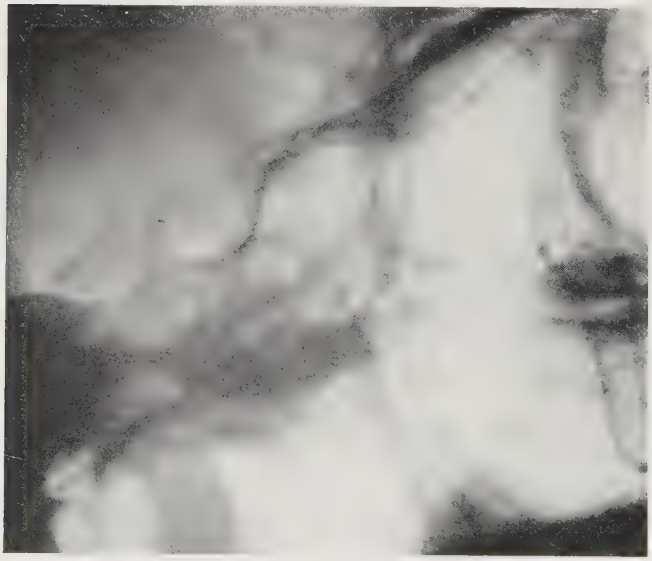

Fig. 113.—Case XXII. Showing absorption and forward tilting of the dorsum sellæ characteristic of a recess tumor.

tive left corneal insensitivity. Slight deviation of jaw to left. VI$^{th}$ = Negative: past history of occasional diplopia. VII$^{th}$ = Convulsive spasms on left: no weakness, though expressional movements possibly impaired in lower face. Lowered taste discrimination on left.

VIII$^{th}$ = Left tinnitus with following deafness, now complete as confirmed during caloric tests, though difficult to exclude the possibility of some retained bone conduction (possibly transferred). Practically no labyrinthine responses left: normal right. X-ray of porus shows no enlargement.

IX$^{th}$, X$^{th}$, XI$^{th}$ and XII$^{th}$ = Marked dysphagia and dysarthria with suggestive cerebellar attacks.

(3) *Medullary* (?). Slight hypæsthesia of left side of body. Deep reflexes variable, occasionally exaggerated with a possible clonus on the left (variable). Superficial reflexes:

Fig. 114

Fig. 115

FIGS. 114, 115.—Case XXII. After operation. Wound on discharge. Absence of facial weakness.

dorsal flexion of toes (positive Babinski) occasionally noted. Abdominal and cremasteric reflex absent on left.

**Clinical diagnosis.**—"Presumptive left cerebellopontile-angle tumor."

*Jan. 21, 1916.* **Operation.**—Usual bilateral cerebellar exposure. Puncture of ventricle owing to tension. On exploring the left recess the margin of a large arachnoid cyst was exposed. On emptying this, a typical recess tumor was bared, its surface somewhat more vascular than usual and its structure less dense and yellowish than the usual acoustic tumor. A fairly thorough intracapsular extirpation was made, in the process of which a cyst of considerable size was encountered in the substance of the tumor.

**Post-operative notes.**—Immediate great improvement. No post-operative setback. Healing *per primam.* Early subsidence of facial spasms (Figs. 114, 115). Discharged

Fig. 116.—Case XXII. Showing normal left porus internus (*p.a.i.*) Restudy after operation. Note bone defect and clips on dural margins.

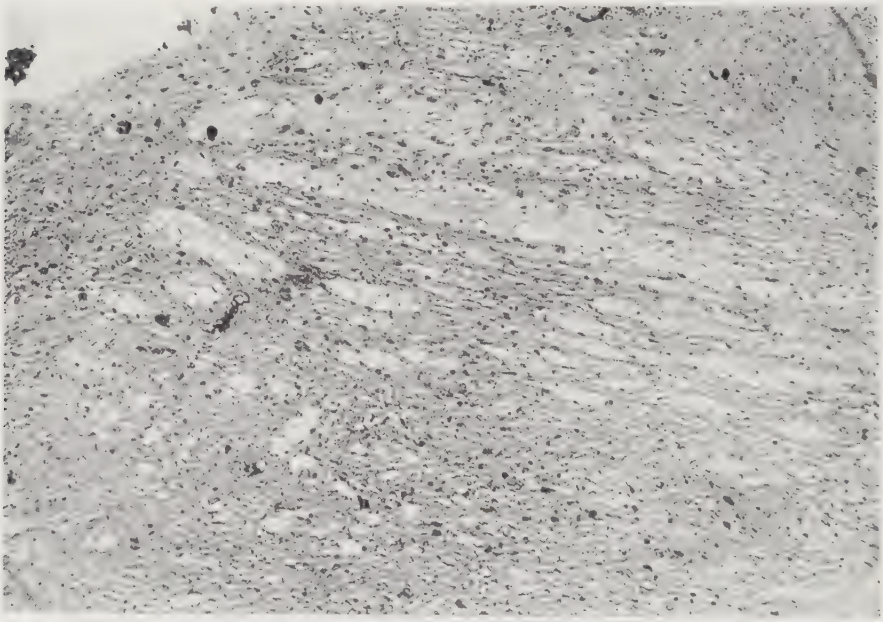

Fig. 117.—Case XXII. Showing (× 80) areas of beginning degeneration with markedly hydropic fibrous bands.

*March 3*, having gained twenty-five pounds: able to walk without aid: choked disc receded. Slight definite return of hearing (air conduction) in the left ear! Slight persisting hypæsthesia and weakness of left side of body.

**Subsequent notes.**—*Aug. 19, 1916.* Re-examination of pori acustici shows equal and normal openings on the two sides (Fig. 116). Patient much improved in all respects and at work. Gait a trifle unsteady when fatigued and on turning. Cessation of facial spasms. Hearing greatly improved.

*Nov. 14, 1916.* Re-examination. Condition perfect. Unsteadiness almost imperceptible. Slight nystagmus. Normal vision. Hearing on left still better: watch 8″ left: 12″ right. Labyrinthine responses practically equal on the two sides.

**Pathological notes.**—The tumor (Fig. 117) contains areas of fibrous tissue but is for the most part made up of a loose reticular tissue of glia-like appearance showing, with phosphotungstic stains, many definite neurofibrils (Fig. 118). The picture resembles closely the usual cerebral glioma, though there are no mitoses. There are many multinuclear cells and cystic spaces. Perivascular hyaline degeneration is marked

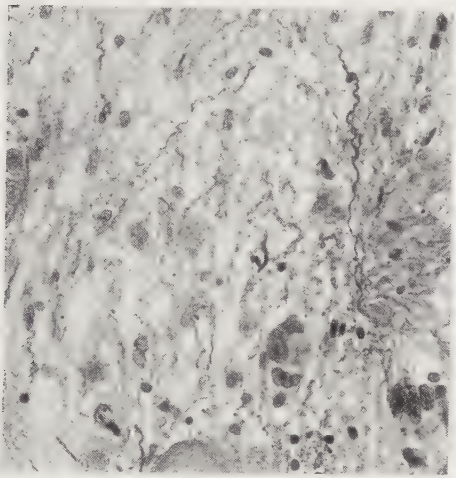

Fig. 118

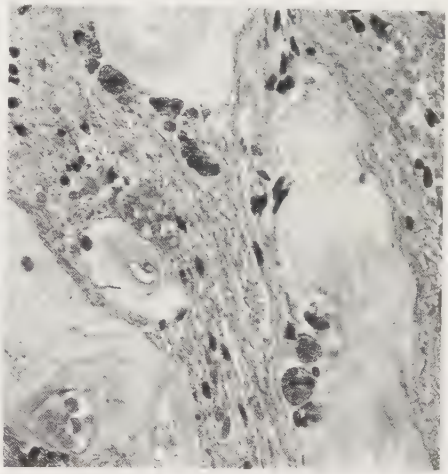

Fig. 119

Figs. 118, 119.—Case XXII. Showing (left) glia fibrils, (right) hyaline zones and pigment deposit in fibrous area.

and there is considerable pigment deposition (Fig. 119). Original diagnosis: "A slow-growing glioma" or "fibroglioma."

A re-examination of the sections shows a sufficient number of characteristic, though hydropic, fibrous bands to justify a diagnosis of an acoustic tumor.

**Comment.**—From the histological notes attached to the three preceding histories it is obvious that we were having difficulties with the pathological diagnoses of these cases and that there was some conflict between what the sections were supposed to show and what clinically it was thought they ought to show. The discussion came to a climax in connection with the tumor of this Case XXII, which offers an even more striking example of the histological pitfalls that may be encountered in the attempt to diagnose an acoustic tumor from a fragment of the growth unless one happens to be familiar with the characteristic features of these peculiar growths.

In the course of preparation for this report the history of this case had been originally included among the varied tumors giving a cerebellopontile-angle syndrome but not of acoustic origin. One reason for this lay in the unusual character of the extracerebellar symptoms with early signs of facial irritation and tardy indications of involvement of the acusticus.

Another reason lay in the fact that at the time of his discharge it was observed that there had been a definite return of hearing in the deaf ear, and though in some other cases in the series (e. g., Cases IV, V, and XX) a slight subjective return of hearing had been recorded in the post-operative notes, these were looked upon as in all probability faulty observations. Here some return of hearing was unquestionable at the time of his discharge, and not only has normal hearing since been regained but normal labyrinthine responses have returned, indicating, as far as can be told, functionally intact nerve fibres which had been "blocked" rather than destroyed. A third reason for regarding the lesion as a true glioma lay in the demonstration of clear-cut glia fibrils—not the pseudo fibrils which had been so frequently seen in other cases, but unmistakable long threads with the characteristic affinity for Mallory's stain.

These unusual clinical and histological features of the case served temporarily to lead to its exclusion from the acusticus group, though it was thought remarkable that a glioma should have given symptoms for so long a period. A re-examination of the tissue, however, in the light of our increased familiarity with lesions originating from the supporting structures of the acusticus leaves no doubt as to its essentially glial character.

It is of course impossible to tell from the anatomical relations of the lesion during an operation from what part of the nerve the tumor has arisen. Indeed this is difficult or impossible in the case of an intact tumor after death unless it happens to be an early and small one disclosed as an accidental finding. So far as I can determine it was Henschen's earlier view that these tumors invariably arose from the distal part of the nerve usually within the internal auditory canal. In his later article,[81] however, two cases are included (No. XXXII and No. XXXIV) which were regarded as having an unusual localization—namely, in the proximal portion of the nerve. In one of them hearing had not been completely lost when examined shortly before death, and in both the disturbances of hearing had been late rather than inaugural symptoms. In neither case was the porus dilated nor did the tumor project into the auditory canal.

The fact that all of the few early tumors which have been encountered have had a distal seat of origin more or less within the porus speaks strongly in favor of this part of the nerve as the more usual starting point for the lesion, but the number is few and there seems to be no definite reason why the growth should not take its start elsewhere. It is probable that an acoustic tumor originating in the proximal and free portion of the nerve would be capable of a much greater enlargement without impairment of function than if the fibres suffered from compression within the bony canal. It is well known that tumors of the peripheral nerves may reach a remarkable size without appreciably interfering with the transmission of nervous impulses and even when impaired, that normal function may be resumed after the enucleation of the growth.

The clinical symptoms, therefore, speak in favor of a proximal origin for the growth in this case, and this is possibly supported by its histological characteristics. Since this will be more fully discussed in a later chapter, it may suffice to say that the supporting tissues for the fibres of the acusticus consist of neuroglia with occasional patches of true ganglion cells and that the nearer the brain the more abundant these tissues appear to be. Hence it is natural to suppose that one of these composite tumors arising from the proximal portion of the nerve will show less of the fibrous and more of the glial elements than do those of more distal origin.

The foregoing interpretation of this unusual case is not entirely satisfying, for it does not account for the facial spasms, which were so pronounced as to lead to a diagnosis of focal epilepsy due to a cerebral tumor. Though twitching of the facial musculature of milder degree is a frequently recorded symptom of acoustic tumors, I know of no reported example of facial spasms of equal intensity and duration. In a case reported by Ziehen[214] there occurred a single attack with cramps in the facial muscles, extending to the arm, which suggested a Jacksonian seizure. Similar seizures also were recorded by Weisenburg[195] in a patient with a supposed cerebellopontile tumor, the nature of which was uncertified, and they were also present in a case reported by Mills.[124]

In the following case, practically the same temporizing procedure was carried out as in Case XXI.

## Case XXIII

P.B.B.H. Surg. No. 4590. **Right acoustic tumor with advanced cerebellopontile-angle syndrome and bilateral nerve involvement. Intracapsular partial enucleation. Recovery.**

*April 17, 1916.* Admission of Mrs. M. L. D., age 41, referred by Dr. W. G. Somerville, of Memphis, Tenn.

**Chronology of symptoms.**—Inaugural symptom about two years ago, with tinnitus in right ear and shortly after, on the left. Soon loss of hearing on the right advancing to deafness, which came abruptly one year ago. For about two years attacks of nausea and vomiting: latterly projectile in character: also unsteadiness in gait, with dragging of right leg: also attacks of vertigo and dizziness, with rotation of objects toward the right. Occasionally falls during attacks. Nystagmus was observed as an early symptom. Periods of stabbing pains in head and neck, with sensation of constriction: worse in the morning: aggravated by stooping: largely referred to the right occipital region and neck.

For one year considerable dysarthria and dysphagia with frequent regurgitation of food through nose. Clumsiness of right hand. Subjective "weakness" of entire right side.

For six months photophobia with lachrymation: also subjective failure of vision which has progressed to blindness in the right eye. Dulling of sense of taste and smell. Numbness and tingling of both sides of face and of mucous membranes: eating difficult from disability in locating food particles with tongue.

For three months diplopia. Twitching of the right face and occasionally of the left. She volunteers that when her head is held tilted to the left it relieves her discomforts. She has been conscious of dreamy states with disagreeable subjective odors suggesting olfactory hallucinations.

**Positive neurological findings.**—(A) *General pressure.* Bilateral choked disc with secondary atrophy: vision greatly reduced. Headaches. X-ray shows greatly enlarged venous channels and secondary pressure absorption of sella turcica (Fig. 120). Relative anosmia.



Fig. 120.—Case XXIII. Secondary pressure absorption with anterior tilting of dorsum sellæ.

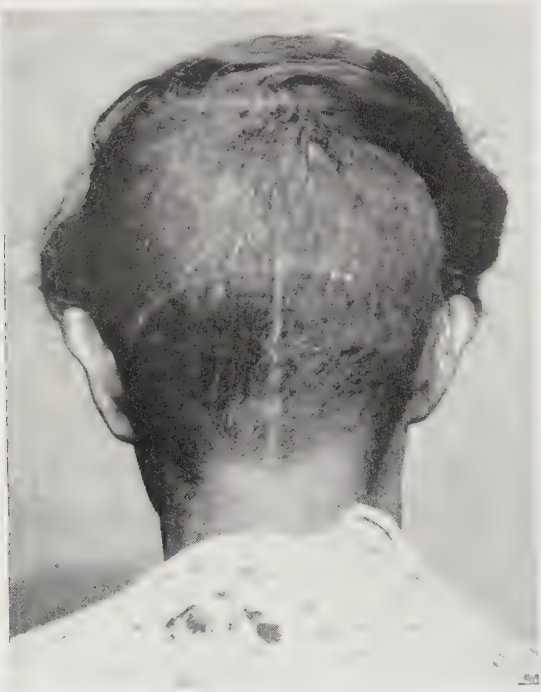

Fig. 121.—Case XXIII. Wound after three weeks.

(B) *Localizing.* Right suboccipital discomfort on flexion of neck. Retraction of neck during severe headaches. Head tilted to left. (1) *Cerebellar.* Nystagmus marked: coarser to right with subjective rotation of objects to right: no restriction of conjugate deviation to either side. Positive Romberg. Ataxic gait with deviation to right as a rule; turning difficult but able to walk alone. Definite ataxia of right arm with dysmetria and general clumsiness. Coarse tremor of both hands. Incoördination of right leg and vertebral musculature.

Deep reflexes hyperactive throughout but without clonus.

(2) *Extracerebellar. Cerebral nerves.* $V^{th}$ = Corneal hyporeflexa on right. Bilateral subjective paræsthesias. Sensation diminished both sides of tongue. Taste much impaired. No deviation of jaw. $VI^{th}$ = Slight weakness right abducens: slight diplopia. $VII^{th}$ = Slight expressional weakness of lower right face. Drooping of palate on right.

VIII$^{th}$ = Normal left. Complete deafness right with marked labyrinthine inactivity on caloric tests, though slight pointing deviation still occurs. No X-ray studies of porus.

IX$^{th}$, X$^{th}$, XI$^{th}$ and XII$^{th}$ = Marked dysarthria and dysphagia with regurgitation. Tongue in median line.

(C) *Misleading.* Suggestive uncinate attacks. Unequal pupils: left larger than right. Bilateral hypæsthesia of face and mucous membrane.

**Clinical diagnosis.**—"Right cerebellopontile-angle (acoustic) tumor."

*April 20, 1916.* **Operation.**—Usual bilateral exposure. Marked foraminal pressure cone. Marked dislocation of cerebellum to left. A large tumor exposed in the right recess, without a covering arachnoid cyst. Surface of tumor vascular. A few fragments only were removed by an intracapsular procedure. The operation was left largely as a decompression.

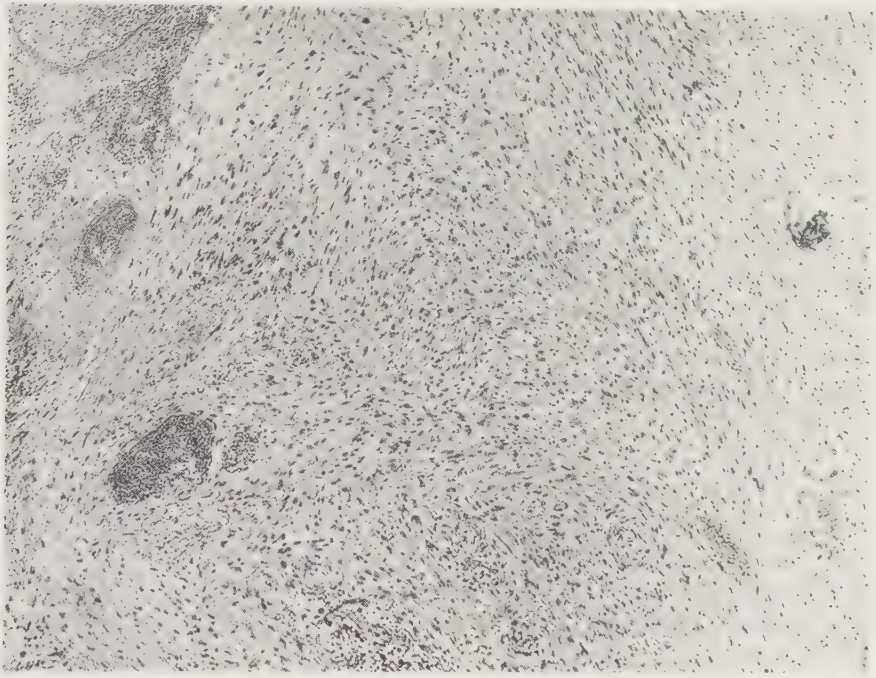

Fig. 122.—Case XXIII. Low power enlargement (× 80), showing main characteristics of tumor (hæmatoxylin eosin).

**Post-operative note.**—An uneventful convalescence. Healing without reaction (Fig. 121). Sitting up at end of week. General improvement in all respects aside from persistence of former neighborhood symptoms. Discharged *May 9, 1916.*

**Subsequent notes** (by letter).—*June 1, 1916.* No further improvement since last note. Some vision retained. *Feb. 1, 1917.* General condition continues excellent: no discomforts: a gain of from 20 to 30 pounds in weight. Unable to walk without assistance. Continued dysarthria.

**Pathological note.**—The fragments of tumor, after sectioning, were diagnosed, without descriptive comment, as "endothelioma."

On re-examination they show (Figs. 122–124) more or less hydropic fibrous bands with indefinite whorls, some palisade arrangement of cells and marked perivascular hyaline

changes. There is reticulated glia-like tissue in small amounts with areas of necrosis, but no fibrils are demonstrable.

**Comment.**—The only chance of diagnostic error in this case lay in the bilateral cerebral nerve symptoms, especially shown by the hypæsthesia of both trigeminal fields. These sensory disturbances were, however, largely subjective and were not accompanied by any demonstrable involvement of the left acusticus, nor was there a left corneal areflexa. Otherwise the condition (as in Case VIII) might have strongly suggested the possibility of a bilateral lesion.

No serious attempt was made to carry out a radical intracapsular enucleation, for the advanced character of the symptoms made even a decompression

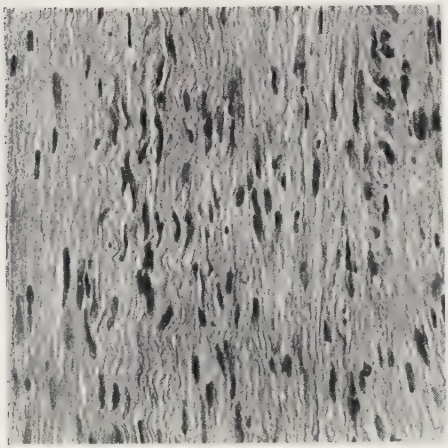

Fig. 123

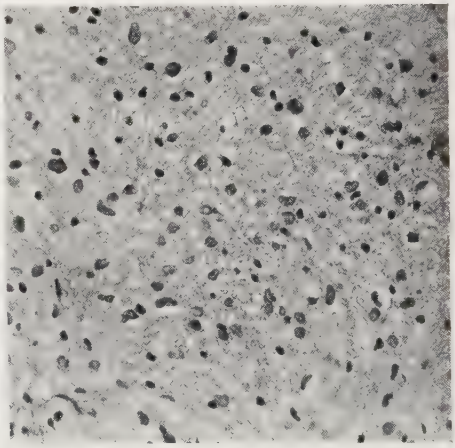

Fig. 124

Figs. 123, 124.—Case XXIII. Showing (× 300) fibrous area with stained fibroglia. On right: reticular area.

precarious and an increase in the deglutitory difficulties was apprehended. Such improvement as occurred was largely confined to the general pressure phenomena, with cessation of headaches, vomiting, and there was ultimately a lessening of the dysarthria and dysphagia. There can be no doubt but that a secondary operation will soon be indicated and it is possible that some more radical measure would have been advisable before her discharge in view of the fact that she did so well at the time, for under existing circumstances the expectation of life, judging from previous experiences, cannot be over a three-year period.

---

The following cases in the series have been observed and operated upon since the studies were undertaken which led to the preparation of this monograph and which largely clarified the confusion under which we had labored in regard to the histological nature of these lesions.

## Case XXIV

P.B.B.H. Surg. No. 5532. **Right acoustic tumor. Subtemporal decompression elsewhere. Typical advanced syndrome. Partial intracapsular enucleation. Recovery. Continued pressure disturbances. Second more radical enucleation. Recovery.**

*Oct. 8, 1916.* Admission of Mrs. P. M., age 44, referred by Dr. P. H. Dernehl of Milwaukee, Wis.

**Chronology of symptoms.**—Two and one-half years ago (1914) noticed when using telephone that she was growing deaf in the right ear. No tinnitus. Prolonged treatment by an aurist with irrigations and electricity. During one of these séances she became completely deaf, her right face contracted and she experienced a numb sensation in the face, which has since persisted. There was also a subjective loss of taste.

Subsequently she began to have vertiginous attacks with sudden dizziness, and would fall if unsupported. At about the same time (*i. e.*, two years ago) she began to have occipitofrontal discomforts, primarily frontal, later suboccipital. The pain would seem to pass from the eyes to the back of the neck, which became somewhat stiff. At about this time her gait became unsteady and she had occasional periods of momentary diplopia.

Various forms of treatment were instituted—frequent change of glasses: inflation of middle ear: and finally, in November of 1915, a thyroidectomy for a small goitre, long present, was performed.

Six months ago, beginning failure of vision with nausea and vomiting. A choked disc was recognized and a right subtemporal decompression was performed, followed by subjective improvement, but the choked discs did not subside and a marked herniation developed. Some subjective loss of hearing in left ear, but no other contralateral symptoms.



Fig. 125.—Case XXIV. Showing marked subtemporal protrusion following decompression.

**Positive neurological findings.**—(A) *General pressure.* A large, tense, subtemporal protrusion (Fig. 125). Bilateral choked disc of 4 D., subsiding with atrophy. Vision reduced to large print. No headaches at present: no anosmia. Cerebration somewhat slow. X-ray shows marked pressure atrophy of the posterior clinoids (Fig. 126).

(B) *Localizing.* Head held tilted to right: marked suboccipital tenderness to pressure: flexion increases discomfort. (1) *Cerebellar.* Nystagmus: coarser to right than left: rotary on looking up. Conjugate deviation well sustained. Positive Romberg with falling

Fig. 126.—Case XXIV. Showing pressure absorption of posterior clinoids.

backward. Gait lurching; broad base; unable to walk unassisted. Incoördination, with tremor, ataxia, and dysmetria of arms and legs: no disparity on the two sides.

Deep reflexes equal and active in normal limits.

(2) *Extracerebellar. Cerebral nerves.* $V^{th}$ = Slight hypæsthesia of right face and mucous membranes, with corneal areflexa. Impaired taste right side of tongue anteriorly. No deviation of jaw. $VI^{th}$ = History of diplopia. $VII^{th}$ = Negative.

$VIII^{th}$ = Absolute deafness right: impaired hearing left: no tinnitus. Completeness of right deafness questionable on subsequent caloric tests. No labyrinthine responses on right. Porus acusticus internus shows no enlargement right or left.

$IX^{th}$, $X^{th}$, $XI^{th}$ and $XII^{th}$ = Some characteristic slurring of speech. No dysphagia. Tongue median line.

*Oct. 13, 1916.* **Operation.**—Usual exposure, the bony opening carried as far to right as possible. Bone thick and dura adherent.



Fig. 127.—Case XXIV. Wound three weeks after operation.

A thick-walled multilocular arachnoid cistern exposed in right recess. An underlying tumor; over its surface were large vessels. Partial intracapsular enucleation. Usual closure in layers.

**Post-operative notes.**—Considerable nausea: otherwise a satisfactory convalescence. Dressing on tenth day. Usual perfect healing (Fig. 127). Subjective improvement in hearing (not corroborated). Subtemporal decompression less tense. Discharged *Nov. 3, 1916.*

**Pathological note.**—Histologically (Figs. 128–130) there are many large interlacing fibrous bands with elongated nuclei showing a disposition to palisade and whorl formation, very closely placed like sarcoma in certain fields. Also large reticular areas with a hydropic appearance and small sparse round cells. Vessels show very little tendency to hyaline change. No fat cells observed.

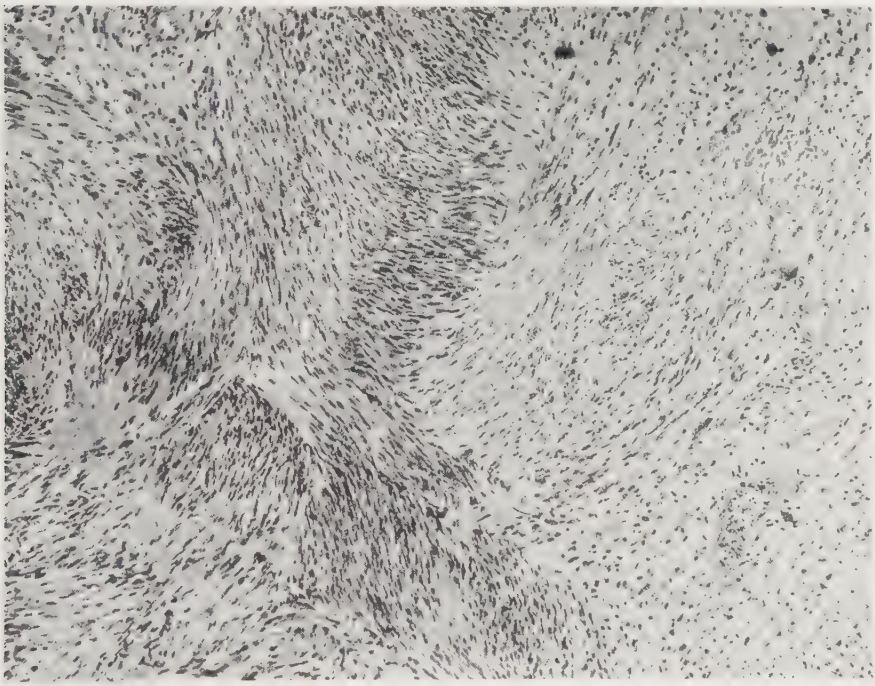

Fig. 128.—Case XXIV. Showing characteristic architecture of tumor (van Gieson stain: × 80).

**Comment.**—The most notable feature of this patient's case lay in the fact that there had been some marked difficulty of cerebrospinal-fluid circulation, for although she improved considerably, there was still marked tension in the area of the subtemporal decompression. It is quite probable that some further operative procedure may be indicated.

(Dr. Cushing did not find time to complete the history of this case. The patient re-entered the hospital on *Jan. 8, 1917,* the suboccipital and subtemporal areas both very tense, and her pressure symptoms still in evidence. A second suboccipital operation was performed on *Jan. 15, 1917,* a very much more thorough intracapsular enucleation being made than on the first occasion. It was hoped that this might serve to permit the obstructed

hydrocephalus to empty itself, but it was evidently unavailing, and her symptoms continued about as before, with the subtemporal protrusion tense.

Consequently on *Mar. 19, 1917,* Dr. Cushing performed a sinoventricular drainage operation with a permanent placement of a silver tube leading from the third ventricle to the longitudinal sinus, according to his new method of draining an obstructed hydro-

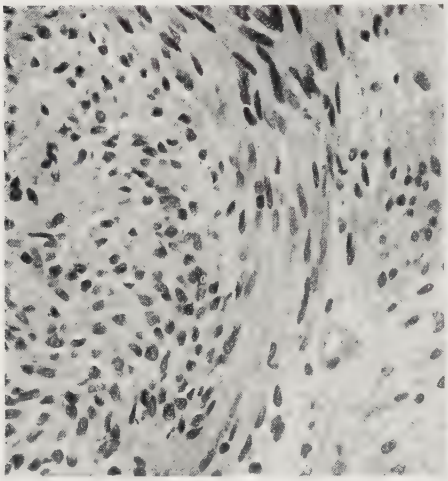

Fig. 129

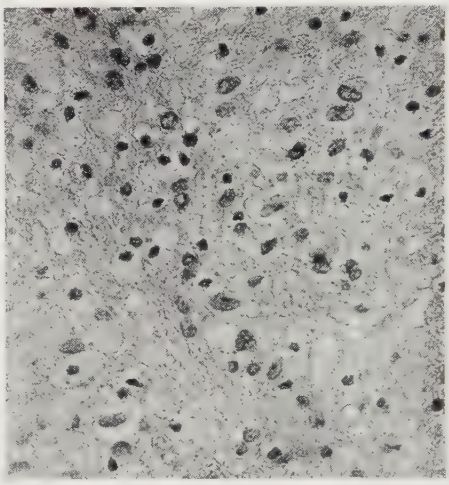

Fig. 130

Figs. 129, 130.—Case XXIV. Margin of fibrous area. On right: reticular area (eosin methylene-blue: × 300).

cephalus. She did very well after this operation, the pressure symptoms were all greatly relieved, and at the time of her discharge, on *April 11, 1917,* she was up and walking with assistance. Subsequent reports relate that she has since shown steady improvement.—L. E.)

The chronology of symptoms in the following case, as elicited from the patient, was less characteristic than usual of a primary involvement of the acusticus, but in all probability the loss of hearing on the right passed unnoticed. The fact that a lowering of vision was one of the early symptoms shows that the process must have long antedated the first recorded symptoms.

## Case XXV

P.B.B.H. Surg. No. 5664. **Left acoustic tumor with recent advanced pressure symptoms and an undeveloped recess syndrome. Thorough intracapsular enucleation. Recovery.**

*Nov. 1, 1916.* Admission of Miss Dorothy D., age 21, referred by Dr. A. B. Twitchell of Newark, N. J., with the diagnosis of a cerebellar tumor.

**Chronology of symptoms.**—For some years a tendency to sick headaches with epistaxis. Onset of pressure symptoms six months ago, with dizziness, and blurring of vision. For three months loss of hearing, first observed on left side owing to difficulty of using the telephone. Does not know when loss began on the

right. At about the same time severe periodic suboccipital headaches associated with nausea and vomiting and noises in the ears like "the puffing of an engine." Also rapid lowering of vision and periods of diplopia. For three months also a staggering gait with tendency to fall backward. Of late some tendency to exophthalmos.

**Positive neurological findings.**—(A) *General pressure.* Bilateral choked disc of 5 D., more advanced on the left, with secondary atrophy and marked constriction of the fields: V. O. S. 20/200; V. O. D. 20/40. X-ray shows dilatation of diploëtic sinuses and some enlargement of the sella with pressure absorption and haziness of the posterior clinoids (Fig. 131).

(B) *Localizing.* Suboccipital headaches: no tenderness: median position of head. (1) *Cerebellar.* Nystagmus marked: slower to the left: slight rotary nystagmus on looking upward. Station poor: unable to stand on left foot. Romberg markedly positive. Gait

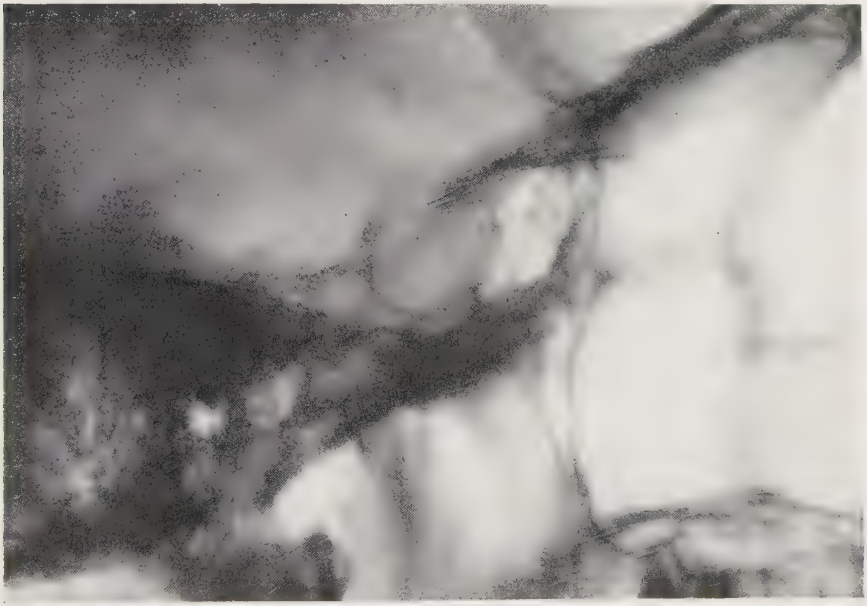

Fig. 131.—Case XXV. Showing enlargement of the sella with haziness of dorsum.

staggering with wide base. Subjective sense of awkwardness of left arm and leg, but tests for ataxia fairly well performed. Considerable fine tremor. Deep reflexes lively, slightly more on right.

(2) *Extracerebellar. Cerebral nerves.* $V^{th}$, $VI^{th}$, $VII^{th}$, $IX^{th}$, $X^{th}$ and $XI^{th}$ = Negative except for slight left corneal hyporeflexa.

$VIII^{th}$ = Subjective "puffing noises"; not localized. Almost complete loss of hearing on right, though low tones of fork perceived. Lowered air perception also on left. Patient too ill for caloric tests. The X-ray studies ot the pori inconclusive (*cf.* post-operative studies which showed (Figs. 132, 133) what was interpreted as an enlargement of the left internal meatus).

**Clinical diagnosis.**—"Right cerebellar tumor, possibly an acoustic growth."

*Nov. 6, 1916.* **Operation.**—Usual procedure with wide dural exposure carried as far as possible to the right. The occipital bone, especially over the right side, much thinned.

Dura extremely tense and as no fluid was secured and the hemisphere tended to prolapse, an immediate ventricular puncture was performed, with evacuation of much fluid. Dura widely opened, disclosing marked pressure cone. Exploration high in the left recess disclosed a bulging arachnoid containing

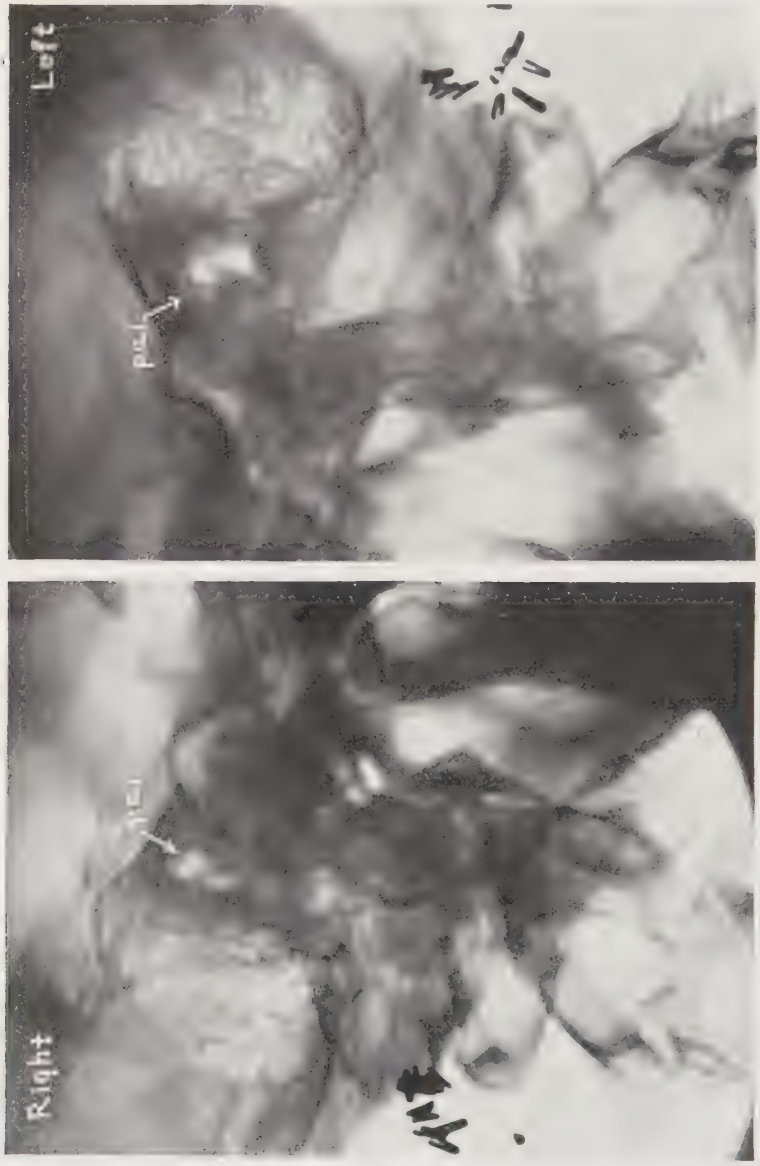


Fig. 133

Fig. 132

Figs. 132, 133.—Case XXV. Right post-operative exposures showing presumed pressure enlargement of porus on left. Plates taken with canals practically superimposed and contralateral mastoid thrown downward (p. [illegible] porus acusticus internus).

fluid, overlying an unmistakable acoustic tumor. The capsule was split and an extensive intracapsular enucleation was made of the soft contents. Usual closure in layers. A prolonged operation of nearly four hours with rise in pulse and fall in pressures (*cf.* Chart 1).

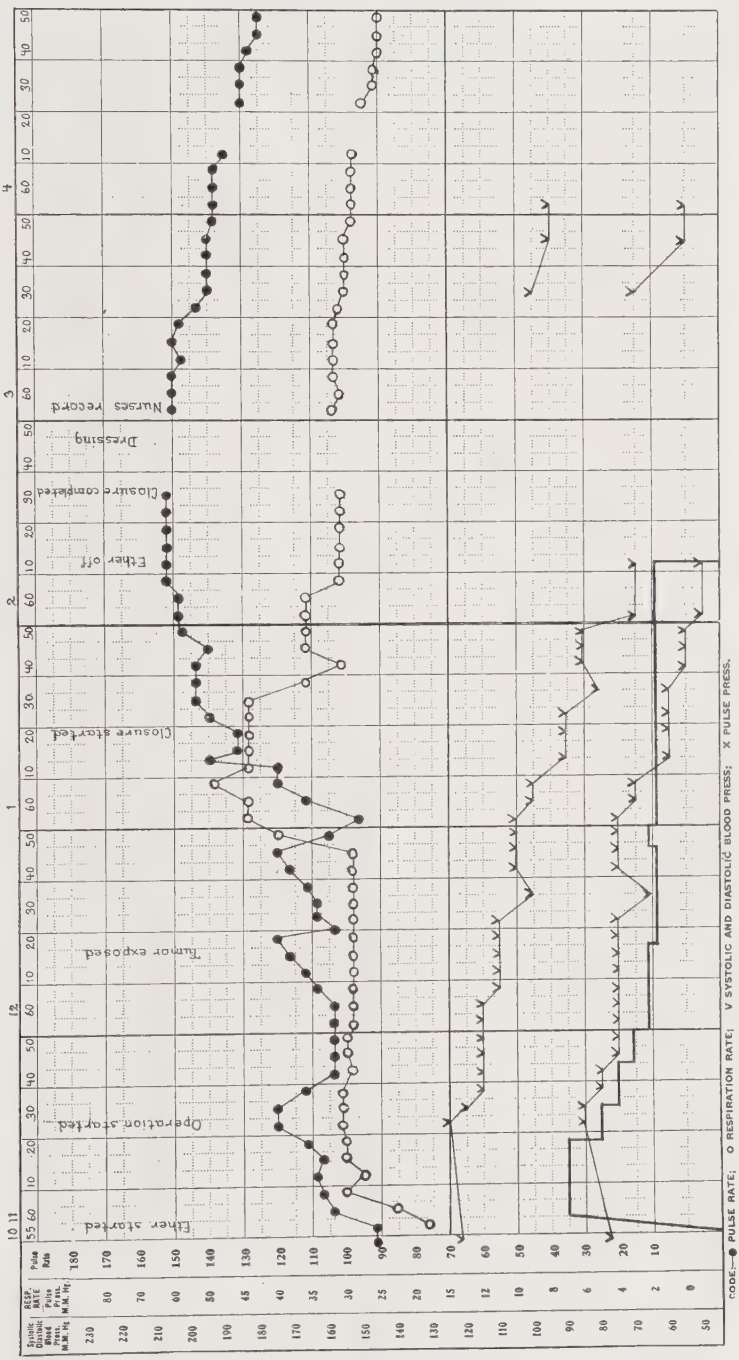


Anaesthetist's chart (Case XXV) showing unusual rise in pulse-rate during period of tumor manipulations and corresponding fall in pressures, though no shock. Prompt recovery after completion of operation.

**Post-operative notes.**—Uncomplicated convalescence. Dressing on the tenth day: perfect healing (Fig. 134). Marked improvement in all respects. Rapid subsidence of choked discs, with unexpected increase in visual acuity. She was discharged *Nov. 28, 1916*, walking well without assistance: a marked improvement in hearing.

**Pathological report.**—The fragments of the tumor are chiefly composed of fibrous bands with whorls and palisade arrangements of the nuclei (Fig. 135). From many of these fields the tumor might well have been regarded as a fibrosarcoma, for the cells are numerous and of various shapes and sizes, and occasionally a mitotic figure is seen (Fig. 200). There are many extensively degenerated and hydropic areas and the walls of the vessels are extensively hyalinized. There are also fields of loose reticular tissue in which imperfectly staining pseudoglia fibrils are seen.

Fig. 134.—Case XXV. Condition of wound on patient's discharge three weeks after operation.

**Subsequent notes.**—*April 2, 1917.* Report by letter that she is free from symptoms except for continued tinnitus in the left ear. There is a definite increase in hearing on the left. Gait practically normal. V. O. D. 18/15: V. O. S. 18/100.

**Comment.**—It is difficult to believe that this clinical history could have been mistaken for any other than that of an acoustic tumor, but in reality the general pressure symptoms so far overshadowed the syndrome of the cerebellopontile angle that an intracerebellar tumor with secondary recess involvement was the favored diagnosis. The right cerebellar symptoms were well advanced, whereas of the nerves, the VIII$^{th}$ only was affected and incompletely so.

The operation was relatively simple and uncomplicated—indeed, one of the best immediate results in the series. It is possible that a complete enucleation might have been attempted, as the exposure was good, though an arterial branch coursed over the surface and would have given difficulty. The tumor was a fairly large one with an estimated diameter of 2.5 cm.

The patient was used as a subject for the photographic illustrations in the operative section (Figs. 241, 242, 259–262).

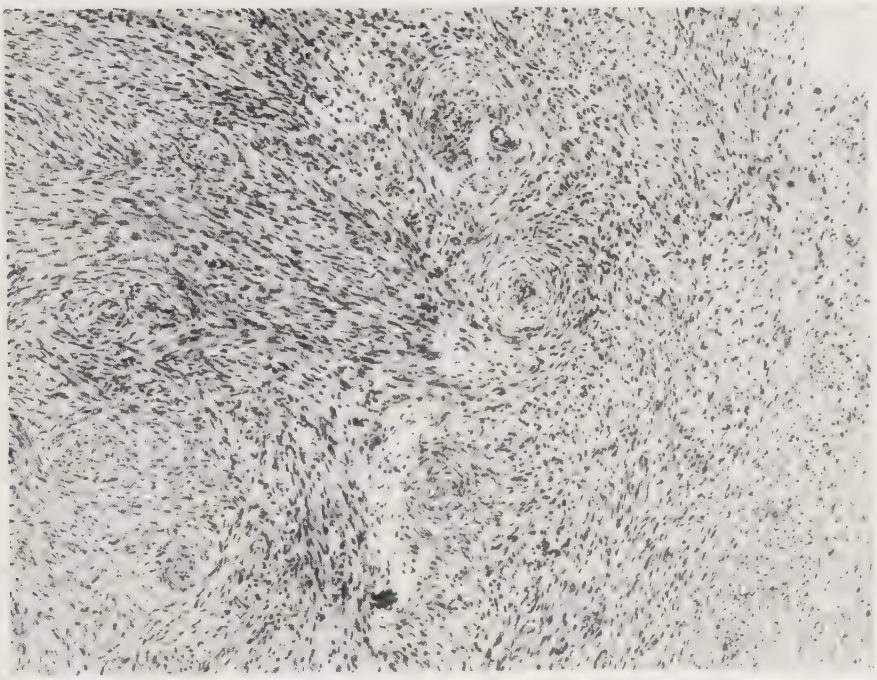

FIG. 135.—Case XXV. Showing (× 80) fibrous area with characteristic nuclear arrangements (phosphotungstic acid hæmatin).

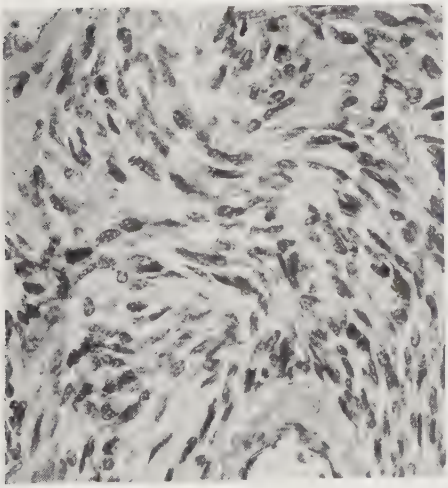

Fig. 136

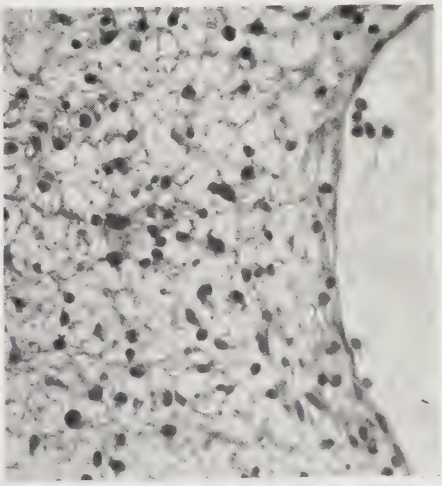

Fig. 137

FIGS. 136, 137.—Case XXV. Fields of fibrous and reticular tissue (× 300: phosphotungstic acid hæmatin).

The symptoms in the following case, as in Case XXII, began with facial twitching, though it is quite probable that an antecedent auditory impairment had escaped the patient's notice.

## Case XXVI

P.B.B.H. Surg. No. 5712. **Early tumor (glioma) of left acusticus, not involving the porus; producing characteristic recess symptoms. Operation. Partial enucleation. Recovery.**

*Nov. 9, 1916.* Admission of Mrs. Rebecca D., age 29, referred by Dr. P. V. Brunick of Boston, Mass., with the diagnosis of tumor.

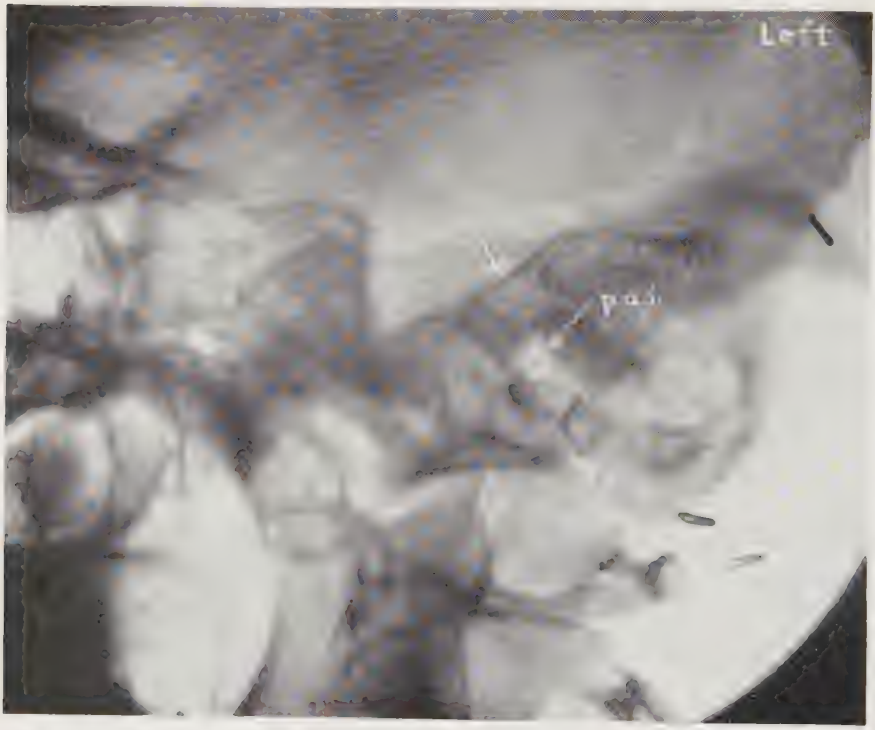


Fig. 138.—Case XXVI. A poorly disposed plate with superimposed mastoids. It nevertheless shows a normal left internal meatus (*p.a.i.*).

**Chronology of symptoms.**—History of an occipital trauma from fall on ice seven years ago. Onset two years ago with left blepharospasm, and on waking one morning she found the face drawn to the left (no history of facial paralysis obtained, though from present appearance suggesting contracture it seems to have been paralyzed at one time). Coincident with this there was a period of numbness of the face for a few weeks.

One year ago, while out walking, sudden loss of hearing in left ear. Thought she had taken cold. Hearing not regained. Never any tinnitus, though for a few days there has been what she calls a "pounding" in the left ear.

For six months indistinctness of vision with diplopia on looking to the left.

For three months severe suboccipital discomforts radiating to the

front: sudden in onset. Also staggering gait, dizziness, a sensation of up-and-down movements of objects, a subjective weakness of the right hand and leg with a tendency to drop objects, marked drowsiness.

**Positive neurological findings.**—(A) *General pressure.* Early choked disc of 2 D.: vision normal. X-ray shows a slight enlargement of venous channels and pressure absorption of posterior clinoids (Fig. 138).

(B) *Localizing.* Left suboccipital discomforts: tends to tilt head to left. (1) *Cerebellar.* A few poorly sustained slow nystagmoid twitches to right and left. Slight rotary nystagmus on looking up. Romberg positive. Gait staggering, wide base, tends subjectively to deviate to the left, but not objectively apparent. Considerable tremor, awkwardness and dysmetria of hands and feet in usual tests for incoördination.

Deep reflexes lively to exaggeration on the right, where there is occasional well-sustained ankle clonus, but normal plantar responses.

(2) *Extracerebellar. Cerebral nerves.* $V^{th}$ = Slight corneal hyporeflexa left. Common sensation over face appears normal. $VI^{th}$ = Complete left external rectus palsy. $VII^{th}$ = Marked asymmetry of the face, which is drawn to the left as though by a post-paralytic contraction. Occasional muscular twitching. She states that her face has been drawn to the left since childhood. Patient's impression has been that there was a right facial weakness. Slight lowering of taste perception on left.

$VIII^{th}$ = Complete paralysis of cochlear and vestibular branches on left. No sound transmission. No responses to caloric or rotary tests. Porus acusticus shows no radiographic change (Fig. 138).

$IX^{th}$, $X^{th}$, $XI^{th}$, $XII^{th}$ = Normal. No dysphagia or dysarthria. No deflection of tongue.

**Clinical diagnosis.**—Left acoustic tumor.

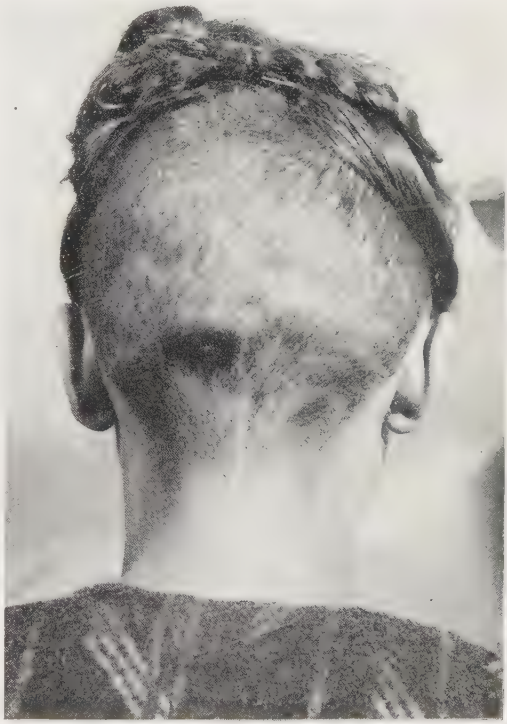

Fig. 139.—Case XXVI. Three weeks after operation.

*Nov. 23, 1916.* **Operation.**—The usual bilateral approach, carried well into the mastoid on the left. No thinning of bone. Emissaries large. Tension of dura not great and membrane opened without marked protrusion of hemispheres. An abundance of fluid from the posterior cistern: no pressure cone. Investigation of left recess caused respiratory embarrassment so that an attempt, which was unsuccessful, was made to puncture the ventricle.

Recess finally exposed with no sign of tumor until the $VIII^{th}$ nerve was exposed, entering the porus. The nerve was of a yellowish-red color, swollen to several times its normal size, evidently containing a tumor, and a single small strand of normal-appearing fibres coursed over its surface. Further investigation showed that this was merely the neck of a pear-shaped tumor which extended into a depression in the cerebellum. The growth was incised and a portion of it removed for histological study. Closure.

**Post-operative note.**—Uneventful recovery. Marked improvement in all respects.

Fig. 140.—Case XXVI. Showing (× 80) the general characteristics of the tumor—a definite glioma (eosin methylene-blue).

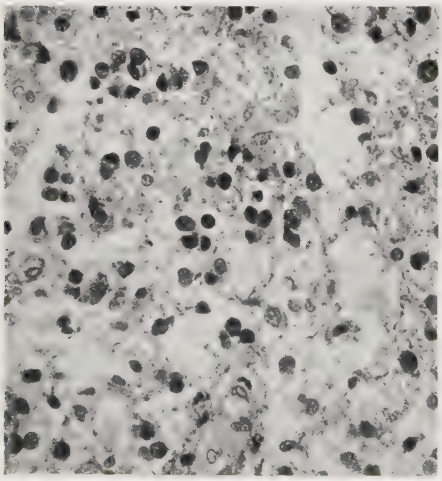

Fig. 141

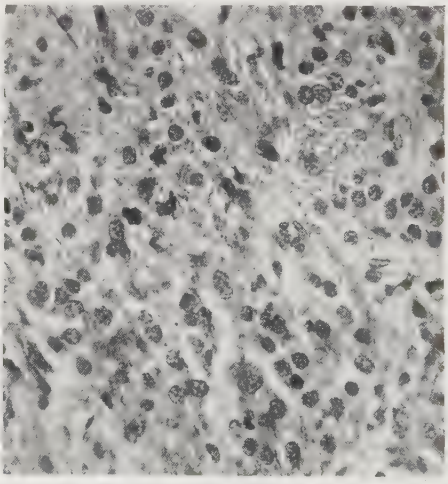

Fig. 142

Figs. 141, 142.—Case XXVI. Showing (×300) the general architecture of the tumor, resembling the reticular areas of the others in the series. On the right the more cellular margin.

Healing *per primam* (Fig. 139). Subsidence of choked disc and of all discomforts. Facial contractions and abducens weakness subsided. Marked improvement in gait, though considerable incoördination of left arm and leg persists. Subjective return of some hearing on left, both to voice and fork, but vestibular reactions to rotation and caloric tests remain absent. Discharged *Dec. 23, 1916.*

**Pathological note.**—The tumor (Fig. 140) is an undoubted glioma (*cf.* Case XXII). The entire basic substance is reticular, containing definite neurogliar fibrillæ. The predominant nucleus is small and round with no circumscribed cytoplasm (Fig. 141). There are many large stellate cells with eccentric nuclei and radial projections whose cytoplasm seems to terminate in coarse wavy neurogliar fibrillæ. No suggestion of fibrous tissue. The outer margin of the tumor is very cellular (Fig. 142), the nuclei being larger than those of the remainder of the tumor, with no very distinct nucleolus and usually surrounded by homogeneous cytoplasm, often having stellate arrangements. Many cells resemble ganglion cells. Extending down from this zone toward the center of the tumor are dense masses of neurogliar fibrillæ pointing concentrically toward the center, forming a definite zone. The tumor is vascular with a capillary network. Diagnosis: "*Glioma.*"

**Comment.**—The case bears considerable resemblance to Case XXII, not only in the early facial irritation, in the considerable return of hearing after the operation, but also in the unusual histology of the tumor and the fact that it appeared to have arisen from the free or central portion of the nerve rather than from the terminal portion in the bone.

Of all cases in the series this probably would have been the most favorable for an attempt at a complete enucleation. The stalk of the growth projecting up to the undilated porus could have been divided, with sacrifice of the facial, and it is quite possible, with this as a handle, that the remainder of the growth could have been easily withdrawn. The temptation will be strong to attempt such a procedure should equally favorable conditions present themselves in the future.

In the following case the symptoms were of rapid onset and the condition unhappily had been allowed to run on to blindness owing to a period of futile antiluetic treatment on the basis of a supposed positive Wassermann reaction. Subsequently, when this was disproved, the condition of her eyes was attributed to a toxemic (lead) papillitis. The cerebellar symptoms were peculiarly inconspicuous.

## Case XXVII

P.B.B.H. Surg. No. 5921. **Left acoustic tumor with advanced pressure and cerebral nerve symptoms. Cerebellar manifestations slight. Extensive intracapsular enucleation. Recovery.**

*Dec. 19, 1916.* Admission of Mrs. T. R., age 39, referred by Dr. George S. Derby of Boston, Mass., with the diagnosis of tumor.

**Chronology of symptoms.**—Onset a year ago with a feeling of drowsiness and morning nausea. This was followed shortly by noises in her head, chiefly in the left ear, but they were at times so loud that she could not tell whether they were "inside or outside of her head." She is quite sure the tinnitus was not the initial symptom. It has persisted to the present time but has become less severe: described as the "purring of an engine." At about the same time there were periods of extreme intracranial discomfort described as a "bursting sensation." These would begin in the occipital region and spread forward. They have been less severe for past few months.

Eight months ago there was a period of stiffness and paræsthesia of the left face: this has largely subsided. Soon after diplopia was observed, which continued until vision was lost.

Six months ago she first noticed deafness, which she thought was complete, in the left ear.

Four months ago she began to suffer from stiffness of the neck, and about this time an optician was consulted owing to lowering of vision. Six weeks ago there was a rapid change for the worse, and for three weeks she has been practically blind.

Of late she has had a "lifeless" feeling in the left arm and hand. There have been occasional attacks of vomiting, but no vertigo, dizziness or staggering.

*Status præsens.* The patient is an alert, well-developed and nourished woman with no

Fig. 143.—Case XXVII. Print from a poorly disposed post-operative radiogram of the left mastoid, showing what was taken to be an absorption of the internal porus.

special complaint aside from her blindness. She shows no mental changes; walks with no unsteadiness other than the uncertainty attributable to her blindness.

**Positive neurological findings.**—(A) *General pressure.* Choked disc of 6 D. with pallor of secondary atrophy: pupils dilated: vision reduced to perception of shadows. X-ray shows enlargement of venous channels and pressure absorption of the dorsum sellæ.

(B) *Localizing.* Left suboccipital discomforts accentuated on flexion of neck. (1) *Cerebellar.* A few poorly sustained nystagmoid jerks on looking to the left. The Romberg test shows slight unsteadiness. Slight dysmetria of left arm and leg (so slight as to have easily escaped detection). No disturbance of gait appreciable. No adiadococinesia, ataxia or tremor.

Deep reflexes normal and equal.

(2) *Extracerebellar. Cerebral nerves.* $V^{th}$ = Subjective paræsthesias. Slight hypæs-

thesia over cheek. Jaw deflects slightly to the left. Left hyporeflexa cornealis. VI$^{th}$ = Convergent squint. Weakness of both abducentes, especially right. VII$^{th}$ = Possibly some slight expressional weakness. Subjective as well as objective loss of taste on left.

VIII$^{th}$ = *Cochlear branch.* Tinnitus present in both ears: more marked on left. Complete deafness left: normal right. *Vestibular branch.* Pointing tests normal. No nystagmus or dizziness produced by rotation. No caloric reactions elicited from either ear. X-ray studies of pori unsatisfactory (post-operative plates suggest an enlargement of the left porus internus (Fig. 143)).

IX$^{th}$, X$^{th}$, XI$^{th}$ = Occasional slight difficulty in deglutition. No dysarthria. XII$^{th}$ = Tongue protrudes slightly to the left.

*Medullary.* A numb and lifeless feeling in the left hand and arm.

**Clinical diagnosis.**—"Left cerebellopontile-angle (acoustic) tumor."

Fig. 144

Fig. 145

FIGS. 144, 145.—Case XXVII. Showing wound after three weeks, and absence of protrusion. Note slight tilting of head toward affected side.

*Dec. 26, 1916.* **Operation.**—The usual bilateral exposure, carried well to the left. Considerable foraminal herniation, but sufficient fluid was secured from the posterior cistern to lower tension. The tumor, with no intervening arachnoid accumulation, presented somewhat lower than usual, and the IX$^{th}$, X$^{th}$ and XI$^{th}$ nerves were seen stretched around its lower pole. The growth was bisected and practically all of its contents were scooped out piecemeal from the capsule, which largely collapsed. The slight oozing from the raw surfaces after the removal of the separate fragments was checked by the temporary placement of pledgets of cotton dipped in Zenker's fluid. Closure. A very prolonged operation: four hours from "ether on to ether off." Condition excellent throughout (*cf.* Chart 2).

CHART 2

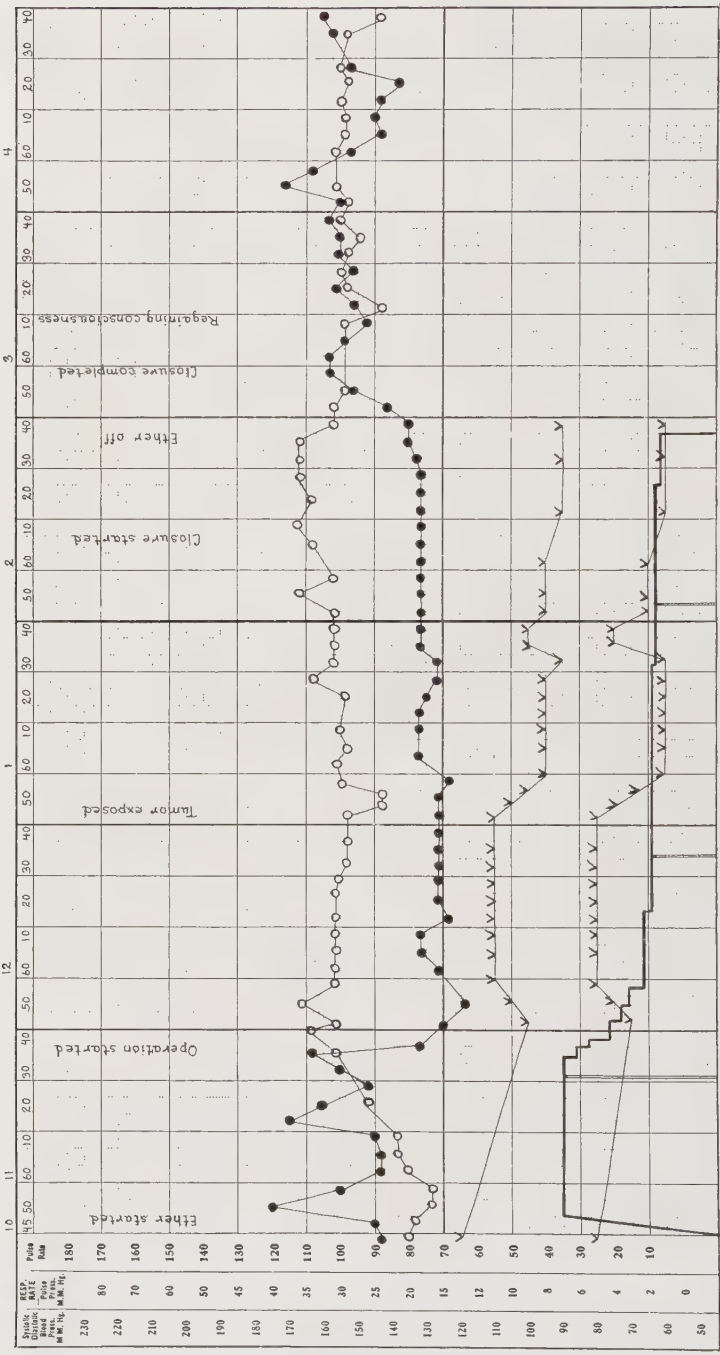


Chart (Case XXVII) showing respiration and pulse rates, systolic and diastolic pressures, and ether tension. Note very slight reaction despite prolonged operation.

**Post-operative notes.**—The operation was well borne. There were no complications. The convalescence was uneventful and healing was perfect (Figs. 144, 145). The operation accentuated slightly her incoördination, but this, by the time of her discharge, *Jan. 17, 1917*, had largely disappeared. At this time there was no Rombergism nor incoördination. The facial numbness, deflection of the jaw, tinnitus and dysphagia had disappeared. There was complete return to normal of the vestibular reactions (caloric, etc.) on the right: those on the left remained lost, but considerable hearing to loud voice sounds on the left (during right irrigation) was regained. The corneal areflexa persisted and with the subsidence of the choked disc to 4 D. there was practically a complete loss of vision.

**Pathological note.**—The tissue shows (Fig. 146) the usual bands of interlacing fibrous tissue, which are quite œdematous. There are many areas of degeneration with beginning

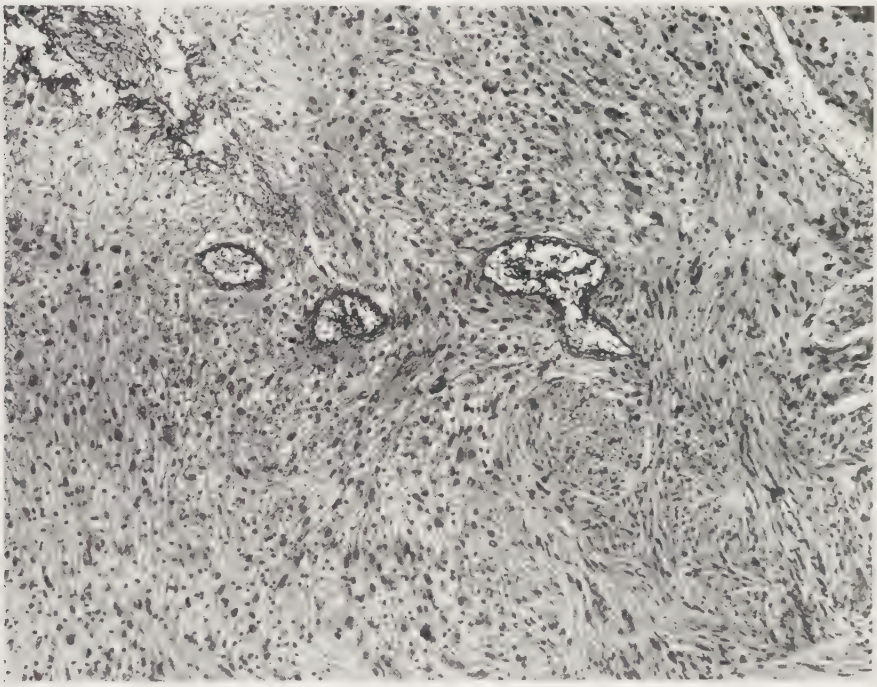

Fig. 146.—Case XXVII. Showing, under low magnification (× 80), the interlacing hydropic bands of fibrous tissue and beginning cyst formation in the upper left corner (eosin methylene-blue).

cyst formation. The characteristic loose reticular tissue resembling glioma occurs in many places. Many of the fibrous-tissue nuclei are large and irregular, probably representing a younger type of cell (Fig. 147). In the reticular areas are pseudo-fibrils resembling glia (Fig. 148).

**Comment.**—This record serves to show how inconspicuous, even with a large tumor, the cerebellar symptoms may be and how much diagnostic reliance one must place on the patient's story and on the cerebral nerve symptoms. The case presented little more than a year's history of left tinnitus and loss of hearing, of left trigeminal paræsthesia, and of loss of vision, due to atrophy secondary to a choked disc. Her choked disc, long regarded as a

toxic (lead) papillitis, was the predominant symptom and there was abundant excuse for the failure, on the part of her earlier attendants who were unfamiliar with these cases, to recognize the presence, seat and nature of the underlying cause.

One thing may deserve special reference—the obscure Bárány tests. It was impossible to evoke nystagmus either by rotation or by caloric tests, and



Fig. 147



Fig. 148

Figs. 147, 148.—Case XXVII. Showing fibrous area with fibroglia fibrils, and reticular field with pseudoglia fibrils (phosphotungstic acid hæmatin: × 300).

no dizziness, vertigo or nausea was produced. Both labyrinths, however, were capable of stimulation by rotation tests, as shown by the characteristic past pointing, but this concerned only the horizontal canals, not the vertical canals. The single observation of value was that the left ear, before the operation, was completely deaf while the right was being irrigated, whereas some hearing was subsequently regained in this ear.

—

The following case is of unusual interest in view of the two preceding explorations, in neither of which the tumor was disclosed though its presence was suspected. The case is therefore comparable to Case XV of the series, though differing from it in the fact that the preliminary decompression was more enduring and effectual, doubtless for the reason that the growth was one of smaller size.

The case, moreover, is a good example of the cases in Table 3 (p. 17) which are listed as "acoustic tumor suspects," for the reason that it was so classified for a period of two years. Our awakened interest in these tumors during the latter months of 1916 led us to reopen correspondence with these suspected cases, and this patient alone of the number was dissatisfied with the

degree of relief which had been afforded, and re-entered the hospital for a further attempt to uncover the tumor.

## Case XXVIII

P.B.B.H. Surg. No. 981. **Left acoustic tumor with typical syndrome. Two previous suboccipital explorations with negative findings. Successful exposure of tumor two years later with radical intracapsular enucleation. Recovery.**

*Mar. 3, 1914.* Admission of Mrs. Florence S., age 30, referred by Dr. George L. Walton of Boston with the diagnosis of a cerebellar tumor.

Her past history is without interest except for a possible otitis media in infancy and for a trauma sustained some years before when she fell on the ice, striking the back of her head. There were no immediate serious after effects.

**Chronology of symptoms.**—For three years she has noticed an increasing defect of hearing on the left (first noticed on using the telephone) accompanied for a year by tinnitus likened to "the distant puffing of a freight train." (This fact was only casually noted in the history at the time and was regarded as of no significance by the patient, who dated the onset of her symptoms to the onset of her discomforts as follows.)

For thirteen months, since *February, 1913,* occipital discomforts more marked on the left side and tending to radiate up over the vault. Usually much more severe in the early morning hours. At the outset these were often accompanied by nausea and vomiting, though these symptoms have largely subsided. Dizziness also has been a marked feature from the onset. She complains of a sensation of pitching forward in descending stairs and of "weak spells" in which it seems as though she were going to faint.

For five months there has been an objective lowering of vision, particularly on the left: no diplopia. Also for five months increasing unsteadiness of gait, though she has managed to get about alone until the present time.

For three months there have been paræsthesias, fluctuating in intensity, over the right trigeminal territory, both of skin and mucous membranes. She has lost 20 pounds in weight.

**Positive neurological findings.**—(A) *General pressure.* Bilateral choked disc of 6 diopters, more advanced on the left with secondary atrophy. Periods of amblyopia. V. O. S. 10/100; V. O. D. 10/20. Headaches and some dispositional change. Considerable exophthalmos with dilatation of extracranial vessels. X-ray shows pressure erosion of the dorsum sellæ (Fig. 149). Deep reflexes exaggerated throughout with suggestive clonus of the left knee and ankle.

(B) *Localizing.* Considerable suboccipital tenderness. (1) *Cerebellar.* Horizontal nystagmus on looking in either direction: excursions coarser to the left. Romberg sign marked: tends to fall to right. Gait variable: occasionally considerable staggering with tendency to deviate to right. Turning to right produces dizziness. Considerable tremor of hands, but no definite incoördination evinced on usual tests. Muscle strength about equal on the two sides. No dystonia or diadococinesia.

(2) *Extracerebellar. Cerebral nerves.* $V^{th}$ = Left corneal areflexa. Subjective contralateral hypæsthesia with numbness and stiffness: objectively normal. Jaw opens in midline. $VI^{th}$ = Negative. $VII^{th}$ = Slight expressional weakness of muscles about mouth on left. Winking reflex less good on the left.

$VIII^{th}$ = Left tinnitus. Relative deafness. Watch O. D. 21 inches: O. S. 2 inches. Forks and whistle better right than left. Drums normal. Caloric tests show inactive labyrinthine responses on the left compared to the right.

$IX^{th}$, $X^{th}$ and $XI^{th}$ = Slight dysphagia observed. $XII^{th}$ = Negative.

*Mar. 12, 1914.* **Operation I.**—The usual suboccipital exploration. Difficulties considerable owing to vascular stasis and to periods of respiratory embar-

rassment with Cheyne Stokes respiration. Considerable bleeding from the large emissary vessels in the bone. After puncture of the lateral ventricle and continual drainage these difficulties were overcome. The bone was greatly thinned and there was a marked foraminal pressure cone.

Exploration in the left recess disclosed what was taken to be a dilated cistern: no underlying tumor was seen. Exploration on the right negative. Closure.

**Post-operative notes.**—The wound healing was perfect: the general pressure symptoms subsided: the right trigeminal paræsthesia and the tinnitus disappeared. She did reasonably well in other respects, though there was some increase in her cerebellar symptoms (nystagmus and incoördination) as well as in her dysarthria and dysphagia. She was discharged *April 6, 1914,* her papillœdema measuring only 1 diopter, and with improvement in vision.

*May 2, 1914. Readmission* in excellent general condition but with the complaint of

Fig. 149.—Case XXVIII. Sella turcica absorption and anterior bowing of posterior clinoid.

persistent dizziness, of increasing unsteadiness, and some continuance of nausea and vomiting. The examination showed a more marked incoördination than before, limited, however, to the lower extremities. Arms normal on all tests. The optic discs showed slight swelling and considerable new tissue, but the acuity had improved—V. O. S. 20/30: V. O. D. 20/50 (?). No further tinnitus, but otherwise auditory symptoms as before. Her dizziness was provoked on looking to the right.

Owing to the certainty that there must be a recess tumor, a further exploration was undertaken as follows.

*May 5, 1915.* **Operation II.**—The original flaps were again reflected and there was an abundant escape of cerebrospinal fluid from the region of the foramen. There were few adhesions except in the region of the recess, and therefore the hemisphere was transected to a depth of from 4 to 5 cm., but no tumor was disclosed nor could one be palpated in the depth of the incision. The usual closure.

**Post-operative notes.**—Her convalescence was uneventful aside from considerable

morning nausea and vomiting. Healing normal. Except for a continuance of her un-

Fig. 151

Fig. 150

FIGS. 150, 151.—Case XXVIII. Print of right and left mastoids, showing enlargement of the left porus acusticus internus, far better shown stereoscopically. Note the situation of the clips on the print of the left porus, placed on the capsule of the tumor during the operation.

steadiness, for subjective improvement was considerable and this was attributed to the evacuation of the fluid. She was discharged *May 23, 1914*.

**Subsequent notes.**—She reported from time to time during the succeeding two years, her chief complaint being her static instability. She gained greatly in weight, remained free from headaches and vomiting, reading vision was retained, but there was a gradual complete loss of hearing in the left ear.

*Jan. 2, 1917. Readmission.* Surg. No. 6003. Although the patient has been free from discomforts and in perfect general health for the past two years, her readmission was solicited in order that a further attempt might be made to possibly expose and remove the lesion, in view of the further experience which we had had with acoustic tumors during the interval.

*Status præsens.* Excellent general condition: a gain of 30 pounds in weight: no headaches: no vomiting. Occasionally some slight nausea. Vision better than at first entry. No dizziness, tinnitus or dysphagia. Chief disability lies in her unsteadiness on her feet:

Fig. 152

Fig. 153

FIGS. 152, 153.—Case XXVIII. Photographs of wound 18 days after the third operation. Note excellent nutritional condition: slight exophthalmos: slight bulging of wound.

she is unable to walk alone without support. Reading vision retained in right eye: V. O. D. 20/70 (uncorrected); V. O. S. 20/200. Left ear remains subjectively deaf.

**Positive neurological findings.**—(A) General pressure. Considerable bulging of the suboccipital region, especially on the left, but the protrusions are quite soft. Dorsum sellæ show marked absorption. Optic discs flat but show considerable pallor. Definite exophthalmos, as before.

Deep reflexes active and equal throughout with tendency to clonus at knee and ankle on the left.

(B) *Localizing.* (1) *Cerebellar.* Slight horizontal nystagmus, equal to right and left: jerks of short amplitude. Marked static disability with Rombergism. Stands unsupported with difficulty. Walks only with support. Considerable ataxia of left arm with dysmetria and diadococinesia.

(2) *Extracerebellar. Cerebral nerves.* $V^{th}$ = Corneal hyporeflexa. $VI^{th}$ = Possible

slight weakness of both abducentes without subjective diplopia. Conjugate deviation to left less well sustained than to right. VII$^{th}$ = Negative.

VIII$^{th}$ = No tinnitus. Complete left deafness to all tests while right ear being douched. No labyrinthine responses on left to spinning or caloric tests: right normal. Single X-ray plates showed no apparent enlargement of the porus but subsequent stereoscopic studies demonstrated that the right porus internus measured 4 mm., the left 7 mm. (Figs. 150, 151).

IX$^{th}$, X$^{th}$, XI$^{th}$ = No dysphagia: that present after her second operation having disappeared. Articulation a little thick. XII$^{th}$ = Negative.

*Jan. 22, 1917.* **Operation III.**—The left half of the old wound was reflected, an immense amount of cerebrospinal fluid being secured from a large endothelial-lined extracerebellar pocket beneath the flap. The exposed cerebellar hemisphere was without tension. It was possible despite the adhesions to get into the recess by extracerebellar manip-

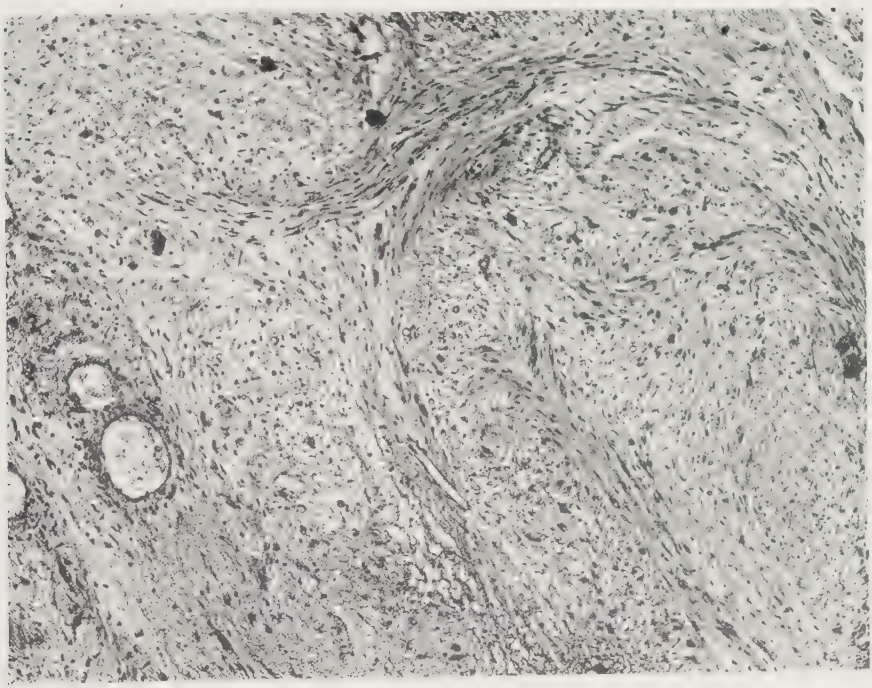

Fig. 154.—Case XXVIII. Interlacing bands of fibrous tissue with interspersed reticular areas (methylene-blue eosin: × 80).

ulations. Here, too, a large amount of fluid containing some gelatinous masses was secured from the lateral cistern. The growth was then identified, and the cerebellum brushed from its surface, giving a good exposure. The capsule was split and what was regarded as the chief mass of the growth removed piecemeal, leaving a cavity about 2.5 cm. in diameter. Such oozing as was produced was checked by the placements of cotton pledgets dampened in Zenker's fluid. Closure.

**Post-operative notes.**—The convalescence was uneventful. Healing perfect (Figs. 152, 153). No increase, even temporary, in pre-existing symptoms. Numerous stereo-Röntgenograms finally showed clearly a definite enlargement of the left porus acusticus internus.

She made an excellent recovery and at the time of her discharge was up and walking for the first time since her second operation two years before.

**Pathological note.**—Fragments of the tissue show the usual architecture (Figs. 154, 155 and 156) with bands of fibrous tissue, many areas being very hydropic. The growth in certain places is more vascular than usual. The vessels show no marked hyaline change. In certain reticular areas the cells are widely spread (Fig. 156) and there is marked hydropic change with tendency to degeneration, there being phagocytic cells with pigment due to diapedesis of the red cells. In some areas there is extensive degeneration of the cytoplasm and the nuclei, with certain tendency to cyst formation. In these areas, moreover, there are large cells which are most probably undifferentiated fibroblasts containing abundant cytoplasm, and some of these cells closely resemble ganglion cells (*cf.* Fig. 202). One definite mitotic figure was observed in one of these cells. The reticular areas appear to be of the same character as the fibrous areas but are undergoing degeneration and replacement by young cells.

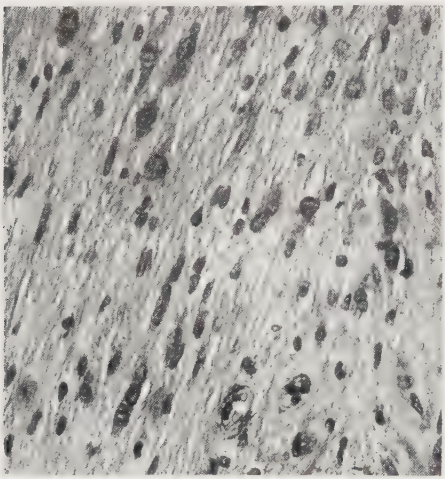

Fig. 155

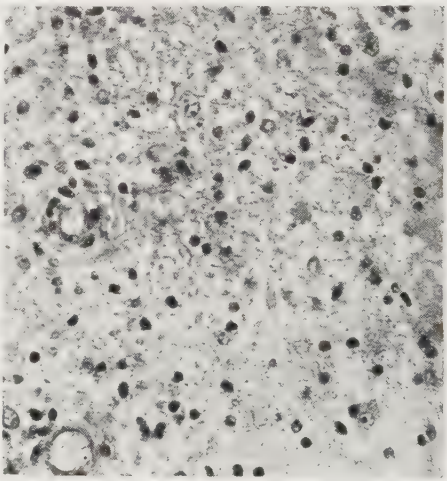

Fig. 156

Figs. 155, 156.—Case XXVIII. Showing fibrous area with young cells having cytoplasm: on right a typical reticular area.

**Comment.**—It is noteworthy that during the two years' interval between her early admission and the final enucleation of the tumor, the only advance in her symptoms lay in the gradual complete loss of function of the VIII$^{th}$ nerve. Unquestionably she would have been much better off if the second operation had not been performed, for the transection of the cerebellum was in all probability the chief cause of her permanent static disability.

The outstanding feature of her story concerns the two negative explorations and the easy exposure of the growth on the third attempt, not because it was of notably larger size, but for the reason, doubtless, that it was approached from a better direction. The experience was an illuminating one, as the case is probably representative of the several other uncertified though presumptive acoustic tumors in the series. I fear that in many of them the recess exploration has been conducted too high, with the internal auditory meatus, and thus the most distant pole of the tumor, as the immediate objective point, rather than the jugular foramen which would expose primarily the lower equator of the tumor. The former necessitates a much greater dis-

location of the cerebellum and in the process detaches the margin of the hemisphere and the arachnoid villi along the sinus. In most of these later cases the lower group of nerves were well exposed before the subsequent manipulations of the tumor were undertaken.

---

The successful series of nine consecutive operations which followed the fatality in Case XIX gradually restored confidence in the surgical procedure, and a more and more thorough enucleation, as can be seen from the operative notes, was being attempted. It was natural, therefore, that in the following case, the last of the operative series, the more radical procedure, simulating that in Case XIX, was undertaken, with the production of a wide-spread trauma of the adjacent nerves.

## Case XXIX

P.B.B.H. Surg. No. 6098. **Left acoustic tumor. Inconspicuous recess symptoms. Extensive intracapsular extirpation. Marked post-operative extracerebellar (cerebral nerve) disturbances. Recovery.**

*Jan. 16, 1917.* Admission of Arthur L., age 49, a soldier, referred by Dr. William Beatty of Utica, N. Y., with a diagnosis of brain tumor. He had been a soldier in the British army for 14 years and had had numerous cranial injuries, the most serious one during the Boer war (1900), when he was kicked on the back of the head by his horse. He apparently sustained a fracture of the base, for there was bleeding from the nose and he lost the sight in his left eye.

**Chronology of symptoms.**—As long as he can remember (since childhood) he has been "hard of hearing" in his left ear, but there has been no increase of deafness of late nor has he ever had any tinnitus. He does not regard his deafness as having any relation to his present illness.

For three years he has had severe occipitofrontal discomforts, localized on the left side, becoming more severe of late and attributed to constipation. For three years also he has had considerable staggering, increasing of late with a tendency to deviate to the left.

For two years he has had photophobia and a lowering of vision in his remaining (right) eye.

For eighteen months there have been recurring attacks which might be regarded as cerebellar seizures, and which he calls "fainting spells." He has a warning of these attacks and has to lie down during them, and says they are more like periods of "weakness and fear." He has had no convulsions.

*Status præsens.* Patient unusually alert and mentally clear. Nutrition fair.

**Positive neurological findings.**—(A) *General pressure.* A choked disc of 3 D. on the right; primary atrophy on left with 2 D. swelling superimposed. Complains of no headache but rather of an occipital discomfort. X-ray shows a slight pressure atrophy of the dorsum sellæ. Deep reflexes active.

(B) *Localizing.* Slight left suboccipital discomfort on pressure. (1) *Cerebellar.* Horizontal nystagmus, more marked, coarser and better sustained to left. Romberg positive: sways to left. Gait slightly unsteady, with deviation to left. Some dysmetria of left hand and leg on usual tests, but no pointing errors.

(2) *Extracerebellar. Cerebral nerves.* $V^{th}$ = Left corneal areflexa: otherwise normal. No subjective paræsthesias. $VI^{th}$ = Negative. $VII^{th}$ = Negative.

$VIII^{th}$ = No tinnitus. Considerable retraction of both drums. Hearing tests (with continuous irrigation of ear not being tested):

Fig. 157

Fig. 158

FIGS. 157, 158.—Case XXIX. Untouched prints from right and left mastoid plates showing what was taken to be an enlargement of the left porus acusticus internus (later disproved: *cf.* Figs. 162, 163).

| Watch. | Whispered Voice. | Conversation. | Loud Voice. | Galton. | Fork (Low Tones). | Rinné. |
|---|---|---|---|---|---|---|
| A.D. 4 in.<br>A.S. 0 | 8 ft.+<br>0 | 18 ft.+<br>2 in. | ....<br>3 ft. | normal<br>normal | 128<br>1024 | 60/25<br>AC>BC |

*Rotation tests* give practically normal labyrinthine responses, but on caloric tests no reactions could be produced from either ear, either as nystagmus or as deviation on past-pointing tests. The X-ray shows what appears to be a definite enlargement of the left porus internus (Figs. 157, 158).



Fig. 159.—Case XXIX. Fragments of tumor removed at operation (nat. size). Lower five fragments fixed in Zenker; others in neutral formalin.

IX$^{th}$, X$^{th}$, XI$^{th}$, XII$^{th}$ = Show no disturbance whatsoever.

The *clinical diagnosis* of a left acoustic tumor was ventured upon despite the undeveloped syndrome.

*Jan. 26, 1917.* **Operation.**—An exceedingly difficult and prolonged four-hour procedure. Marked respiratory embarrassment during the early anæsthesia. Venous stasis troublesome until the stage was reached at which a ventricular puncture could be performed. Continued drainage of ventricle during the remainder of operation. Suboccipital field between the sinuses was unusually small, the bone thick, and the emissary vessels large.

On opening the dura an immense amount of fluid was secured from the posterior cistern, and on dislocating the left hemisphere to the side a large lateral cistern was opened which flooded the field. Exploration beyond this cistern revealed the nodular surface of the usual acoustic tumor, which was approached from below

Fig. 161.—Case XXIX. Three weeks after operation, showing condition of wound.

Fig. 160.—Case XXIX. Post-operative left facial palsy and weakness of left accessorius group. Note droop of left shoulder.

rather than from the side. Lying below the tumor the bundle of the nerves to the jugular foramen could be seen. The capsule was incised in the usual way, and a very thorough intracapsular enucleation was performed (Fig. 159), oozing from the cavity being controlled with pledgets of cotton wet in Zenker's fluid. At the conclusion of the enucleation it was found that the lower portion of the tumor could be separated from the IX$^{th}$, X$^{th}$ and XI$^{th}$

bundle of nerves, so that the shell of this lower half of the growth was removed in one large piece. The wound was closed in layers as usual.

**Post-operative notes.**—The patient made an excellent recovery from his anæsthetic, but it was found that the left VII$^{th}$ nerve was completely paralyzed and that the XI$^{th}$ was seriously affected (Fig. 160). The trigeminus must also have been traumatized, for there

Fig. 162

Fig. 163

FIGS. 162, 163.—Case XXIX. Showing post-operative study of left porus, demonstrating error of previous view regarding its dilatation (*cf.* Fig. 158). Upper figure untouched. Lower figure redrawn from stereoscopic plates.

occurred quite an outbreak of herpes labialis. However, the weakness of the sternomastoid and trapezius muscles quickly disappeared, so that by the end of two weeks the shoulder movements were completely restored. Examination of the larynx showed no weakness of the vocal cord, for this had been anticipated. His dressing was done on the tenth day: perfect healing (Fig. 161).

**Subsequent note.**—The patient made a slow convalescence with steady improvement, though the facial paralysis promises to be permanent. Repeated studies of the left mastoid were made subsequent to the operation and despite the impression given by the earlier Röntgenograms that the left internal meatus was dilated, it was finally concluded, through a series of stereo-Röntgenograms, that this had been a mistaken observation (Figs. 162, 163).

**Pathological note.**—There are some thirty odd fragments of the tumor, varying in size up to pieces 2 cm. in their long diameter (Fig. 159).

*Histologically* they show (Figs. 164, 165, 166) the usual fibrous bands with more or less characteristic whorl and palisade arrangements of the nuclei. The areas of loose reticular tissue are comparatively infrequent and in them no structures suggesting glia fibrils are

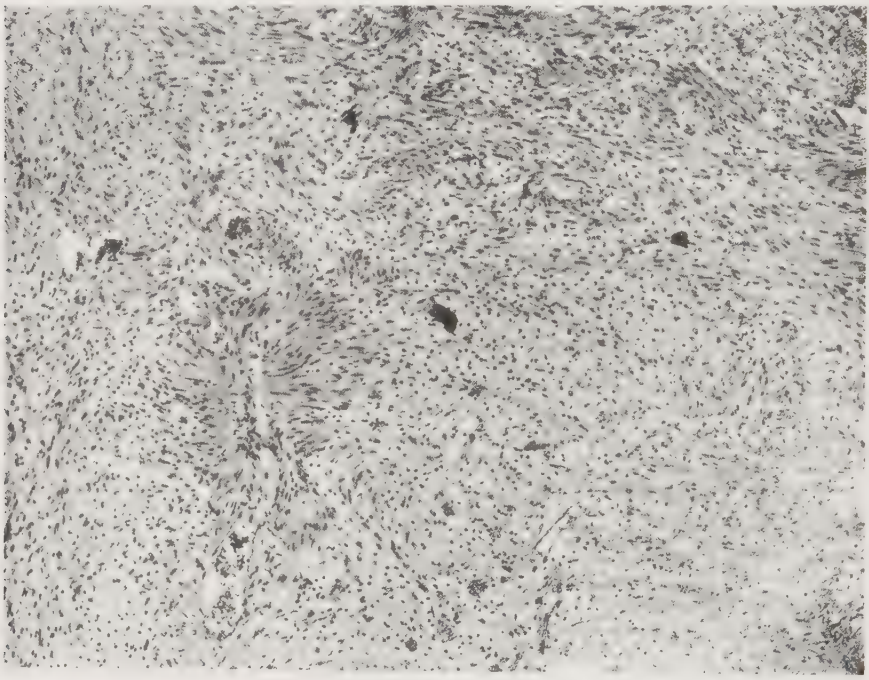

Fig. 164.—Case XXIX. Patch of fibrous tissue surrounded by an area highly infiltrated with fat cells (eosin methylene-blue: × 80).

found. The striking thing about the fibrous areas is the large amount of fat, and in this respect the tumor resembles Cases VII, XIX and XXI. The phagocytic fat cells are arranged along the longitudinal fibrillar bands (the fat in formalin hardened sections is anisotropic, transmitting polarized light). The tissue of the tumor in certain areas shows considerable hydropic change. There is slight hyaline change in the walls of the blood vessels.

**Comment.**—This case is out of the ordinary in the recorded long duration (since childhood?) of the auditory symptoms and the possible effect of the trauma in activating the growth of what may have been a long-standing indolent process. It is not at all improbable that the routine histological examination of auditory nerves secured at autopsy might reveal occasional tumor rests too small for naked eye observation and give us a better understanding

of the point of origin of these tumors. The cerebellar manifestations were fairly well marked, but the cerebral nerves showed merely an impaired function of the VIII$^{th}$ together with a definite corneal areflexa, the reverse, as can be seen, of Case XXVII, in which the cerebral nerves were extensively involved and the cerebellar signs inconspicuous. The syndrome, as may be noted, supports Oppenheim's contention of the occasional great diagnostic value of a lost corneal reflex.

The wide-spread post-operative palsies of the adjacent nerves provoked by the operative manipulations, largely intracapsular, gentle and bloodless as they were, serve to show how inevitable such nerve injuries must be when an attempted total extirpation by rougher methods is undertaken.

One thing which should be noted is the fact that no dysarthria or dysphagia was produced by the damage to the IX$^{th}$, X$^{th}$ and XI$^{th}$ bundle, which supports the view that these symptoms are due to pressure against the medulla

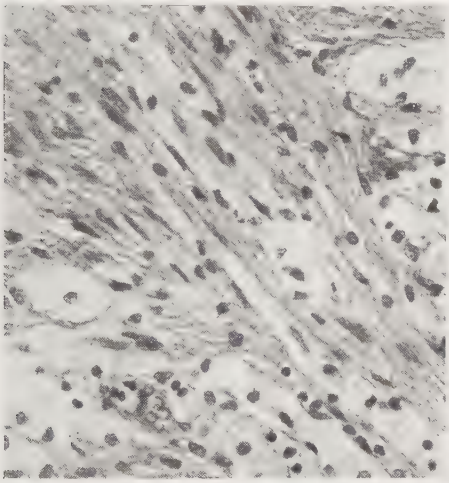

Fig. 165

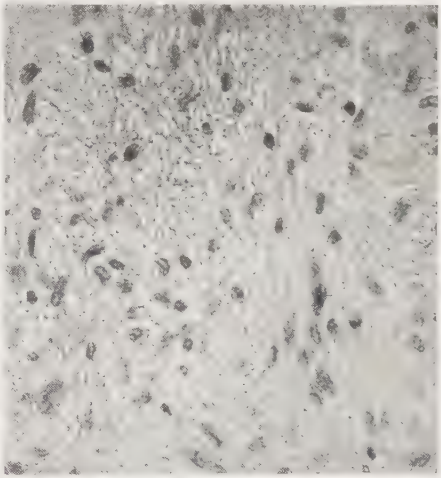

Fig. 166

Figs. 165, 166.—Case XXIX. Showing (left) fibrous area with fat cells: (right) reticular area.

rather than to the pressure involvement of the third or fourth posterior nerves.

The experience with the X-ray studies of the pori in this case is an illuminating one and served to cast considerable doubt on the interpretations of the cases which had been previously studied. In all probability it is unwise to attempt to interpret a condition of the porus internus from single plates, even though it is possible to study and compare the condition on the two sides. Not only are stereo-Röntgenograms necessary, but with our present inexperience several sets may be required before a definite opinion can be expressed.

The following case completes the present series of verified cases. When this study was begun the patient, like Case XXVIII, was listed among the cerebellopontile-angle (acoustic) "suspects." It was regarded,

moreover, as an almost certain example of bilateral acoustic tumors, and for that reason had been tentatively included in the chapter on Neurofibromatosis, in which the subject will be discussed. In view of a presumed double lesion and because of the advanced symptoms with complete blindness and deafness, operative intervention was not pressed at the time of her hospital admission, and as the diagnosis was not certified until recently, the case, like Case XXVIII again, does not appear in its proper chronological order in the series.

## Case XXX

P.B.B.H. Surg. No. 4522. **Multiple bilateral cerebral nerve palsies with motor incoördination, previously diagnosed as multiple neuritis. The syndrome attributed to a bilateral lesion. No operation. Survival seven months. Autopsy. Left acoustic tumor.**

*April 2, 1916.* Admission of Mrs. Grace W. C., age 37, referred by Dr. William McDonald of Providence, R. I.

The patient's family known as somewhat peculiar and eccentric: one brother with dementia præcox. In the past she has had periods of emotional depression with anæmia.

**Chronology of symptoms.**—The exact character of the onset is not entirely clear. She was married *April 3, 1912,* and became pregnant. Some unsteadiness of gait was observed from time to time by her husband, and a physician who saw her noted thickness of speech, some immobility of the face and drooling. These things were ascribed to her pregnancy and she went on without special complaint until six weeks before her expected confinement (i.e., in *January, 1913*). She awoke one morning with a peculiar numbness on both sides of the tongue and face, and she staggered greatly on attempting to walk. At about this time deafness in the left ear was first noticed. (It may have been present long before.) A Cæsarean section was performed *Feb. 14, 1914,* owing to a threatened eclampsia, with survival of a healthy child. On *May 28, 1914,* she consulted an oculist owing to periods of diplopia from a paresis of the left abducens.

When seen soon after this by Dr. McDonald she complained of weakness, lack of emotional control, subjective failure of vision, a dull suboccipital discomfort, occasional periods of cephalalgia with vomiting, defective sense of taste and smell, insensibility of the lips and mucous membranes and consequent difficulty of eating, clumsiness of movements and paræsthesias of the left forearm. In addition he observed anosmia, a choked disc, a bilateral facial weakness with some exophthalmos, giving her a peculiar staring appearance with pendulous lower lip. Weakness of both abducentes but particularly the left, insensitivity of the entire face and mucous membranes, especially on the right, nystagmus, defective articulation, deviation of the tongue to the right, static ataxia with falling to either side or forward, a marked staggering suggesting a tabetic gait, and incoördination of the extremities, especially of the left leg.

In short, "of the 12 pairs of cranial nerves ten pairs appeared to be involved on one or both sides, one pair on the left (the VIII$^{th}$) and one on the right (the XII$^{th}$)."

The patient, moreover, had a bacteriuria which, together with a very noticeable fluctuation of the intensity of many of the cerebral nerve palsies, led to confusion. On *Dec. 18, 1914,* a diagnosis of poliomyelitis was made. Another diagnosis was a cerebral inflammation and œdema associated with the threatened eclampsia.

Other opinions were a multiple neuritis and a basilar meningitis of luetic (though the Wassermann was negative) or tuberculous origin.

Early in 1915 deafness in the right ear began to be noticeable. By *May, 1915*, she had become completely blind. The final complete loss of hearing was abrupt. Since then there has also been bilateral paralysis of the masticatory muscles. Of late there have been a number of convulsive attacks, with flushing, exophthalmos, rigidity and unconsciousness—probably typical cerebellar seizures.

Dr. McDonald's analysis and impression of the case, which was sent with the patient, is as follows:

"1. Sudden onset of acute symptoms six weeks before confinement.

"2. Involvement of a large number of cranial nerves from the start without progression from a focus. To be sure the severity of the symptoms relative to particular structures has increased though periodic improvement was pronounced. On the other hand, there has been pronounced and permanent improvement in the function of other parts, notably the III$^{rd}$, IV$^{th}$ and VI$^{th}$ cranial nerves.

"3. The process has extended from the left auditory structures (deaf on left from start) to the right and bilateral progression has also occurred in the visual tracts. But, the first and twelfth pair were involved from the beginning, so that whatever lesion was present over two years ago was exerting its influence from the anterior to the posterior poles of the brain stem.

"4. If the disorder is due to a brain tumor it is remarkable that despite its growth certain structures lying between the cribriform plate and the twelfth nuclei have been relieved from pressure and have resumed their function.

"Headache has not been a marked symptom and vomiting has occurred but occasionally, which would be difficult to explain if a neoplasm of sufficient extent to involve the brain stem from front to back in the beginning had been growing in size for over two years.

"5. The gait has never been of the cerebellar type, though ataxia is now much more marked than in the beginning.

"6. From the first there have been evidences of spinal tract involvement hardly to be explained by interference with supra-nuclear arm and leg mechanisms (incoördination, ataxia, tingling, prickling of right face and left forearm).

"Impression. A chronic proliferative basilar meningitic process."

**Examination on admission.**—A greatly undernourished woman, completely blind and deaf, with staring exophthalmos and expressionless face, a hanging jaw and flabby lip over which she drools. Very ataxic but able to sit up in a chair. A slurring speech barely understandable, and her attendant communicates with her by numerically tapping out letters on the palm. Her mentality is apparently normal and she is alert.

**Positive neurological findings.**—(A) *General pressure.* A secondary optic atrophy: vision nil: pupils wide without reaction. Exophthalmos and dilatation of extracranial vessels. Headaches not marked though periods of severe suboccipital pain common. Vomiting infrequent though formerly very pronounced. Complete anosmia. X-ray shows extreme secondary pressure absorption of sella turcica and marked dilatation of diploëtic sinuses.

(B) *Localizing.* Suboccipital discomforts radiating to front; cervical rigidity and tenderness.

(1) *Cerebellar.* A few fine nystagmoid jerks on looking to the right only (*cf.* ophthalmoplegia). Extremely coarse dynamic ataxia of all extremities during purposeful movements. Manages, however, to do coarse knitting. In attempting to walk with support legs thrown wildly. Unable to stand alone.

Deep reflexes all exaggerated: no clonus. Babinski questionable.

(2) *Extracerebellar. Cerebral nerves.* III$^{rd}$, IV$^{th}$ and VI$^{th}$ = Almost complete ophthalmoplegia: conjugate deviation impossible except to the right. V$^{th}$ = Bilateral areflexa cornealis and more or less marked hypæsthesia (total analgesia on right) over both

trigeminal fields, skin and mucous membrane. Complete bilateral paralysis of masticatory muscles. VII$^{th}$ = Almost complete bilateral palsy: slight movements possible, better on left. Complete ageusia.

VIII$^{th}$ = History of bilateral tinnitus preceding complete deafness: no labyrinthine responses to caloric tests elicited from either side.

IX$^{th}$, X$^{th}$ = Complete ageusia: dysarthria and dysphagia. Swallows food only when placed far back on tongue. From character of voice a probable vocal cord paralysis (larynx not examined).

XI$^{th}$, XII$^{th}$ = No disturbance noticeable. Tongue in mid line.

FIG. 167.—Case XXX. Photograph of base of brain showing large left acoustic tumor. Note distended third ventricle: the evidence of villous herniations over the lips of the temporal lobes: the scar of the porus attachment (*cf.* arrow).

**Clinical diagnosis.**—Bilateral cerebellopontile-angle tumors (acoustic fibroneuromata). No associated von Recklinghausen's manifestations.

An operation was not favored by the patient's family and she was discharged *April 8, 1916.*

**Subsequent note** (by letter).—"Though shut off from the external world except by the sense of touch, she retained her interest and remained mentally active almost to the last." She died *Nov. 6, 1916.* The end was sudden, as it so often is in non-decompressed cerebellar cases.

**Pathological notes.**—The brain unfortunately was not removed immediately nor was it hardened *in situ*, so that the relations were largely lost. But from all that I can gather the terminal picture was similar to that described by Cruveilhier, with marked herniations into absorption fossæ in the base of the skull, the nature of which was not understood, and a widely dilated and absorbed sella. There was a large left acoustic tumor, a photograph of which (Fig. 167) has been kindly sent to me by Dr. McDonald. The small scar of the attachment at the porus is clearly apparent.

**Comment.**—An exploratory operation was suggested but not warmly recommended, for vision and hearing were supposedly gone beyond recall. The mere prolongation of life in her sorry condition hardly justified intervention, particularly in view of the fact that her discomforts at the time had largely subsided, and death when it occurred was likely to be sudden in one of her convulsive attacks and therefore unattended by great suffering.

With full consciousness of the misjudgments which may arise from so vividly visualizing a lesion that one unconsciously makes the recital of the case history correspond, it nevertheless was difficult to believe, when she was under observation, how any other than a bilateral acoustic tumor could possibly have accounted for this woman's symptoms. It will be recalled that a few other cases in the series (e. g., Cases VIII and XIX) were under suspicion of having bilateral lesions, but so far as I am aware there is no recorded instance of a correct antemortem diagnosis of such a condition, apart from the multiple cerebral nerve lesions which may accompany generalized neurofibromatosis, ever having been made.

---

The foregoing series of cases, all of which but Case IV were histologically verified and all but Case XXX operated upon on one or more occasions, furnishes the basis of the symptomatic, pathologic and surgical analyses of the subsequent chapters. The case histories show clearly the slow progress in our understanding of these lesions. However, our diagnostic ability has unquestionably improved; the histological designation has passed from endothelioma to fibrosarcoma to glioma to fibroneuroma or, better, to the unequivocal acoustic tumor; the surgical procedure, moreover, has become far safer with experience, though in the process of acquiring this the operation has had its distinct ups and downs.

It must be remembered that experience was acquired not from these verified cases alone, for not only were there a large number of intracerebellar lesions in the clinic during the fifteen years, but, what is more, there were thirty-five cases in which a cerebellopontile-angle tumor was suspected though not verified. In the following chapter illustrations of these acoustic tumor suspects will be given.

## CHAPTER IV

## CASE REPORTS (Continued)

### Examples of Unverified Tumors

With but one exception the lesion has been histologically verified in all of the thirty cases recorded in the preceding chapter. The exception (Case IV of the Baltimore series) was included in its chronological order merely because of its importance from a surgical point of view, since it illustrated the possibility of successfully carrying through a suboccipital operation under prolonged artificial respiration.

In the statistical tables which have been given in Chapter II it was pointed out that in the group of 91 extracerebellar lesions there were 35 presumable or suspected, though unverified cases (*cf.* Table 2). Naturally all of them were cases with a cerebellopontile-angle syndrome, for one would hardly venture to make a diagnosis of an extracerebellar lesion in their absence, and hence they are listed in Table 3 (p. 17) with the tumors of the angle.

From this latter table it is apparent that 30 of the 37 verified tumors of the angle proved to be acoustic tumors, and it is safe to say that about three out of four of the unverified 35 cases are of this same nature. Four of the cases now in the verified list (Cases VII, XV, XXVIII and XXX) were at one time classified as presumptive though unverified, and the larger number of the present 35 "suspects" are cases which came under observation some years ago when we felt less certain of our diagnoses and when hesitation was felt about too radical an investigation of the conditions far in the recess.

In order that it may be apparent in this group of cases on what clinical basis the diagnosis rests, three random cases from the Boston series have been chosen to serve as illustrative types. Another purpose will be served by this recital, for the cases show what may be accomplished by a wide suboccipital decompression alone—that is, without partial tumor removal—in the way of palliation of symptoms and prolongation of life of patients with acoustic tumors.

The first of them had advanced pressure symptoms at the time of operation, and survived for about the usual three-year period. The story follows.

### Case XXXI

P.B.B.H. Surg. No. 534. **Right cerebellopontile-angle (presumed acoustic tumor) syndrome. Decompression and evacuation of encysted recess fluid. Survival two years, ten months.**

*Oct. 30, 1913.* Admission of Henry G. L., a farmer, 32 years of age, referred from the Portland, Maine, Eye and Ear Infirmary.

*Trauma.* In 1906 he fell from a tree, striking suboccipital region.

**Chronology of symptoms.**—For about two years right tinnitus followed by deafness and subsidence of tinnitus. For one year staggering gait, attacks of vertigo with falling, occipital headaches (becoming general);

stiffness of the neck, and failing vision. Recently nausea and vomiting and numbness and neuralgic discomforts of the right face. Four months of antiluetic treatment: also treated for lead poisoning.

**Positive neurological findings.**—(A) *General pressure.* Anosmia. High grade of choked disc (6 D.) with pallor and vision reduced to shadows. Dilatation of extracranial vessels. X-ray shows usual pressure changes with absorption of dorsum sellæ.

Deep reflexes overactive and equal.

(B) *Localizing.* Suboccipital tenderness on right. (1) *Cerebellar.* Nystagmus marked, coarser to right. Positive Romberg: falls to right. Gait deviates to right. Some incoördination with ataxia of arms.

(2) *Extracerebellar. Cerebral nerves.* $V^{th}$ = Marked hypæsthesia of right face and mucous membrane. Right corneal areflexa. Jaw deviates to right. $VI^{th}$ = Weakness of right abducens. $VII^{th}$ = Lower facial weakness with some blepharospasm: right ageusia.

$VIII^{th}$ = Complete right deafness. No labyrinthine tests. No definite change in right porus demonstrated.

(3) *Misleading.* Paræsthesias of arms and legs. Tenderness of right parietal and temporal regions.

**Clinical diagnosis.**—"Tumor of right cerebellopontile angle."

*Nov. 3, 1913.* **Operation.**—Bilateral suboccipital craniectomy. Puncture of lateral ventricle necessitated by pressure. Marked pressure cone. Exposure of arachnoid cyst in right recess. Evacuation of cyst. Closure.

**Post-operative notes.**—Considerable dysarthria for some days. Healing *per primam* (Fig. 168). Marked improvement in general condition: local symptoms much as before. Choked disc largely subsided by December 5. Vision reduced to shadows. Discharged *Dec. 8, 1913.*

Fig. 168.—Case XXXI. Condition on discharge four weeks after operation.

*May 17, 1915.* Reports condition practically unchanged. Further operation advised and refused.

*Aug. 31, 1916.* Death, following a few weeks of illness, reported by letter.

**Comment.**—This was in all probability a cyst-capped tumor of the acusticus. The operation was performed in 1913, and in a number of later experiences, as has been pointed out in the series of verified tumors, after opening a thick-walled cyst, thought at first to represent merely a circumscribed chronic arachnoiditis, an underlying tumor was disclosed. It is true that arachnoid cysts may produce symptoms which simulate angle tumors, but though tinnitus and vertigo and a Ménière's syndrome may occur, complete deafness and such pronounced pressure symptoms are hardly to be expected.

There can be little doubt, from the characteristic chronology of the symptoms, as to the correctness of the diagnosis, and the case has been chosen from among those which show that on the average a three-year period represents the expectancy of life after a suboccipital decompression. Case IV, to be sure, is a notable exception to this, and it is possible that the average survival may be more than three years, but I have at this writing no figures regarding the end results of the acoustic tumor suspects of the Baltimore series.

The following case with an undeveloped syndrome was first listed as an "intracerebellar tumor: uncertified: presumable glioma," but a subsequent review of the history with re-examination of the patient has brought out more clearly the actual chronology of the extracerebellar symptoms which makes the diagnosis of an acoustic lesion probable.

## Case XXXII

P.B.B.H. Surg. No. 950. **Unverified though undoubted right acoustic tumor with early cerebellopontile-angle syndrome. Suboccipital decompression. Recovery.**

*Feb. 20, 1914.* Admission of Carl M. C., a clerk, age 46, referred by Dr. N. K. Wood of Boston, Mass., with the diagnosis of probable brain tumor.

On the whole he has heretofore enjoyed good health. His occupation is exacting and entails his being on his feet for nearly 12 hours a day. On *January 2* he entered the ambulatory clinic of the Massachusetts General Hospital, with the story that for six weeks he had noticed, associated with a period of frontal headaches, some awkwardness of his right side and dizziness when turning to the right.

During the examination relative loss of hearing on the right was observed. He was referred to the Eye and Ear Infirmary, where the condition was regarded as a chronic otitis media with accompanying vertigo. The opinion was given with some reservation, as an obscuration of the nasal margin of the right optic papilla was also noted at the time.

**Chronology of symptoms.**—The order of his symptoms, particularly in relation to the onset of the auditory disturbances, is not entirely clear, but as elicited after his admission, they are as follows:

For three months a sensation of falling toward the right side, which has increased so that for two weeks he has been unable to walk alone. Frequently accused of being intoxicated.

For six weeks periods of numbness of the right face, fluctuating in intensity.

For about a month he has noticed an impairment of hearing on the right with bilateral (?) tinnitus (both symptoms possibly of much longer duration). Four weeks ago a period of temporary diplopia.

For two weeks forward flexion of the neck has caused sharp pain referred to the right temple and forehead, and of late there have been marked suboccipital soreness and tenderness.

*Physical examination.* The skin shows several pigmented moles and pedunculated fibromas.

**Positive neurological findings.**—(A) *General pressure.* An early bilateral choked disc. X-ray shows evidences of pressure with partial erosion of the dorsum sellæ.

(B) *Localizing.* (1) *Cerebellar.* Nystagmus in all directions: coarser to right. Conjugate deviation to right poorly sustained. Station unsteady with eyes open: falls in any direction. Considerable right dysmetria and adiadococinesia. No especial incoördination or ataxia. Gait impossible without support: lurches to right.

Deep reflexes active and equal.

(2) *Extracerebellar. Cerebral nerves.* $V^{th}$ = Subjective numbness: marked hypæsthesia

over entire right trigeminal area with absent corneal reflex. Jaw deviates to the right. VI$^{th}$ = Weakness of right abducens: periods of diplopia. VII$^{th}$ = Right face subjectively and objectively slightly drawn: relative ageusia.

VIII$^{th}$ = Constant bilateral tinnitus like a "dull whistle." Hearing on left normal. On right, practically deaf but Galton whistle still heard. No labyrinthine responses elicited on irrigation of either ear and nystagmus unmodified. The X-rays of the pori were inconclusive.

IX$^{th}$, X$^{th}$, XI$^{th}$ and XII$^{th}$ = Slight dysarthria.

During the two weeks he was under observation there was a marked increase in his symptoms, with elevation of the discs to 4 diopters. There were several critical attacks resembling cerebellar seizures, with sudden unconsciousness, slow labored respiration and a drop in the pulse rate to circa 40 beats per minute. One of these occurred while he was being shaved preparatory to his operation.

*Mar. 7, 1914.* **Operation.**—The usual bilateral suboccipital exposure. Dura very tense. Primary dural opening near site of foramen magnum, securing fluid and relieving tension without necessitating ventricular puncture. Marked pressure cone. Puncture of each protruding hemisphere negative. Exploration of left lateral recess negative, but

Fig. 169 Fig. 170 Fig. 171

FIGS. 169, 170, 171.—Case XXXII. Three years after a simple suboccipital decompression for unquestioned right acoustic tumor.

in the depth of the right recess what appeared to be adhesions between hemisphere and dura were encountered. Further exploration was thought to be unwise.

**Post-operative notes.**—Considerable temporary increase in dysarthria with dysphagia, which subsequently lessened. Healing perfect. Some subjective improvement in hearing; persistence of tinnitus becoming localized in right ear.

There was progressive though slow improvement, with a steady gain in weight and strength. By *June 16*, when he was discharged, the discs were flat and he was beginning to get about on his feet unsteadily with the use of a cane.

**Subsequent notes.**—An examination every few months during 1915 showed a continued gain and gradual subsidence of most of the cerebellar signs, including the nystagmus. The cerebral nerve symptoms remained much as before the operation, though the improvement in hearing was only temporary, and with the onset of complete deafness during the year the tinnitus subsided.

During 1916 he continued well and free from discomforts and on *Aug. 30, 1916*, the only positive neurological findings were complete right acoustic paralysis, confirmed by caloric tests, slight hypæsthesia and slight

expressional weakness of right face, considerable dysarthria, a positive Romberg and some unsteadiness of gait, though he gets about very actively and well for the time being.

*Mar. 23, 1917. Reports for examination.* Condition remains excellent, and though unsteady is able to get about alone. No headaches, choking of discs, or tinnitus. *Cerebellar;* positive Romberg with falling to right; slight nystagmus; drunken gait. *Cerebral nerves:* numbness of right V$^{th}$ with corneal areflexa; slight facial weakness on right; complete VIII$^{th}$ paralysis shown by caloric tests. Dysarthria persists. Renewed studies of the pori (stereoscopic) show no change, though the outlines of the right meatus internus may be a little less sharp than on the left. No post-operative photographs were taken of this patient, but the condition three years later is shown in Figs. 169, 170, 171.

**Comment.**—The presumable diagnosis of an acoustic tumor in this case was not made at the time of his hospital residence for the reason that we were not thoroughly awake to the significance of the early auditory symptoms. Communication with the patient was not easy, as he spoke broken English: the recorded onset was an unusually acute one and he was suffering from severe cerebellar attacks. The outline of the case history rearranged for presentation in this report in accordance with the more accurate information gradually accumulated, fails to picture the early sources of confusion. All this merely goes to show the necessity of an accurate history, without which errors of diagnosis in these cases are so readily made.

No one would doubt for a moment the presence of an acoustic tumor from an examination of the patient in his present condition, even though the pressure signs remain in abeyance. In all probability the time will come when an attempted enucleation will be indicated, but as yet he is very comfortable, his vision is intact, and he is well enough to take over his wife's household duties while she has become the main wage-earner.

In the following case, unlike the foregoing, some doubts might be expressed as to the diagnosis.

## Case XXXIII

P.B.B.H. Surg. No. 4509. **A Ménière's syndrome followed by variable cerebral nerve disturbances, chiefly right. Operation. Temporary improvement. Presumptive cerebellopontile-angle (right acoustic) tumor.**

*Mar. 29, 1916.* Admission of William L., age 29, a clerk, referred by Dr. T. J. Burrage of Portland, with intracranial tumor symptoms.

*Trauma.* A fall, striking the top of the head, ten years previously: unconscious for 14 hours: scalp wound sutured.

**Chronology of symptoms.**—For ten years: Stabbing neuralgic pains in forehead, eyes and left upper teeth: also considerable headache described as a sense of pressure. Most of his present symptoms he dates from a period 15 months ago, and he is not certain of their exact order of onset.

For fifteen months: ''Dizzy spells'' associated with faintness and a "buzzing and ringing" tinnitus in the right ear, and accompanied by sudden uncontrolled vomiting and vertigo so marked that he has occasionally fallen to his hands and knees. These attacks, which resemble a Ménière's syndrome, come without warning, often on first arising in the morning, and of late with any sudden change of position even while recumbent. If on his feet he would

stagger and fall generally to the left. The more severe of these attacks may last several days.

For about fifteen months also, his employer has complained of his being "hard of hearing." The patient ascribes this to the noises in his ears and does not know which one is chiefly affected. He has had some auditory hallucinations ("church bells": "strange voices") and volunteers that he is a sensitive person and has some delusions of being persecuted.

About fifteen months also: A ten-week period of paræsthesias of the right side of the face and loss of the sense of taste on the right. These symptoms subsided for six weeks and returned again for a time, together with a sensation of drawing of the right face so that he was unable to whistle. A right blepharospasm has been present and noticed by his friends since the outset.

For one year: Numbness and paræsthesias of the arms and legs, chiefly on the right with some subjective weakness, a sense of fatigue, and a tendency to drop objects from his hands. Unusual drowsiness has been noticeable. For five months he has become increasingly unsteady on his feet. For the past three weeks there has been an increase in his staggering and he has been accused of drinking. Also a loss of visual acuity and double vision.

**Positive neurological symptoms.**—(A) *General pressure.* Early choked disc with blurring of nasal margins: more right than left. X-rays show no pressure changes.

Deep reflexes equal and active throughout without clonus.

(B) *Localizing.* Head held tilted to right. During his attacks lies on right side, as turning to left provokes nausea and vomiting. No suboccipital tenderness.

(1) *Cerebellar.* Nystagmus, horizontal and rotary, chiefly confined to right eye: coarser to right. Marked Rombergism: falls to left. Considerable incoördination of left hand, with dysdiadococinesia. Static ataxia marked: requires support in walking, due to great dizziness.

(2) *Extracerebellar. Cerebral nerves.* III$^{rd}$ = Some apparent weakness on left. V$^{th}$ = Variable hypæsthesia on right to all stimuli; apparent slight hypæsthesia on left. Left corneal hyporeflexa (?). VI$^{th}$ = Near paralysis on left. Persistent diplopia. VII$^{th}$ = Weakness on left apparent at rest and on expressional movements: winking reflex impaired. Relative ageusia on right tongue.

VIII$^{th}$ = Tinnitus referred at present to left ear: also subjective lowering of hearing. Tests inconclusive: slightly reduced air conduction on right. Weber referred to right. Labyrinthine responses equal right and left. X-rays of pori inconclusive (*cf.* later studies Figs. 175, 176).

IX$^{th}$, X$^{th}$, XI$^{th}$, XII$^{th}$ = No dysarthria or dysphagia. Tongue protrudes occasionally to right.

(C) *Misleading.* Occasional visual and olfactory hallucinations. Some mental change with impairment of memory.

**Clinical diagnosis.**—"A subtentorial new growth, presumably a left cerebellopontile-angle lesion."

*April 1, 1916.* **Operation.**—Usual bilateral exploration. No marked pressure. Large posterior cistern. No pressure cone. Unsatisfactory exploration of each recess negative. Closure.

**Post-operative note.**—Considerable nausea and vomiting for three days. Healing normal (Fig. 172). The discharge note on *April 26* records a marked lessening of entire preoperative symptomatology. Cessation of discomforts, of nausea and vomiting, of the neuralgia and numbness, of the diplopia and left ophthalmoplegia, facial weakness, tinnitus, Rombergism and staggering. A slight lateral nystagmus persisted and some dizziness, but practically no other residual evidences of his former symptoms.

**Subsequent notes.**—*Aug. 31, 1916. Returns for observation.* Has been at former work since the end of April. *Subjective:* Slight awkwardness of hands, particularly left, noticed on tying cravat. Occasional slight diplopia on looking to left. *Objective:* Slight

poorly sustained lateral nystagmus. Station and gait normal. Slight awkwardness of left hand. Slight apparent weakness of right lower face. No choked disc. The X-ray shows an apparent enlargement of the right porus (*cf.* later studies, Figs. 175, 176).

*Nov. 4, 1916. Readmission.* Has been doing well: at work: marked gain in weight: no subjective disturbances until two weeks ago, when there was a temporary return of the diplopia and right facial weakness and right ageusia: also some "nervousness." Thinks his hearing is less good and there is a "numb sensation" in the left ear as though he were "going to have an earache."

*Status.* Discs slightly hyperæmic with some tortuosity of vessels and œdema of nasal margins. A positive Romberg sign: gait almost perfect, though slight dizziness when turning sharply to the left. Nystagmus coarser to left. Conjugate deviation to left fatiguing. $V^{th}$ = Bilateral corneal areflexa: slight objective hypæsthesia on right. $VI^{th}$ = Diplopia

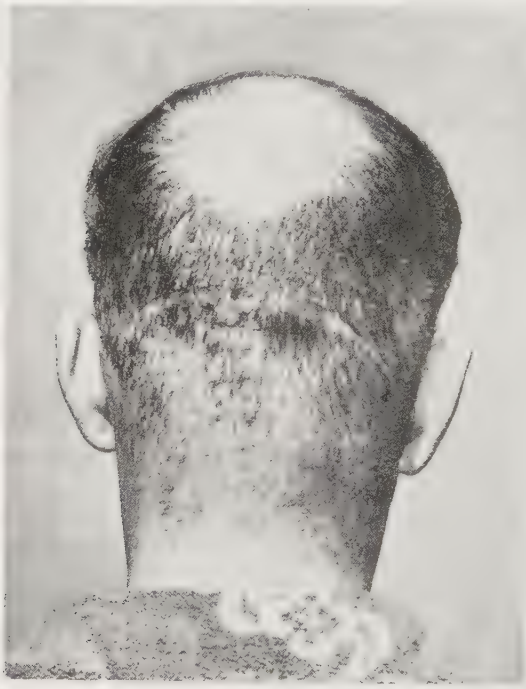

Fig. 172.—Case XXXIII, 18 days after operation, showing wound healing.

with head in certain positions. $VII^{th}$ = Negative: history of recent right (contralateral) weakness. $VIII^{th}$ = Watch 3″ right: 1″ left. Labyrinthine tests (caloric and rotary) give practically equal reactions from both sides.

*Mar. 13, 1917.* Reports for examination. Continues well: at work (Figs. 173, 174). Aside from a slight Romberg and slight nystagmus to the right, there are practically no positive neurological findings. Gait normal. Disappearance of the divergent squint. Stereo-Röntgenograms show normal pori interni on the two sides (Figs. 175, 176).

**Comment.**—This case has been chosen to illustrate the average uncertainties of diagnosis at a stage of a presumed lesion in which the extracerebellar symptoms are fluctuating and more or less bilateral, and before there is any definite certainty of impairment of the acoustic nerve. The decompression

Fig. 173

Fig. 174

FIGS. 173, 174.—Case XXXIII. Condition after one year: practically invisible wound after accurate closure.

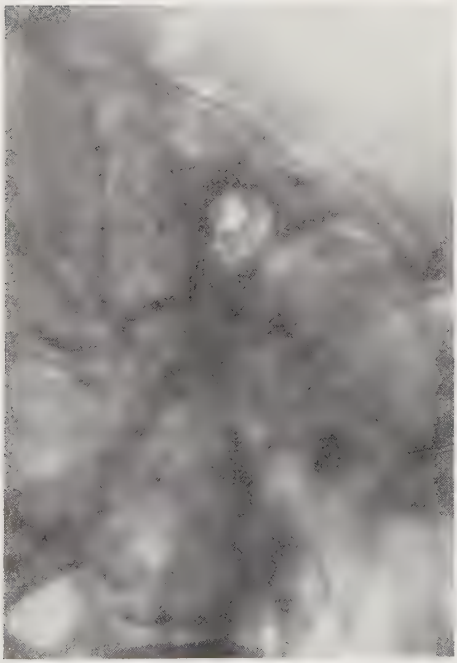

Fig. 175

Fig. 176

FIGS. 175, 176.—Case XXXIII. Untouched prints from the pairs of stereoscopic plates showing normal right and left pori interni. Ideal "collar button" position.

has so far relieved the general pressure symptoms and greatly ameliorated the cerebellar manifestations which, however, pointed fairly conclusively to a lesion on the left. The cerebral nerve disturbances have been more marked on the right, the side of the original Ménière's syndrome. On this side there appeared to be an enlargement of the porus, but, as has been true of several other cases, this was subsequently disproved by stereoscopic studies.

Other examples might be given of presumed though unverified tumors from the 35 cases in the series so designated. The enumeration of others would too greatly prolong this study, which must necessarily be based chiefly on the verified cases. The four clinical histories which have been abstracted, however, illustrate firstly an almost certain case (Case IV): another (Case XXXI), somewhat less certain though also with an arachnoid accumulation over the cyst: a third (Case XXXII) with fairly characteristic symptoms of recent onset: and a fourth (Case XXXIII) with a somewhat more obscure clinical picture. All of these cases, as can be seen, improved greatly as a result of the decompressive after-effects of their cerebellar exploratory craniectomy. In this respect Case IV is perhaps exceptional with fairly quiescent symptoms for nearly eight years: Case XXXI is perhaps more nearly the average, with a survival for about three years uninfluenced by a further operation: Case XXXII will doubtless reach the limit of benefit from the decompression ere long, and Case XXXIII, if the patient actually has an acoustic neuroma, should continue relatively free from symptoms for two years more.

It may be of some interest to note that when this short chapter was first planned, Case XXVIII of the present verified series was one of the non-certified cases selected for inclusion here, for her symptoms on her first admission were in many ways comparable to those shown at present by Case XXXIII.

In assuring the diagnosis of these suspected cases in which an operation for one reason or another has fallen short of disclosing the expected lesion—granting the possibility, of course, that it is there—one would like to lean more heavily than is now possible on the condition of the porus acusticus internus, and it is hoped that time will improve our methods of detecting changes in the canal.

As matters stand at present, one is reminded of the discussions pertaining to the diagnosis of other lesions, such for example as a duodenal ulcer, in which some regard the Röntgenographs as the most important, some the clinical examination, and some the patient's history as the most significant. In the case of an acoustic tumor, the order of relative value would be first the history, second the neurological examination, and third the X-ray. Of course an X-ray negative may alone suffice if it shows a dilated porus, just as it may in the case of a duodenal ulcer when it shows a definite filling defect, but a dilated porus is unfortunately less common than Henschen's studies had led us to expect, and is only of value, therefore, as confirmatory evidence. For the present, chronology of the symptoms remains unquestionably the most important factor in the diagnosis and should be patiently unraveled in every patient with a cerebellopontile-angle syndrome.

## CHAPTER V

# ETIOLOGY AND INCIDENCE

**Relation to trauma and infection.**—Unlike other forms of intracranial tumor, particularly the fibro-endotheliomata* arising from the meninges, trauma does not seem to have played any very important antecedent rôle in this series of cases. In only six of the patients in the present series (e. g., Cases II, VII, X, XXVI, XXVIII and XXIX) was there any definite history elicited of a cranial injury of some possible etiological moment. In most of them the trauma had been received a number of years before the onset of symptoms, though it is of interest that in all the blow was an occipital one.

The literature, however, contains many examples in which there appears to be a definite relation to trauma. A few may be cited. In one of the very early reports (1867) Brückner,[36] in describing the case of his own wife, attributed her symptoms to a fall on the ice, with a blow on the occiput, which occurred three years before the onset of deafness. Another and more rapid case was reported from the Salpêtrière by Collin and Barbé,[40] with early symptoms and death in 26 months after the injury—a very short story for one of these lesions. In Alagna's[3] carefully studied case of a young soldier the symptoms were the definite sequel of an occipital injury.

According to Henneberg and Koch[78] there is very often an antecedent history either of injury or of otitis media (*cf.* Cases I, VII and XV) or of otorrhœa, and Hessler is said to have assembled nineteen examples of acoustic tumor in patients who had suffered from ear diseases. In reviewing the present series of cases it was anticipated that such a history would prove to have been more frequently elicited, for we have labored somewhat under the impression that some insult, traumatic or infective, played a significant rôle in the causation at least of the meningeal growths with which the acoustic tumors had originally been classified.

**Embryonal rests.**—Sternberg,[174] as may be recalled, regarded the tumors as in all likelihood of embryonal origin and he attributed them to an *anlage* of glia tissue which might be either in the nerve itself or outside of it, thus explaining the cases in which the nerve spanned rather than traversed or became lost in the substance of the tumor. The V$^{th}$, VII$^{th}$, VIII$^{th}$, IX$^{th}$ and X$^{th}$ pairs, the so-called dorsal cerebral nerves, develop from the tissue band lying between the ectoderm and the dorsal face of the neural tube and, as we shall see, a neuroglia sheath extends for some distance onto these nerves, in the case of the acusticus even as far as the internal auditory meatus.

---

* An interesting description has been given by Weygandt[230] of a patient with a cerebellopontile tumor which so definitely followed an injury as to have made it the occasion for litigation. The lesion in the end proved to be an endothelioma of the angle and not a true acoustic tumor.

Verocay,[186] whose conclusions will be quoted in full (p. 215), also regarded these lesions as attributable to a rest of embryonal tissue in the nerve, and it is also Henschen's suggestion that embryonal connective tissue may persist in the binding tissue of the acoustic fibres longer than in the other cerebral nerves and that the tumors arise from the proliferation of this tissue.

Reference has already been made to Orzechowski's[135] belief that cerebello-pontile-angle tumors arose more often from an *anlage* of the middle wall of the recess than from the nerves. Unquestionably the angle has a complex structure and in the course of its development tissue rests may be deposited, just as they are in the development of the pituitary body, and give rise later on to neoplastic growths. These tumors, however, are more apt to be of a teratomatous nature and lesions of this sort have been described in the lateral recess of lower animals (Lutz[118]) as well as of man. Spiller[169] has briefly reported a case which he believes to be of this nature, and doubtless most of the teratomas found in the angle have such an origin. They certainly cannot be mistaken anatomically nor are they likely to be confused clinically with the tumors which actually arise in the substance of the VIII$^{th}$ nerve.

It should be noted in connection with these unilateral acoustic tumors, even though they undoubtedly are related to the bilateral tumors which not infrequently occur in von Recklinghausen's disease, that no familial examples have ever been recorded nor any recognizable hereditary tendency in the direction of parental generalized neurofibromatosis. In this disease, however, there is unquestionably some fault of development on the part of the peripheral nerves, and this coupled with the fact that the histology of the cerebral nerve tumors of central neurofibromatosis is identical with that of the solitary tumors of the acusticus makes it probable that they are due to the same underlying *anlage*, which may therefore be regarded as more likely to occur in the VIII$^{th}$ than in the other cerebral nerves.*

**Effect of pregnancy.**—It has been a matter of frequent observation that brain tumors, particularly gliomas, may either arise during pregnancy or, what is more likely, their growth becomes accelerated during this state. This seems to be true also of the acoustic neuromas, and it was particularly apparent in Case V of this series—a patient whose symptoms had become latent but reappeared during a pregnancy: again two years after her first operation, when she was considered well, a second pregnancy was followed by a rapid return of symptoms. It may be noted also in Case XXX that the onset of symptoms coincided with her first pregnancy.

Similar observations have been made by others. Thus v. Leyden,[113] in connection with a case of recess tumor, suggested that under the influence of the vegetative changes which occur during pregnancy there is either a disposition for tumors to develop or a pre-existing lesion may be excited to a more rapid growth. Westphal[199] has also reported a case in which the first symptom occurred during one pregnancy, with an exacerbation of symptoms during a succeeding one. Many other examples might be cited.

* It may be pointed out that isolated fibroneuromas in the lateral recess, of the same histological nature as those arising from the acoustic nerve and giving a very similar syndrome, have been described as arising from the VII$^{th}$ nerve by Raymond, Huet and Alquier,[147] and from the IX$^{th}$ by Gierlich.[69] They must be very rare, however, and as Raymond and his collaborators make no reference to the VIII$^{th}$ in their report, some doubt must be cast on their observation.

## Incidence

**Sex.**—In this present series of 30 certified cases there happened to be 18 females and 12 males. From this one might conclude that the lesion was more common in women, although Bruns and Gowers came to believe that it is twice as frequent in men. The numbers are too small for reliable conclusions, as shown by those given by Henschen, for in his earlier dissertation[79] he assembled from the literature prior to 1910, records of 136 verified examples of solitary acoustic tumor, and in the succeeding five years, 109 additional ones. Of these 245 cases the sex was known in 225, 104 males and 121 females, showing that there is no definite predisposition to these lesions in either sex.

**Situation.**—The tumor, moreover, shows no definite predilection for the right or left side, though our small figures might suggest the contrary. In the 30 recorded cases the right acoustic chanced to be involved in 12, and the left in 18 instances, but Henschen's larger assemblage of cases shows definitely that one side is no more likely to be affected than the other, nor is there any reason to see why it should be.*

**Age.**—Of more interest and importance is the period of life at which these tumors occur. The average age of the 30 patients with the verified lesions in this series at the time of their admission was 38.1 years. The youngest patient (Case XXV) was 21, Case XV was 22, and Case XI was 23 years of age, and the two oldest patients, Cases XVII and XVIII, were both 53 years of age. However, as shown by the following table, the greatest number of cases fall in the fifth decade.

21–25 = 4
26–30 = 6
31–35 = 2
36–40 = 3
41–45 = 7
46–50 = 6
51–53 = 2

These figures, however, are of less importance than those recording the age at onset of the first symptom, which should give an approximate idea (though an imperfect one since the tumors doubtless may be present for long without giving symptoms) as to the decade in which the growth begins. Unfortunately, however, more often than otherwise the patients have no recollection or record of the time of onset of the auditory symptoms, which are stated to have been present "for many years" or "for a long time" and can only recall with some precision the time of onset of the suboccipital discomforts, the unsteady gait, the lowering of vision, or some equally distressing symptoms or combination of symptoms from which they usually date the beginning of their trouble. As recorded, however, the figures for the 30

* To show the futility of drawing conclusions from small figures, it may be stated that when these calculations were first made there were 24 cases equally divided between the sexes and also between the right and left side, but much the larger number of left lesions were in males and of right in females. The last six tumors in the series were all on the left and mostly in women.

certified cases show approximately an average onset of initial symptoms before admission of four years. The extremes are represented by Case XXV of six months, and Case IX of ten years, though Case XXIX, as may be recalled, gave a history of impaired hearing since childhood. Any attempt, therefore, to give with any exactitude the average age of onset is futile, but such as they are, the figures show that it was 34.1 years for the 27 verified cases which furnished data sufficiently dependable for this calculation.

What is chiefly significant about these figures is the fact that the symptoms of an acoustic tumor rarely occur before the third decade of life, for the earliest age from which symptoms might definitely be traced was 19 in only one case in the series (Case XI). Hence one may be justified in the conclusion that a patient under 20 with a cerebellopontile-angle syndrome in all likelihood has a lesion other than an acoustic tumor.* This rule, however, must be taken with reservations, for Henschen's tables relating to the age of onset of first symptoms in the series of 165 supposedly verified acoustic tumors show 3 cases in the first decade† and 17 in the second, whereas in the third, fourth and fifth the numbers mount rapidly to 39, 53 and 42. It of course all depends upon what one regards as "premonitory symptoms" and, as has been pointed out, our histories are necessarily imperfect in this respect.

Despite these exceptions to the rule given above, there seems to be no doubt but that patients with acoustic tumors on the average do not present themselves until a somewhat more advanced age than do those with other subtentorial lesions. In the certified tumors involving the hind brain in our Brigham Hospital series, excluding the acoustic tumors, the average age on admission was 23.2, and it may be pointed out that when cerebellar symptoms occur in the first two decades an intracerebellar tumor, more often a glioma, may be suspected.

**Expectation of life.**—It would be interesting to have some definite figures regarding (1) the average duration of auditory symptoms before signs of involvement of other structures in the recess occur, (2) the time at which general pressure disturbances indicating a ventricular hydrops may be looked for, and (3) the expectation of life in unoperated cases after the onset of these pressure symptoms, in order to compare the figures with the expectation of life when an operation has been undertaken. There can be no doubt but that with the commonly recorded mortality of 70 per cent for operations for cerebellopontile-angle tumors the average expectation of life would be greater without operation, and this Tooth[183] has shown to be apparently true of the tumor operations which formed the basis of his studies.

Figures, however, cannot record the comparative improvement in comfort of the survivors nor contrast it with the status of those in whom the tumor is

---

* It should be pointed out that this applies to isolated acoustic tumors. Individuals with generalized neurofibromatosis and wide-spread disease may have acoustic tumors, even bilateral ones, at a much earlier age, as in Berggrün's remarkable case of a child of eleven.

† For example, Druault's[52] patient was a young woman of 19, the onset of whose auditory symptoms had occurred abruptly at about 10 years of age.

allowed to run its course for a few months longer without intervention. In the only unoperated case in the series (Case XXX) the duration of life was seven months (the symptoms admittedly were very advanced at the time she came under observation). On the other hand the average duration of life, even after little more than a simple suboccipital decompression, appears to be from three to four years (e. g., Cases II and III) and may be much longer (e. g., Case IV), whereas after a partial intracapsular enucleation this period may be greatly prolonged (e. g., Cases V, VI, and XI).

A general average impression of what these patients recount, of what they show, and of what they may expect, is as follows: auditory symptoms of about four years' duration; general pressure symptoms, which have finally led to their hospital admission, of from 6 months to a year's duration; an expectation of life with increasing discomforts and blindness of from 6 months to a year without operation: an expectation of life with vision preserved and relatively free from discomforts, averaging from 3 to 4 years after a simple wide decompression: and from 5 years upward if a more or less thorough enucleation is successfully performed. This is merely an impression gained by past experiences: it is hoped that it may be greatly modified for the better by future ones.

## Summary

Acoustic tumors apparently arise from embryonic tissue rests in the peripheral end of the nerve and their growth may possibly be influenced by such elements as trauma, local infection, or pregnancy. From the present series they appear to be somewhat more common in women and more often on the left side. The average age of onset has been 34 years; hospital admission and operation on the average date four years later.

## CHAPTER VI

## SYMPTOMATOLOGY

The chronology of symptoms in the foregoing series of cases makes it clear that the clinical diagnosis of an acoustic tumor can be made with reasonable assurance only when auditory manifestations definitely precede the evidences of involvement of other structures in the cerebellopontile angle. This is characteristic of so large a percentage of the clinical histories that the exceptions (e. g., Cases XXII, XXV and XXX) merely serve to make it the more striking. Hence when the inaugural symptoms of a growth, obviously situated in the angle, have another sequence with secondary acoustic symptoms, the diagnosis must remain uncertain until the lesion is exposed.*

The significance of this does not seem to have been heretofore sufficiently emphasized, nor was it appreciated when the study of these cases was first undertaken, and it must be confessed that in most of the clinical histories the fact was hidden in a mass of symptomatic details, while in others it has only been brought to light by subsequent inquiries directed toward this particular matter.

It would appear that patients rarely call attention to the premonitory auditory symptoms, which are either forgotten or are not associated with the subsequent and more incapacitating phenomena, and it is equally certain that the sequence is apt to be slighted by the questioner. Jumentié,[92] for example, states that auditory troubles in most cases are the first to occur and may long be the only indication of the affection, and yet no indication of the fact occurs in the history of any of his eight certified cases. On the other hand, a progressive unilateral loss of hearing, if unattended by tinnitus, may not be observed by the patient, and it is interesting to note how often, when it is observed, attention is called to the fact by disability in the use of the telephone (*cf.* Cases XX, XXIV, XXV and XXVIII).

It is rare for the VIII$^{th}$ nerve to be the only one affected by the time these patients present themselves in a neurological clinic, but Table 4 (p. 162) shows that this was true of two cases in the series (Cases X and XX), and practically so in two others (Cases XVI and XVII), not even the corneal

---

* These statements may be a little extreme, for there are many authentic case histories in which the acoustic symptoms were unquestionably late in appearance. The matter was emphasized by Sorgo[167] in the discussion of his case. Doubtless a tumor which arises in the free course of the nerve may reach a size sufficient to produce local symptoms without affecting the conductivity of the fibres of the nerve itself. A neuroma of a peripheral nerve may similarly leave the nerve fibres for long unimpaired.

reflex on the side of the lesion being impaired. A distinctive feature, moreover, of the auditory phenomena in these cases lies in their uninterrupted progress from the first signs of irritation of the nerve to the stage of paralysis or near paralysis, and in this respect the symptoms referable to the acusticus differ essentially from the other cerebellopontile-angle symptoms, which, as will be pointed out, are characteristically variable in their intensity or even actually fugitive.

It is fitting, therefore, that the acusticus should first engage our attention and that the symptoms referable to other adjacent structures be taken up subsequently, so far as possible, in the order of their occurrence.

## The Auditory and Labyrinthine Symptoms

**The N. cochlearis.**—In twenty-five out of the thirty* cases the inaugural symptoms were auditory, varying from a recorded period since childhood (?) in one instance (Case XXIX), of ten years (Case IX), of nine years (Case IV) and of seven years (Case XIII) at one extreme, to a few months before the patient's admission at the other. In view of this predominant number of positive cases it is quite probable that had the matter been pursued in some of the earlier cases which stand as exceptions to the rule (e. g., Cases VII and XI), a primary history of auditory symptoms might have been elicited.

Individuals differ greatly in their ability to recall the order of onset of their early symptoms, particularly when they are of long duration, and this is accentuated, of course, when their faculties have become dulled by a secondary hydrocephalus. Thus in Case XVII the fact was subsequently elicited from the patient's wife that for two years before the onset of his deafness he had often been kept awake at night by a buzzing in his ears; this he had completely forgotten when his history was first taken. However, in Case XXIII, according to the patient's recollection there was no definite priority in the disturbance of hearing over some of the other symptoms; the literature contains many cases with a similar history and we must accept the fact that the acoustic symptoms may long remain latent. Case XXII remains the single unquestioned example of secondary rather than inaugural auditory manifestations, but the unusual features possessed by the growth readily explain why it should be an exception to the general rule.

Tinnitus of one form or another and variously likened to a ringing or buzzing or roaring, and from the faint sound of a sea shell to the rush of a train, usually preceded the onset of deafness. In a few cases, however (e. g., Cases X, XX and XXIX), no history of tinnitus was volunteered or elicited, though it may of course have occurred, and in one or two cases (e. g.,

---

* Inasmuch as the diagnosis in Cases XXXI to XXXIII, which have been given as types of presumable though unverified examples of acoustic tumor, has been based largely on our studies of the symptomatology of the verified cases, they will be excluded from the figure percentages in this chapter. It goes without saying that the chronology of the symptoms is more or less similar in the other thirty-two unverified cases in the series, not included in this report.

Case VIII) it was a late symptom.* Indeed in some instances the loss of hearing on the affected side was an accidental finding not preceded by any noises (e. g., Case XX); in one or two other instances complete deafness was of sudden occurrence (e. g., Case XXVI) without premonitory symptoms, whereas in still another patient (Case X) there was antecedent pain in the ear (trigeminal?), and deafness without preceding tinnitus was of abrupt onset. Similar observations have been made by others. Thus in Meyer's case[123] there was abrupt loss of hearing following an attack of dizziness.

Occasionally, as in Case VIII, tinnitus has persisted even when there appeared to be complete loss of air conduction, and in one or two instances when it has been late in onset (e. g., Case XIII) the noises were referred to the contralateral ear. Indeed in seven cases, as can be seen from the table (p. 162) the tinnitus has actually been bilateral or at least subjectively referred to both ears.

All of these case histories, as may be emphasized, record the examinations made by at least two and often by three or four observers and, what is more, when there has been any uncertainty or confusion regarding certain symptoms the tests have always been repeated on subsequent examination. In reviewing the records it has been of interest to find that the first observer in going over the cerebral nerves has sometimes been confused regarding the question of deafness, and in a number of the patients it was thought that bone conduction was present and, in some instances, air conduction also, when both were subsequently disproved. The absence of the latter, indeed, has only been absolutely certified in some patients by the complete deafness to external sounds which ensues when the unaffected ear is being irrigated in the course of the caloric tests. As Grey[75] points out, the perception of after tones and the transmission of tones of the fork to the opposite ear somewhat interfere with the Rinné test and not infrequently, even with acoustic tumors of large size, the tones perceived by the unaffected ear are referred by the patient in part to the diseased side.

All of this goes to show that absolute deafness is almost as difficult to certify as an absolute loss of the vestibular reactions in these cases. It is true that the majority of patients in the series by the time of their admission appeared to have a complete acoustic paralysis. But this was not true of all, for about seven of the patients showed either some preservation of hearing for certain tones of the Galton whistle or the fork or even of the voice (*cf.* Case XXIX) and in a somewhat smaller number labyrinthine responses to caloric tests were retained. This suggests that a complete vestibular paralysis is more frequent than a complete cochlear one, which is in line with Henschen's view that these tumors arise more often from the vestibular nerve. The tabulation of symptoms shows, however, that when some auditory function is retained, some labyrinthine responses can usually be elicited (Cases XXI, XXVIII and XXIX). Only in one case (Case XVI) was there incom-

* It is notable that Toynbee's early case, which was apparently an accidental post-mortem finding, though this is not stated, had a history of a slowly progressive loss of hearing of twenty years' duration, unaccompanied by any noises in the ears.

plete deafness with loss of labyrinthine responses, whereas the reverse was apparently true in Case VIII, though this patient was observed when we were comparatively unfamiliar with the labyrinthine reactions.

It should be noted in this connection that a considerable number of the patients who were completely deaf before, regained some hearing after operation (e. g., Cases V, XV, XX and XXVI). It is my impression that a return of function in the vestibular nerve is less likely to occur (e. g., Case XXVI), though in one instance (Case XXII) normal auditory and labyrinthine responses for the time being have been completely restored. This all goes to show that intact fibres may still traverse these tumors or, what is more likely in view of the character of the operations performed, be incorporated in or near the capsule and regain some measure of their functional activity when released from tension. The fact, too, that nerve fibres, supposed by some to be newly formed fibres, are occasionally encountered in histological preparations from these growths is thus accounted for. This explanation has also been regarded as probable by Alexander[4] on the basis of the very early tumor which he had the opportunity of studying, and was particularly well shown in the case reported with Frankl-Hochwart.[5]

In one of our more recent operations (Case XXVI) upon a comparatively young tumor, a small bundle of fibres could be seen passing from the meatus over the surface, but they must have been functionally blocked, for deafness was complete. An interesting observation was made by Biggs[25] on a case with verified bilateral acoustic tumors which were of quite unequal size; the larger tumor occupied the side on which some hearing had been retained.

**The N. vestibularis.**—With all of this emphasis which has been laid upon inaugural auditory manifestations it must not be overlooked that there are two divisions of the nerve and that the radix vestibularis may be primarily involved, so that symptoms on the part of the labyrinthine apparatus often precede any disturbances of hearing. Reference has already been made to Henschen's view that the vestibular branch is the one more apt to be the primary seat of the lesion, and examples of acoustic tumor have been observed in which the cochlearis was functionally and anatomically unimpaired (Mayer[120]). This being so, one would expect a history of vertiginous attacks to be frequently recorded among the initial symptoms.

Though a sensation of giddiness, usually relieved by recumbency, is not uncommon, in only one patient (Case IV) was the early history so definitely associated with attacks of vertigo and falling as to lead to the diagnosis of Ménière's disease (*cf.* also Case XXXIII). Several examples of this, however, occur in the literature (e. g., Sharkey,[163] Frankl-Hochwart,[61] Fraenkl and Hunt[59]).

It is difficult, sometimes impossible, to tell whether the forms of nystagmus, vertigo and ataxia which the patient exhibits are to be ascribed to labyrinthine or cerebellar involvement. This has been fully and ably discussed in the papers by Wilson and Pike.[202, 203] As a matter of fact, we have had no opportunity of studying cases at an early stage of the

lesion, and by the time they have come under observation the growth has enlarged sufficiently to deform the cerebellum so that there must be more or less fusion of symptoms from the two sources, leading to confusion as to their seat of origin. Consequently we must depend largely upon the patient's history, and in some instances there seems to have been an inaugural period possibly of pure labyrinthine symptoms.

On this basis one might possibly account for the unusual chronology of symptoms in Case V, for the patient recalled an antecedent period of local symptoms with an unsteadiness of gait possibly due to a disturbance of equilibrium of vestibular origin, though nystagmus was not recorded: this had completely subsided for a year or so before the onset of what was regarded as her "present illness," inaugurated by tinnitus.

As indicated by the case reports, we have included nystagmus under the cerebellar symptoms, though it is quite possible that the two varieties of nystagmus on the basis of origin may be distinguished. However, that case, in our series of recess tumors, in which we felt most confident that the symptoms of vertigo, nystagmus and instability were largely vestibular in origin, proved to be one not of an acoustic tumor but a meningeal endothelioma with extensive cerebellar deformation and merely a pressure involvement of the VIII$^{th}$ nerve (*cf.* Case XXXIV) so that we were utterly misled.

Though detailed studies of nystagmus in these cases and the attempt to determine whether the symptom is due to vestibular irritation or destruction, or to an involvement of the pontile or cerebellar connections through Deiter's nucleus, or wherever they may lie, are of great physiological interest and in time may come to be of great diagnostic value, the subject is still greatly tangled. In its clinical adaptation we must rely at present on the single fact that in most of these cases the nystagmus in a horizontal direction presents excursions which are wider, slower, and more pronounced on looking toward the side of the lesion than toward the other. This is the case regardless of whether the vestibular apparatus is still capable of responding to caloric tests.

Vertigo of the type described by Stewart and Holmes, accompanied by subjective rotary displacement of self or of objects, has been sufficiently definite to be noted in very few cases (e. g., Case XXIII), and it is quite possible that the matter was insufficiently inquired into in the earlier clinical histories. Stimulation experiments of the labyrinth have shown that the apparent rotation of self is always in the direction of the rapid phase of nystagmus and this is usually away from the lesion in recess tumors. On the other hand, the apparent rotation of objects, according to Wilson and Pike, is less definite, though in the one case in our series in which the sensation was distinct (Case XXXIV: a recess endothelioma) the subjective revolution of objects occurred toward the side of the lesion—namely, toward the side of the coarser nystagmus.

There is difference of opinion on this subject, even in the interpretation of the field oscillations which accompany the dizziness following rotation in the Bárány chair. It may be noted that these patients commonly find that

lying on the sound side relieves their vertigo, whereas it is increased by turning on the affected side.

As is the case with nystagmus, it is often difficult or impossible to tell whether the dizziness or vertiginous sensation which these patients experience is of labyrinthine, cerebellar or of combined origin. It should be noted that vertigo may be present even when the vestibular nerve is destroyed, or at least gives no responses to caloric stimuli and, what is more, vertigo, dizziness and nystagmus may all for a time be very greatly increased by the operative manipulations of the cerebellum incidental to the exposure of the growth.

The caloric tests in these patients by the time of their admission have shown a great lowering of vestibular irritability, though, as already stated, some reactions were observed in four cases (e. g., Case XXIX), indicating that the conducting path is not necessarily destroyed even in large tumors. This is contrary to Bárány's experience,[17] for he has stated that he has never obtained caloric responses in the examination of more than thirty cases, whereas some hearing might be preserved.

**Dilatation of the porus acusticus internus.**—As pointed out in the historical notes, a dilatation of the internal auditory meatus, with more or less pressure absorption of the adjacent pyramidal bone, has been frequently recorded in the autopsy reports of these cases—in fact, more often than not—since the time of Cruveilhier and Weiglein. Unfortunately in the fatal cases of this present series a thorough examination of the petrous bone at autopsy has never been made, though some of the tumors (*cf.* Figs. 4, 66, 167, 196) clearly show where the stalk of the tumor projecting from the canal has been torn across during the removal of the brain. It remained for Henschen to point out that the growth often originates from that portion of the nerve which lies within the canal, and he first suggested and later demonstrated that the distended internal meatus or porus could be shown by the X-ray.[80] He thus aroused the hope that this might prove to be of essential aid to the diagnosis, and though in four of the cases of this series, as we have seen, X-ray studies have possibly shown such a dilatation, unhappily in those in which it would be of other than corroborative value no enlargement could be demonstrated. Indeed in one patient with a suspected recess tumor a relatively dilated porus acusticus internus was observed on the side contralateral to the symptoms, and in one of the cases in Henschen's later report[81] (Fall XXXII) the same thing was observed.

During the preparation of this report misgivings arose as to the reliability of our earlier X-ray reports, and on a careful review of the Röntgenograms it was found that in some of them the outline of the porus acusticus externus (Figs. 228, 229) rather than of the internal canal had been reported upon.* Owing to this disclosure renewed studies have been made of all the available patients in the series who are living with certified lesions, and Dr. Grey and Dr. Carr developed a fairly exact method whereby the canals could be clearly

---

* It is possible that others may in the past have fallen into this same error in reading their plates. Although undoubtedly Henschen must refer to the internal canal and not to the external, nevertheless in the X-ray prints which accompany his article it is the external and not the internal porus which appears to be represented as being dilated. The same appears to be true of the print of one of Josefson's[81] cases.

projected on the plates (*cf.* Fig. 177) and the two sides compared. It has been disappointing, however, to find that, even in advanced cases, there is apt to be little demonstrable difference between the pori interni of the affected and unaffected side. This is remarkable in view of two things: one, that the tumors, whether or not they arise within the canal, certainly in the course of time come to project therein, and the other, that slowly growing benign tumors commonly cause pressure absorption of adjacent bone. A dilated porus would therefore be expected more often than it really occurs or is capable of radiographic demonstration, though this may merely be an acknowledgment of the present imperfections in our methods of detecting the lesion.

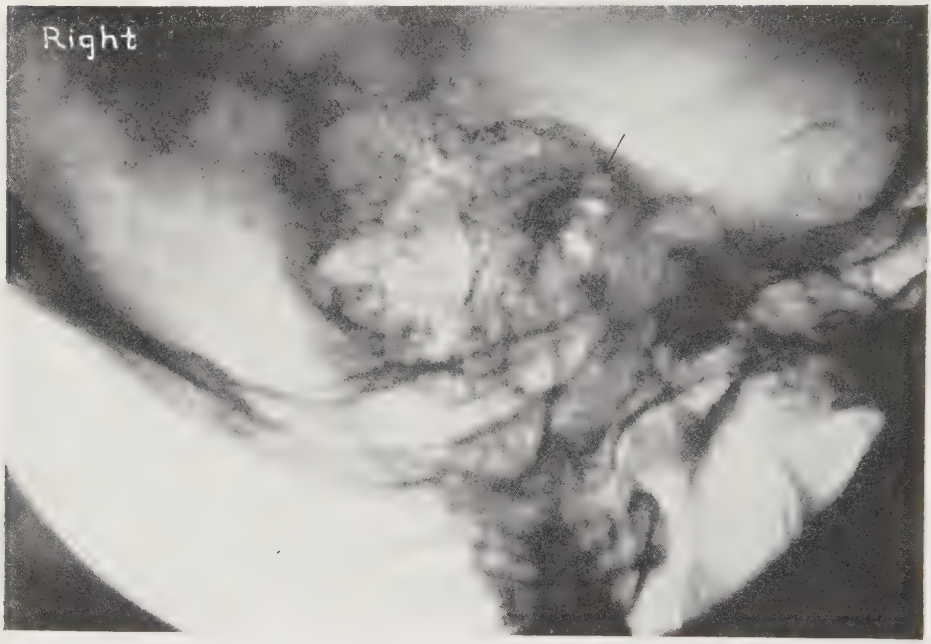


Fig. 177.—Showing print of a normal right porus acusticus internus (arrow) properly projected.

Careful notes upon the porus acusticus occur in the X-ray reports on most of the twenty cases composing the Boston series. Of these only four (Cases XVIII, XIX, XXV and XXVII) showed what was interpreted as a definite enlargement and in these four in only one (e. g., Case XVIII) was it at all notable. In many of these cases repeated plates were taken before satisfactory exposures were obtained, and in three of them the assurance of a demonstrably enlarged porus was secured only from exposures taken after the operation with certification of the lesion. As can be seen from the tabulation, there were six other cases in the twenty in which there was a suspicion of some change in the porus, shown more as a lack of distinctness in outline on the affected side than as a definite widening of the canal.

Doubtless further experience will greatly increase the value of this sign,* but even when the method of detecting it is perfected, it can only be of considerable diagnostic importance under the rare circumstance of a unilateral acoustic tumor with bilateral manifestations, as in Case XXX of the series. To this we shall return in the chapter on diagnosis.

---

The symptoms which follow the acoustic manifestations are a little less definite in their chronology, and indeed in a number of cases (e. g., Case XXIII) giddiness, unsteadiness of gait, and intracranial discomforts have more or less coincided with the primary signs of auditory derangement. Whether the early uncertainty of gait and station, recorded in some instances (e. g., Case V), should be ascribed to an involvement of the vestibular nerve or of the cerebellum is not clear.

From the history alone labyrinthine and cerebellar symptoms are difficult to distinguish, and it is a common practice to attribute all forms of motor incoördination to an involvement of the cerebellum, which would necessarily imply a growth sufficiently large to project far into the recess. A growth of inconsiderable size, however, seems to be capable of producing discomforts, which after a varying period subsequent to the onset of auditory disturbances usually begin to appear.

### Suboccipital Discomforts

Though a diffuse, unlocalizable cephalalgia may occur, the early discomforts from which the majority of these patients suffer are less often described as headaches than as paroxysmal pain, more often on the side of the lesion, sometimes frontal, sometimes occipital, but apt to spread from back to front, or occasionally in the reverse direction (e. g., Case XXIV), and a more or less severe boring retro-orbital pain is often complained of.

There is apt to be some soreness and stiffness in the neck on stooping and straining; coughing or sneezing may bring on a paroxysm of pain. These discomforts are often more troublesome at night or in the morning hours and may wear away later in the day, much as may the pain or discomforts which accompany spinal cord tumors.

Just what these discomforts may be due to is difficult to say. They may possibly be produced by pressure against the tentorium and thus be in part of trigeminal origin, but they do not have the characteristics of occipital neuralgia, though often regarded and treated as such early in the course of the disease. A trigeminal origin would not account for their suboccipital distribution and, as a matter of fact, paræsthesias rather than pain characterize the direct involvement of the N. trigeminus by pressure of the tumor, as we shall see.

As the growth enlarges, these discomforts may become greatly exaggerated,

---

* Since these paragraphs were written we have greatly perfected our methods of detecting slight absorption changes in the outline of the affected porus, though it necessitates the careful comparison of stereoscopic plates of both sides (*cf.* p. 237).

with extreme tenderness of the suboccipital muscles, usually on the side of the lesion and leading to a protective tilting of the head, in which the mastoid is usually drawn down toward the shoulder (*cf.* Fig. 64).* Often a definite muscle spasm occurs in resistance to a passive flexion of the neck.

### The Cerebellar Symptoms

In the average case, in a year or so after the acoustic symptoms first appear, evidences of cerebellar incoördination become apparent, due undoubtedly to pressure by the tumor against the region of the flocculus, with distortion of the cerebellar hemisphere and its peduncles and consequent involvement of the cerebellolabyrinthine as well as the spinocerebellar paths. By this time the tumor has of course reached a sufficient size to elongate the adjacent cerebral nerves, but it is apparent from the case histories that pronounced cerebellar symptoms may be present with but slight symptomatic evidence of cerebral nerve (other than the acoustic) involvement (*cf.* Cases XVI and XXIX) or, indeed, with no objective signs of their involvement whatsoever (e. g., Cases X and XX). On the other hand, it must not be overlooked that pronounced cerebral nerve involvement may be present with cerebellar symptoms, even the nystagmus, practically absent (e. g., Cases VII and XXVII).

As already stated, it is not always possible to tell from the history alone whether the early periods of staggering are of labyrinthine or cerebellar origin, and inasmuch as none of these patients were subjected to labyrinthine tests early in the course of the disease the matter must remain unsettled. Unfortunately, inasmuch as they have been accidental postmortem findings, the clinical histories of the few examples of small acoustic tumors are imperfect, but in none of them, so far as I can gather, were there any symptoms which could have been confused with true cerebellar ataxia.

The first symptom to be noted is usually the unsteadiness of gait, which may vary all the way from a drunken reeling to a slight tendency to fall on turning. It is notable that this cerebellar incoördination (ataxia, dysmetria) which is homolateral to the lesion and is often associated with a distinct loss of power or tone in the muscles, is apt to affect the lower extremities—and therefore the gait and station—more noticeably than the upper extremities, for though some tremor and a tendency to drop objects from the hand on the side of the lesion may be noted, the upper limb type of ataxia is much less outspoken than is seen in the majority of patients suffering from intracerebellar lesions.

The difficulties and uncertainties of gait and station exhibited by these patients vary greatly from day to day, as the histories of these cases bear abundant testimony. In some cases in the series, even though the extracerebellar symptoms were outspoken, there was but slight instability, and in

* This cerebellar posture has been ascribed by Starr[173] to a disturbance of position due to the weight of the tumor, an explanation which can hardly be the correct one. But, whatever may be its cause, the sign is not a particularly valuable one.

Case X practically none at all: others have managed to pitch and stagger and reel along on a broad base with their feet wide apart: while in a few instances the incoördination had become so pronounced that the patients were completely bedridden (e. g., Cases II, III and IV).

Though some have expressed a contrary opinion it is my impression, in accord, among others, with Stewart and Holmes,[177] who have given a detailed description of the gait of these patients, that when station is disturbed, as shown by the Romberg and other tests, there is a distinct tendency to fall to the side of the lesion, and in progression to deviate toward the same side. This, however, was not uniform throughout the series, and indeed the direction of falling may actually vary from time to time in the same patient. As a rule, even when incoördination is slight, these persons find it much more difficult to balance on the foot of the affected than on the other side when attempting to stand on one foot alone.

These signs are of course all merely an expression of imperfect cerebellar control over the coördinate movements of the homolateral side of the body, the *hémiasynergie cérébelleuse* of Babinski.[12] The disturbance is often accompanied by a sense of unilateral weakness, by incoördination with more or less marked dysmetria and, as Babinski pointed out, there is often an impaired ability to perform rapid movements (adiadococinesia). None of these symptoms, however, can be regarded as characteristic of acoustic tumors in distinction from other lesions involving chiefly one cerebellar hemisphere.

*Nystagmus.* The question of differentiation of vestibular and cerebellar nystagmus has already been touched upon under the acoustic symptoms. Though it is quite possible that the two types may be clinically distinguishable, in our case reports from the outset all forms have been incorporated with the cerebellar manifestations. Wilson and Pike[203] are emphatic in stating that cerebellar nystagmus is essentially ataxic with oscillatory features due to the asynergia which affects the general musculature, and to this I would in general agree, but as these authors admit, "so many cerebellar lesions are complicated by pressure on the vestibular nerve . . . . the most careful observations leave us often hopelessly involved." According to Mills and Weisenburg,[125] the two forms may be so much alike that a decision between them can only be determined by a thorough study of the general features of each case.

Whatever its cause may be, nystagmus is not a symptom of which the patient is aware, so that its onset is not recorded. Owing to the early involvement of the vestibular nerve it is probably an early symptom and certainly, even when of cerebellar origin, will antedate all other evidences of cerebellar motor incoördination or at least, being easily observed, it can be detected when a disturbance of the trunk or limb musculature may escape our rough methods of investigation. In a few cases (e. g., Case X) it was the only recorded cerebellar manifestation, and in Case XXVII even the nystagmus was practically wanting. This observation, taken in conjunction with the fact that the nystagmus is almost always greatly increased by the cerebellar manipulations incidental to exposure of the recess, makes me feel that the nystagmus in these cases is of cerebellar rather than of vestibular origin.

The slow component or phase of the jerk is commonly toward the side of the lesion, but a more usual and useful observation, noted also by many others, is that the oscillations are slower with the eyes turned to the affected than to the unaffected side. In a number of cases a vertical nystagmus on looking upward was recorded, but this was usually combined with rotary oscillations and has, as yet, no diagnostic significance.

The apparent rotation of self or of objects, on which Stewart and Holmes[177] dwelt at length in their paper, as already mentioned under the topic of "vertigo," has been infrequent in this series of examinations and I do not believe that it can be sufficiently common to be of especial diagnostic service. Even when carefully inquired into, an account of the sensation is not easily elicited and but few patients (e. g., Case XXI) recalled the feeling. In but few cases in the series was the sensation at all definite. In Case XXVI there was an up-and-down movement of objects: while in Cases XXIII and XXXIV (the latter an extracerebellar but not an acoustic tumor) objects during dizzy periods were described as swinging toward the side of the lesion. In Case VIII the sensation occurred only under the unusual circumstance of the patient's turning the head away from the side of the lesion and happening at the same time to turn his eyes in the opposite direction—namely, toward the affected side. This combination of movements would aggravate his nystagmus and produce the sensation of objects revolving or sweeping past him apparently in the direction he was looking, but even then he was not entirely sure of this.

## The Adjacent Cerebral Nerve Symptoms

The cerebral nerves adjacent to the VIII$^{th}$ begin to show signs of involvement in varying degree at variable periods, but, as already pointed out, one or two patients in this series (e. g., Cases X and XX) showed no signs of cerebral nerve involvement apart from the acoustic, whereas at the time of admission some cerebellar signs were present in all, though admittedly in Cases VII and XXVII they were inconspicuous. For the sake of convenience in following these nerve symptoms, the accompanying table has been prepared.

Unlike the auditory phenomena, the symptomatic disturbances of these other nerves tend to fluctuate in their intensity. In most patients, by the time of their hospital admission, the V$^{th}$, the VI$^{th}$ and the VII$^{th}$ are apt to have given subjective evidences of involvement, as related in the patient's history, or to be objectively affected. The involvement of the homolateral nerves adjacent to the growth is a matter of their local compression or distortion, but it must not be forgotten that irritation or palsy of contralateral nerves may occur and give misleading and distant symptoms. In at least fourteen out of the thirty cases (*cf.* Table 4) some subjective or objective contralateral involvement was noted, most often of the V$^{th}$ and VIII$^{th}$ nerves, as numbness and tinnitus. Case XXX is a remarkable example of contralateral symptoms so wide-spread as to have led to the diagnosis of a bilateral lesion.

Many hypotheses have been offered in explanation of these contra-

TABLE 4.

| Case Number. | Homolateral Cerebral Nerve Involvement. | | |

lateral palsies, such as displacement of the pons and medulla by a dislocated cerebellar lobe (Spiller), or pressure of the nerves against the sharp edge of the dura at their point of emergence (Wernicke) or pressure of the pons and medulla against the base of the skull on the opposite side (Grey). None of them are entirely satisfying, and as a matter of probability, the different nerves may be affected in different ways. In the case of the V$^{th}$, for example, there must be a sharp angulation of the root (*cf.* Fig. 178) at its point of entry into its tentorial foramen. In the chapter on diagnosis reference will be made to a case in which the contralateral cerebral nerve symptoms, produced by a meningeal endothelioma involving the left cerebellar hemisphere, were so pronounced as to lead to the diagnosis of a right cerebellopontile-angle tumor. Henschen reports a similar experience.

**The N. oculomotorius.**—It is unusual for the III$^{rd}$ nerve to be affected, and though in one or two cases in the series skew deviation (*cf.* Cases XIV and XV) had been observed, it was not until Case XXX was seen and the lesion certified that the possibility of impairment of the III$^{rd}$ was fully appreciated. This, as in the case of the abducentes, I am inclined to ascribe to a kinking or vascular constriction rather than to any possible direct pressure by the tumor. As in the case of the contralateral symptoms, there is no entirely satisfying mechanical explanation for these oculomotor palsies.

**The N. trigeminus.**—Next to the acoustic this is probably the first cerebral nerve of whose involvement the patient is subjectively conscious, for slight paræsthesias attract attention, whereas a slight facial weakness is not likely to be noticed. The sensation is usually described as a feeling of numbness, tingling or of burning, more commonly limited to the face but often involving the entire trigeminal territory, both skin and mucous membrane. The symptom, as would be expected, is more commonly homolateral (18 cases), occasionally bilateral (5 cases) and rarely contralateral (Case XXVIII).

Some subjective sensations of this kind, more or less fugitive in character, were described as having occurred by about half of the thirty patients, though at the time of admission in some of them (e. g., Case XVII) there was no demonstrable objective lowering of sensitivity even of the cornea. On the other hand, it is of interest that in three patients (Cases XIII, XV and XXII) —and there may possibly have been others among the earlier cases—a definite hypæsthesia of skin or of skin and mucous membranes was objectively demonstrated when there had been no previous history of subjective paræsthesias.

The most delicate objective evidence of a trigeminal involvement is unquestionably the lowering of or the loss of the corneal reflex (hyporeflexa and areflexa cornealis of Oppenheim) on the affected side, and a normal corneal sensitivity was retained in only four of the thirty patients in whom the condition was carefully noted on the history; two of them (Cases X and XX) being the cases in which the acusticus was the only involved nerve.

Attention should be drawn to the fact, however, that in a few patients (Case V on her first admission, Cases XI, XXV, XXVIII and XXIX) the loss of corneal reflex was the only demonstrable evidence of trigeminal involvement. Though not of so great significance, therefore, as Oppenheim would lead one to believe, the sign may nevertheless be of premonitory value: this was true of Case XXIX,

the only one in the series in which a corneal areflexa was the only cerebral nerve symptom apart from those of the acoustic itself. Another patient (Case VIII) gave a history of bilateral trigeminal paræsthesias, but at the time of his first examination no objective hypæsthesia of face or mucous membranes apart from a bilateral corneal areflexa was demonstrable. Of the four other patients (Cases IV, XIX, XXIII and XXX) who also gave a history of bilateral paræsthesias, three showed a bilateral corneal areflexa, but there were other nerve symptoms which overshadowed the corneal reflex in importance.

There is one other reflex, the loss of which has been observed in a number of cases—namely, a palatal reflex on the side of the lesion, and it may be added that the palate itself is apt to be a little lax on the homolateral side, whether from a trigeminal, facial or glossopharyngeal involvement is not quite clear.

*Trigeminal pain.* One striking thing is notable in relation to all of these cerebral nerve symptoms—namely, that paralytic phenomena rather than irritative are dominant. In the case of the trigeminus, though the paræsthesias may be regarded as excitatory, neuralgic pain such as one would expect is relatively uncommon. This is the more remarkable when one realizes how flattened and elongated the nerve becomes as it is crowded aside by the growth.

Slight neuralgic discomforts were complained of in but a few cases. In Case I there was a history of contralateral infraorbital pain. In Case VIII also there were neuralgic pains referred to the lower jaw on the opposite side; in Case XIX to the face and tongue on both sides; in Case X to the ear on the same side. In none of these patients were the discomforts at all distinctive of trigeminal neuralgia of the major type.

It is said, however, that a cerebellopontile tumor is capable of producing paroxysms of such a character that they have been mistaken for tic douloureux and oft-quoted examples have been recorded by Krause,[102] by Lexer,[112] and Weisenburg.[196] The tumor in Krause's case was a cholesteatoma of the angle, in Lexer's case a psammoma (apparently arising from the trigeminal sheath, since the VII$^{th}$ and VIII$^{th}$ nerves were displaced below the growth), neither of them, therefore, primary acoustic tumors. I feel some doubt, moreover, as to the diagnosis in Weisenburg's case, for one would have expected deafness had the lesion originated from the VIII$^{th}$ nerve.

These cases, therefore, merely serve to emphasize the fact that, though major trigeminal neuralgia may accompany or be produced by a cerebellopontile-angle tumor, it is rarely if ever a significant symptom of an acoustic neuroma. Furthermore, in true tic douloureux, unmodified by operation, there is no cutaneous hypæsthesia, whereas in the painful neuralgia from pressure of a tumor some sensory loss is demonstrable, and the conditions may thus be easily distinguished.

Examples of neurotrophic keratitis, it may be added, though of rare occurrence, have nevertheless been recorded (e. g., Alquier and Klarfeld,[9] Babinski[11]) in association with recess tumors, and this never occurs in true trigeminal neuralgia except as the result of the loss of sensitivity of the cornea following a neurectomy.

One additional point of interest in connection with the trigeminus is the post-operative herpes (e. g., Cases XVII, XVIII and XXIX) which may follow the tumor manipulations, just as after a sensory root avulsion for major trigeminal neuralgia, herpetic eruptions are apt to occur about the lips or nose on the side of the operation. No example, however, of preoperative herpes has been noted in the series.

The motor division of the trigeminus, in cases in which the nerve is seriously involved, may be sufficiently affected to cause a definite weakness or paralysis of the masticatory muscles, shown most characteristically as a deviation of the jaw toward the affected side. It was observed in twelve patients (*cf.* Table 4), always in conjunction with marked sensory impairment. The deflection of the jaw is of some importance in relation to the deviation of the tongue, which will be mentioned in its place.

**The N. abducens.**—Twenty of the thirty patients gave a history of double vision, sometimes fugitive, sometimes persistent, and in eleven of the twenty an objective weakness of the abducens on the side of the tumor was present on admission. There was one patient (Case XIV) in whom an abducens weakness was practically the only homolateral cerebral nerve symptom in addition to the deafness.

It seems improbable that the abducens is ever directly pressed upon by the tumor, no matter how much it may flatten the pons, for the VI$^{th}$ nerve lies so near the median line that it would be displaced with the pons (*cf.* Fig. 196), and I believe that a strangulation of the nerve by an overlying vessel, as I have described in connection with cerebellar tumors of other sorts,[44] is the more probable explanation. The fluctuating character of the diplopia and the fact that it usually disappears after operation, whereas the palsies of the nerves which are definitely compressed by the growth are apt to persist, also speak in favor of this view. Then, too, in Cases XIX, XXVII and XXX there was a bilateral involvement of the abducentes, which could hardly have been due to the unilateral pressure of the growth.

A weakness of conjugate lateral movement toward the side of the lesion has been noted by many (Bruns, Bruce, Oppenheim, Stewart and Holmes) and poorly sustained ocular movements in this direction have been observed in many cases in this series. It may either be associated with an abducens weakness or with the nystagmus. When, therefore, secondary atrophy has led to blindness the eyes at rest are said to be deviated toward the side opposite to the growth, though as Bruce[35] has pointed out, this depends upon the presence or absence of irritative lesions of Deiter's nucleus. The matter is of physiological interest rather than of any diagnostic value.

**The N. facialis.**—In nineteen of the thirty patients some degree of facial weakness was present at the time of admission, a percentage of cases slightly lower than that which records some degree of objective trigeminal involvement as indicated by a relative corneal insensitiveness. In only one patient (Case XVI) was an accompanying areflexa unelicited—that is, only one patient showed a facial weakness without evidence

of a coincident disturbance of the V$^{th}$ nerve. On the other hand only two patients (Cases VII and XXIV) showed an objective numbness of the face without coincident facial weakness.

In the majority of the cases the paresis was little more than an inconspicuous asymmetry shown in the lower facial muscles—a planing out of the nasolabial fold apparent only during expressional movements but without any apparent loss of strength or symmetry on forced movements. This is remarkable in view of the fact that the nerve must often be pressed upon within the canal, and it is quite possible that the degree of facial paralysis may depend upon whether the lesion originates from the nerve within the canal or proximal to it.

The nerve may be elongated in its course to an amazing degree without producing any palsy whatsoever. It normally should measure only about 10 mm., but in Case XV (*cf.* Fig. 196), for example, it was 50 mm. in length and though flattened to almost paper thinness, the patient showed but very slight expressional weakness of the lower face. Though examples of complete paralysis showing the reaction of degeneration have been recorded (e. g., Bielschowsky's case[22]), no case even approaching it occurred in this series.* The surgical experiences, however, show how easily a paralysis may be produced by the operative trauma incidental to an intracapsular enucleation (*cf.* Cases XVI, XVII and XXIX) and an attempted total extirpation is almost certain to produce a complete and lasting injury of the nerve, as many operators have learned to their distress.

Irritative symptoms referable to the facial have been more frequently recorded than is generally supposed. Stewart and Holmes[177] mention them as possible though inconspicuous symptoms. They were described, we may recall, by Cruveilhier (*cf.* p. 6) as conspicuous features of his case, and in 1865 Hughlings Jackson[89] noted contralateral attacks of facial spasm which he had difficulty in accounting for. They occurred in Brückner's,[36] Sorgo's,[167] and in Alexander and Frankl-Hochwart's[5] patients; two examples are cited by Mills and Weisenburg,[125] and some slight facial twitching was present in three patients (Cases XIX, XXIII and XXVI) in this series, in one of them (Case XXIII) on both sides of the face.

In another case, however (Case XXII), the most extreme type of spasmodic facial tic occurred and, what is more unusual, it was the first recorded symptom. The tumor was of an unusual type, with especially pronounced gliomatous elements, and the presumption is that it arose from the proximal portion of the nerve, which may possibly account for the unusual chronology of the symptoms and the early and unusual type of irritation of the VII$^{th}$ nerve, if indeed this was not a coincidental affection. A mistaken diagnosis of Jacksonian fits had been made, and in a case reported by Ziehen[214] a similar error was recorded. According to Weisenburg,[195] Keen was led to operate over the facial area in a case of this kind.

---

* It should not be forgotten that tumors may actually arise in the facial and give recess symptoms as well as complete paralysis. The condition is rare, however. (*Cf.* the case of Raymond, Huet and Alquier.[147])

**Gustatory disturbances.**—In the summaries of the case histories instances of impaired sensation of taste have been recorded in connection with the VII$^{th}$ nerve, possibly erroneously, but it is my conviction, as the result of some earlier studies,[42] that the fibres of the chorda tympani ascend by way of the N. intermedius of the VII$^{th}$ rather than through the second division of the V$^{th}$ nerve, as had been commonly supposed.

A subjective disturbance of taste was noted in sixteen patients in the series and in most of them, according to the record, it was supposedly corroborated by clinical tests. I am rather doubtful, however, as to the accuracy of the observations, particularly since all of these patients, except Cases XI and XXVI, had a coincidental well-marked hypæsthesia of the trigeminal skin and mucous membrane fields and, unless the tests for the cardinal taste qualities are made with full appreciation of the difficulty of interpreting gustatory impulses, when common sensation over the tongue is affected, errors may easily be made. In Cases XI and XXVI, however, the facial was objectively involved, whereas the trigeminus showed only a lowered corneal reflex, and though it is unsafe to draw deductions from so few examples, they are nevertheless suggestive.

Four of the positive cases (Cases VIII, XIX, XXIII and XXX) were examples of bilateral trigeminal involvement, and in others all the nerves from the VI$^{th}$ to the VIII$^{th}$ were objectively affected and in all probability there was an involvement of the IX$^{th}$ as well. This was almost certain in Case XXX, for there was complete ageusia. It may be noted that on anatomical grounds the central stations of the N. intermedius are more or less intimately connected with those of the glossopharyngeus, so that in some of these patients both nerves may have been affected and taste perception lost over the entire half of the tongue. No accurate gustatory tests of the posterior half of the tongue to determine this were made in this series, nor so far as I know have they been made by others.

**The Nn. glossopharyngeus, vagus, accessorius, and hypoglossus.**—Clinical evidence of involvement of these nerves has been described, but, in view of the experiences in this series of patients with the very inconspicuous evidences of disordered function on the part of the V$^{th}$ or VII$^{th}$ nerves despite an extraordinary degree of distortion, I confess to some doubt as to whether an impairment of function may reach such a stage as to be often demonstrable.

In the accompanying sketch (Fig. 178) of the normal disposition of the cerebral nerves it can be seen how close the foramen of exit for the IX$^{th}$, X$^{th}$ and XI$^{th}$ (foramen lacerum posterior) lies to the porus acusticus internus, and how it is that an acoustic tumor would just as certainly displace and elongate these nerves caudad to the growth as the V$^{th}$ and VII$^{th}$ lying cephalad to it, as the pons and medulla became crowded away from the median line.

Motor and sensory nerves, however, as we have seen, adapt themselves with extraordinary readiness to such a gradual elongation and distortion, which in the case of the nerves in question might easily occur without clinical evidences of loss of function. Nevertheless the difficulties of deglutition and the slurring speech and possibly also the hiccoughing and yawning so common in the later history of all of these cases are doubtless coupled with a composite impairment of function of these posterior cerebral nerves, and the resulting symptoms may at

times so closely resemble a bulbar paralysis as to have led as eminent a diagnostician as v. Leyden[113] to make this diagnosis in a case of acoustic tumor.

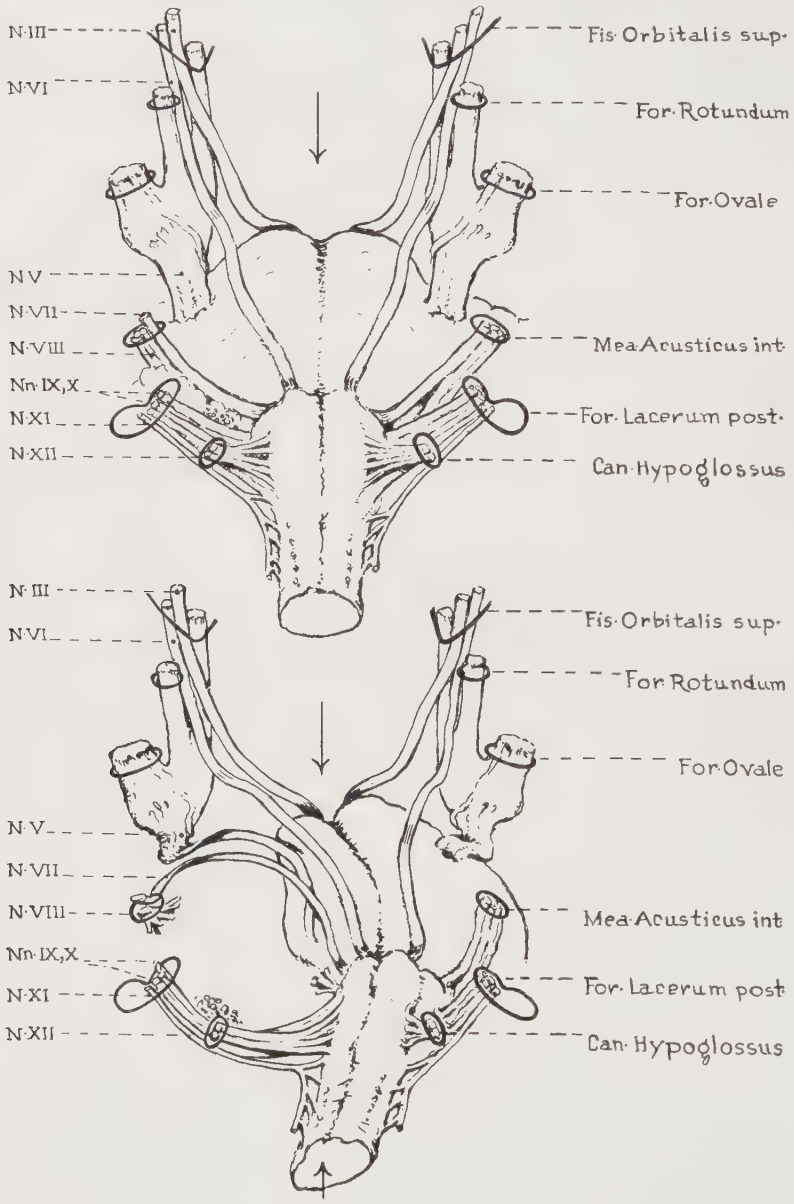


FIG. 178.—Showing, from studies of actual cases, the normal relations of the cerebral nerves and their foramina of exit to the brain stem, contrasted with the distortions which occur from an acoustic tumor of moderate size.

**The IX$^{th}$.**—Glossopharyngeal symptoms are notably difficult to detect by themselves, but the possibility of an involvement of the

IX$^{th}$ must be admitted in view of the frequent record of a subjective impairment of taste,* and its total loss in Case XXX. In how far the dysarthria and dysphagia, so commonly observed, should be regarded as evidences of glossopharyngeal involvement is not clear. To this we shall return.

**The X$^{th}$.**—Unquestionably the first vagal symptom in case of a serious intracranial implication of the X$^{th}$ nerve would be a vocal cord impairment, but unfortunately a routine examination of the larynx has not been made. In one patient (Case XI), though a homolateral vocal cord paralysis was present, it was apparently due to an antecedent lesion of some sort, for it preceded the auditory symptoms by two years. In Cases XIV and XXIX a temporary vocal cord paralysis followed the operation, and it is quite probable that this has occurred in all of the cases in which too radical procedures have been undertaken. The nearness of the manipulations to the IX$^{th}$, X$^{th}$ and XI$^{th}$ group was indicated in many of the operations by the occasional twitching of the accessorius musculature and in many of the later operations this bundle of nerves has been purposefully exposed early in the procedure.

The so-called vagal attacks, such as have been fully described by Sorgo[167] among others, characterized by flushing, by slowing or quickening of the pulse, by labored respiration, and so on, I am inclined to regard as evidences of medullary involvement associated with the increased tension and resultant herniation of the cerebellum about the medulla in the foraminal cone. They will be described later as cerebellar crises, which is but another name for them, and inasmuch as similar attacks may occur in patients with an intracerebellar lesion in the absence of cerebral nerve involvement, it seems improbable that the lower cerebral nerves should play an essential rôle in their production. Admittedly, however, it would be difficult to distinguish clinically between nuclear and trunk disturbances of these nerves.

**The XI$^{th}$.**—Evidences of an accessorius palsy were observed on admission in but one patient (Case XIII). Doubtless a functional involvement of the XI$^{th}$ nerve occurs more often than the clinical records would make apparent, but weakness of the accessorius musculature is less easily detected than in the case of the facialis or abducens, for example. The fact that during the process of making an intracapsular enucleation, as already mentioned, twitching of the trapezius and sternomastoid may occur while dislodging fragments from the neighborhood of the jugular foramen, shows the intimate relation of the nerves to the posterior hemisphere of the tumor. Radical tumor extirpations have, as already noted, been the frequent source of a total facial paralysis, and there is little doubt but that an injury of the accessorius, such as occurred in Case XIX, is a still more common though objectively less apparent sequel.

Irritative accessorius symptoms have not been observed in this series, though there is no apparent reason why they should be any less frequent than in the case of the facial nerve. In a patient with a

---

* Attention may be drawn to the report by Gierlich[69] in 1908 of an isolated recess neurofibroma which apparently originated from the N. glossopharyngeus.

recess tumor of peculiar character (Case XXXVI) spasms of the trapezius were so outspoken that a diagnosis of torticollis had been made. Weakness of the trapezius was described in a case by Oppenheim, whereas Wiersma[201] has recorded a case with complete paralysis of the accessorius musculature, though in view of the attachment of the tumor to the dura noted in his brief report, I suspect that the growth may not have been an acoustic tumor.

**The XII$^{th}$.** In view of the anatomical situation of the hypoglossal foramen and the relation of this nerve to the tumor (*cf.* Fig. 178), a hypoglossal palsy, with deviation of the tongue toward the side of the lesion, would seemingly occur at least as often as a palsy of the three preceding nerves. A slight deviation of the tongue is frequently mentioned by one observer or another in the course of various examinations on the cases in this series, but never a paralysis or atrophy.

Stewart and Holmes ascribe the deviation of the tongue to pressure on the central hypoglossal connections within the pons, others to stretching and distortion of the nerve, but in view of the extent to which the facial nerve may be elongated without anything but the slightest expressional weakness of its musculature, it seems improbable that a similar though less marked stretching of the hypoglossus would impair the movement of the tongue. There is, however, another possible explanation.

It has been learned from the study of patients after a trigeminal neurectomy for neuralgia that the tongue, although unaffected by the ensuing motor and sensory paralysis of the V$^{th}$, except in so far as the sensory loss over the anterior two-thirds of its surface is concerned, nevertheless tends to protrude toward the affected side, if one estimates the position of the organ from the midline of the face. This is a common source of confusion in the recorded results of the cerebral nerve examinations.

Owing to the paralysis of the pterygoids in consequence of the division of the motor root, the jaw deflects toward the afflicted side and the tongue tends to protrude in the center of the deflected jaw, from which it appears to gain its sense of position. Thus in six of the seven cases in the series in which invariable deflection of the tongue was noted there was a coincident and outspoken trigeminal involvement, both sensory and motor. Case IV, in which, though the jaw is said to have had a mid position the tongue nevertheless deflected toward the side of the lesion, proves to be the single exception.

According to Henneberg and Koch,[78] an actual hemilingual paralysis with atrophy has been recorded by Wallenberg, and in one case Jacobson observed spasmodic cramps in the partially atrophied tongue. Wiersma[201] has briefly reported a case with coincident accessorius and hypoglossal palsy, though there is some question as to whether the lesion was an acoustic tumor, and two cases reported by v. Voss[191] of St. Petersburg were said to have had an apparent atrophy of the tongue. Furthermore, what appears to have been an undoubted example of bilateral acoustic tumor with "Atrophie beider Zungenhälften" has been put on record by Stark.[170]*

* In fact, a number of the recorded examples of atrophy of the tongue have occurred in patients with bilateral tumor or generalized neurofibromatosis (e. g., Seiffer[161]), so that there may have been an actual lesion of the hypoglossus itself to account for the condition.

The IX$^{th}$, X$^{th}$, XI$^{th}$ and XII$^{th}$ nerves, in short, do not seem to play, other than in exceptional cases, an important symptomatic rôle in these acoustic tumors, though there is one important group of symptoms which appear in advanced cases and which some authors ascribe to them. These symptoms, which will be considered further on, are related to the act of swallowing and phonation and their presence is always a warning of an advanced process and of especial hazard in undertaking an operation, for respiratory failure, particularly during the administration of an anæsthetic, is likely to occur in patients showing these symptoms.

## The General Pressure Symptoms

Headaches of the pressure type with nausea and vomiting and a subjective blurring of vision due to an early papillœdema seem to have been recorded as fairly early symptoms in some cases, but inasmuch as these pressure phenomena are unquestionably produced by a secondary dilatation of the ventricles due to the distortion of the pons and obstruction of fluid outflow through the iter, it is unlikely that they should precede the neighborhood symptoms already mentioned.

Choked disc. Almost all patients with brain tumor admitted for a surgical clinic have a choked disc and in many the process is advanced. In many patients, indeed, the process has advanced through a secondary atrophy to total blindness, though I am encouraged to believe that this is less often the case today than ten years ago. In a recent analysis of sixty-three certified cerebellar cases in this clinic, Grey[75] found that six had been admitted before there was any measurable papillœdema, but in the present series of acoustic tumors the patients with but few exceptions presented themselves with an advanced process. Cases II and XXX were already blind. In six cases (e. g., Case XXVII) vision on admission was reduced to shadows. In eighteen the process was advanced though vision as yet was not greatly impaired, and in only four could the process be considered an early one. The expectation of vision under these circumstances will be considered in connection with the results of operation.

Vomiting, as in all tumors of the posterior fossa, is a common symptom by the time pressure manifestations have set in—possibly more common than with intracranial tumors situated elsewhere. Indeed even after operative relief from pressure has been afforded, morning nausea and vomiting often associated with dizziness may persist for a long time. In only a few cases has there been any history of vomiting in association with the early vestibular symptoms, which therefore differ in this respect from the usual syndrome of Ménière.

A blunting or loss of the sense of smell may occur in association with advanced grades of intracranial tension, particularly when produced by cerebellar lesions, according to Muskens,[132] who attributes it to the pressure effects of a dilated third ventricle. Mills[124] and others have ascribed it to a choking of the olfactorius, of a sort similar to a choked disc of the opticus. In one of the writer's cases of cerebral tumor it has been shown to have been produced by a mechanical angulation of the olfactory tracts by the interclinoidal edge of the dura.[47]

Grey's analysis[75] showed that in only four out of sixty-one cases of verified cerebellar tumor was a definite impairment of olfaction recorded, doubtless far too low a percentage, inasmuch as several examples occur in the present series. A relative anosmia was present in Cases I and XXIII and a complete loss in Cases IV, XI and XXX.

As a rule only very rough tests of the sense of smell have been made, for its impairment is of no great diagnostic significance and may be misleading. Indeed in those exceptional circumstances when there is confusion of localization between a frontal and a cerebellar lesion I have known of instances in which so much stress was laid on the presence of anosmia that it led to the wrong diagnosis.[47]

One rare sequel of an acquired internal hydrocephalus—namely, a cerebrospinal rhinorrhœa—may occur as a complication of an acoustic tumor. Of this Stark has given an illustrative case,[170] the patient having a bilateral lesion.

*Psychic disturbances.* Another group of symptoms which are an expression merely of the general increase in tension associated with an internal hydrocephalus are of a psychic order,* so-called frontal-lobe symptoms, characterized by an impairment of the intellectual faculties. They have been made the object of special study by Schuster[160] and by Pfeiffer.

They may occur as early features of the syndrome, as in Preisig's[141] case and many others, but are more likely to be a source of confusion with an advanced lesion, as will be noted in the chapter on diagnosis. Thus in Case VII of the present series it will be recalled that the mistake had been made of regarding the symptoms as of cerebral rather than cerebellar origin.

Collier,[39] in his article on false localizing signs, refers to a case of presumed cerebellopontile tumor seen in the National Hospital (cerebellar symptoms, nystagmus, paralysis of the left VI$^{th}$, VII$^{th}$ and VIII$^{th}$ nerves and a choked disc), the autopsy revealing a glioma of the left prefrontal region. Only on the basis of similar misleading symptoms can I account for the fact recorded by Tooth[182] that in 17 negative explorations made by Horsley for what subsequently proved to be a frontal tumor, 5 were made over the cerebellum. One would expect that a mistake in the reverse direction would be much more common, but only a single example of a frontal exploration for what proved to be a cerebellar tumor is found in his records.†

In Case XIX of this series mental symptoms had become very marked, with stupor and disorientation. In Case XXIV periodic psychoses with dispositional changes were particularly noticeable, and in several others there

---

* These symptoms must be distinguished from the psychoses so common in Recklinghausen's disease and central neurofibromatosis.

† We have by no means been exempt from mistakes similar to those to which Collier calls attention, and it is somewhat disconcerting to have brought one or two examples to light while making the studies for this report. Thus in going over all of the plates in the X-ray department in which a dilatation of the porus acusticus had been observed, one very excellent example of this condition was found to have been noted in a patient not subjected to operation but in whose history a diagnosis of frontal-lobe tumor (uncertified) had been made. A careful review of her story in the light of our present better understanding of these cases makes it clear that she unquestionably had a left acoustic tumor, though the evidences of this at the time were completely overshadowed by her frontal-lobe symptoms.

was loss of memory and inactivity of the mental processes, which was often appreciated by the patient only when contrasted with the more active cerebration following the operation.

### Dysphagia and Dysarthria

In leaving the subject of the cerebral nerves, mention was made of certain characteristic signs of an advanced growth, namely disturbances of articulation and of the act of swallowing, which may possibly be ascribed to an involvement of some of them.

*Dysphagia.* The deglutitory difficulties first manifest themselves by the consciousness of effort required in the act and by the tendency of food particles to "go the wrong way," to get up behind the palate and cause sneezing, or into the larynx and cause coughing. This of course may be due to some sensory disturbance of the fauces or pharynx, and if this is so may properly be ascribed to an involvement of the glossopharyngeus and consequent impairment of the complicated reflex act of deglutition.

A definite nervous mechanism, the motor centers for which are participated in by the IX$^{th}$ to the XII$^{th}$ nerves inclusive, controls this performance, but it is very difficult to determine to what extent dysphagia is due to an involvement of their medullary centers rather than to a peripheral involvement. It is quite possible too, as Babinski and Rothmann and others have suggested, that deglutitory disturbances may arise through an incoördination of the musculature involved in the act, and thus after all be of cerebellar rather than cerebral nerve or medullary origin. The matter needs further investigation.

*Dysarthria.* In varying degree, some disturbances of articulation, with its characteristic and unmistakable thickness, slurring and indistinctness of speech—likened by some to bleating—despite all efforts at clear enunciation, are an even more characteristic symptom of acoustic tumors. Like the foregoing, this may be due also to a sensorimotor reflex impairment of an obscure nature, possibly again connected with a disturbed reflex action of the palatal fauces and thus be in part of glossopharyngeal origin.

Here again there is uncertainty as to whether the difficulty is due to some combined cerebral nerve palsy (for paralysis of no individual nerve will produce the same effect), to pressure on medullary centers, or to the cerebellar incoördination of the musculature concerned in the act (Babinski and Tournay,[13] Mills and Weisenburg[125]).

Whatever may be their cause, these symptoms of dysphagia and dysarthria probably occur before the end in every case of cerebellopontile tumor, and inasmuch as the dysarthria is the more obvious its presence is more commonly noted. One or both of these symptoms were recorded in twenty-one of the thirty cases, all of them examples of an advanced process with multiple cerebral nerve involvement.

It may be added that dysarthria and dysphagia are likely to be increased for a time by extensive operative procedures, in which case the deglutitory difficulties invite an inhalation pneumonia and may lead to an ultimate fatality from this cause. In two of the patients (Cases XI and XII) the postoperative dysphagia was so marked that nasal feeding for a long interval had

to be resorted to, and it is quite probable that had this measure been employed sufficiently early in Cases X and XIX the terminal pneumonia might have been avoided.

### Cerebellar Crises

Mention has been made of the characteristic suboccipital discomforts which occur and which in some patients in the course of time may progress and lead to paroxysms of a most extreme and agonizing type, with retraction of the neck and back, respiratory difficulties, an altered pulse, a sense of impending death and often with loss of consciousness. At the outset of the attack the victims may scream, and graphic descriptions of seizures of this severe type are found in the earliest literature on the subject. The following quotation has been taken from J. H. Wishart's report of a case in 1822:

> "For six months past, he has been attacked every eight or ten days with violent paroxysms of pain, which continue for three or four hours. At the commencement he complains of a very peculiar and disagreeable smell. During the paroxysm, the pain extends from the tumour in the back part of the head, through the whole muscles of the neck and back, and likewise to the forehead, lower jaw, arms, stomach, and the muscles of the abdomen, which are at the time as hard as a board. He at the same time is unable to move the lower jaw; the muscles of the face are affected with twitching; the trunk of the body is drawn backwards; and some of the fingers are deprived of feeling. At the termination of the paroxysm he frequently falls into a profound sleep, which sometimes continues for three days, with scarcely any intermission."

Cerebellar seizures were observed in seven patients in the present series (Cases IV, V, VIII, XVI, XIX, XXIX and XXX). They have been variously termed vagal attacks (Starr) and cerebellar seizures (Dana[51]), but their causal factors are not entirely clear and they seem to be quite unlike the "lowest level fits" described by Hughlings Jackson in cases of tumor of the vermis. According to Ziehen,[214] Frankl-Hochwart regarded them as a sort of modified Ménière's attack and spoke of them as epileptic seizures with a Ménière's aura. This description, however, would not fit the attacks which I have seen.

These cerebellar seizures may occur with advanced tumors of the posterior fossa of almost any type, but in my experience they have been particularly characteristic of recess tumors, though not necessarily of acoustic neuromas (e. g., Case XXXVI). I am inclined to believe that they are due to the periods of variable tension of the cerebrospinal fluid retained in the arachnoid cisternæ, as will be explained.

### The Fluctuation of the Symptoms

As mentioned heretofore, one of the notable features of these cases is the great variability from time to time in the character of the symptoms, with periods of amelioration particularly in those of a subjective order. This is true of nearly all the symptoms except those referable to the acusticus itself. Diplopia, for example, though few patients fail to have observed it at one time or another, is apt to be fugitive, and the same thing is true of the tri-

geminal numbness. There is also great variability in the degree of static instability as well as in the discomforts from day to day, and in the earlier stages, as in Case V, the symptoms may entirely disappear for a few months. Even when the condition is advanced their intensity seems to vary much more than in the general run of cerebral tumors, variable as the intensity of symptoms accompanying all of these lesions may be. The fluctuation of symptoms has been attributed to various causes, for example to extravasations within the tumor by Jumentié,[92] and it is quite possible that the sudden access of symptoms, which may follow a blow or other injury, thus originates. There is another possible, and what seems to me a far more probable, explanation.

It is to be remembered that the tumor in the course of its enlargement must first impinge on the flocculus and in all likelihood the tuft of choroid plexus (plexus choroideus ventriculi quarti) in this region which apparently secretes into the cisterna lateralis, continues to pour fluid into the cistern, the proper evacuation of which is more or less interfered with by the growth.

Though I have no real knowledge of the course of circulation of the fluid which is secreted by these lateral paramedullary plexuses, the frequency with which a dilated arachnoid cistern is found overlying the tumor is best explained by a circulatory obstruction. Whether or not this hypothesis will prove to be correct, it nevertheless serves as a satisfactory explanation of the fluctuation of symptoms which these cases so often show early in the course of the disease and also for the fact that comparatively small tumors may at times produce marked general pressure disturbances, for, as we shall see (p. 219), the tumor actually lies within the lateral cistern, and the growth together with the pocket of fluid may attain a considerable size. This, indeed, is one reason why a circumscribed serous meningitis of this region may be difficult to distinguish from an actual acoustic tumor, and also why in some cases of actual tumor a lumbar puncture may give a period of relief, dangerous as this procedure may be.

In the case of the cerebellar crises which have been described, it is quite possible also that the paroxysms may be provoked by periods of excessive tension of the cerebrospinal fluid retained in the cisternæ medullo-cerebellares.

### The Sensory and Motor Paths

What have been designated as "medullary symptoms," indicating an involvement of the motor and sensory pathways, have been observed in a few cases in the series. Some of the patients (e. g., Cases IV, V, VIII and XXII) complained of a sense of numbness always on the homolateral side of the body, and in a few (e. g., Cases XXVII and XXX) confined chiefly to the hand and arm. In one patient (Case X) there was also some twitching of the arm and leg.

These symptoms are not infrequently noted in the case reports of others (*cf.* Brückner). In a case reported by Putnam and Waterman,[143] paræsthesias of the left (contralateral) hand, arm and face occurred and led to an exploration of the postrolandic area of the right cerebrum, whereas a right acoustic tumor was found postmortem. Alquier and Klarfeld's Case III

had a spasmodic hemiparesis with Jacksonian crises homolateral to the lesion.

The deep reflexes with but few exceptions (e. g., Case VI) were active to exaggeration, possibly due to the hydrocephalus, in all of the 30 cases on admission. As a rule also they were equally active on the two sides, though in eight the homolateral reflexes were the more active, with an occasional suggestion in four patients of clonus at the ankle (e. g., Cases VIII, XIV, XXII and XXVIII), and in these cases also there was a suggestive dorsal toe response on the same side.

Others, who have written on the subject, have described contralateral spasticities with clonus and a positive Babinski plantar response, but this must be less common, for the more active reflexes opposite to the lesion were noted in only four patients (Case V on her second admission, Cases XVII, XXII and XXVI). When such a condition occurs it is presumably due to pressure of the tumor on the adjacent corticospinal tract in pons or medulla, but even in the presence of such a degree of pontomedullary distortion as was present in Case XV, there was no disparity in the reflexes of the two sides, no clinical evidence of any pyramidal tract degeneration shown by the reflexes, nor any definite tract degenerations apparent in the histological preparations of the cord.

*After-word.* From the above group analyses of the individual symptoms, as well as from the story connected with the case histories, it can be gathered that the symptomatic progress of the average acoustic tumor occurs more or less in the following stages: first, the auditory and labyrinthine manifestations; second, the occipitofrontal pains with suboccipital discomforts; third, the incoördination and instability of cerebellar origin; fourth, the evidences of involvement of adjacent cerebral nerves; fifth, the indications of an increase in intracranial tension with a choked disc and its consequences; sixth, dysarthria, dysphagia, and finally cerebellar crises and respiratory difficulties.

I know of no better clinical description of the symptoms of an advanced case than was given in 1829 by John Whiting in his letter to Charles Bell[19] concerning the patient in whom Bell had been interested at the time because of the trigeminal involvement. So far as I know it is the first clinical description of one of these lesions to be associated with a postmortem study. Whiting wrote as follows:

"I found that she still had a distressing sensation on the left side of her face, etc., although altered in its character; her speech had become indistinct, her face was drawn to the right side, the masseter and temporal muscles of the left side had ceased to act, the tongue was protruded towards the left side, the hearing of the left ear had ceased; she could raise the left upper eyelid by voluntary power, but could not keep it elevated; the effort to raise the globe of the eye was attended with headache and giddiness; there was considerable secretion of tears; she was emaciated and bed-ridden, and complained of great and constant pain at the back part of her head.

"About a month before her death her intellects became confused, her breathing difficult, her speech quite indistinct, and her deglutition impeded; she occasionally ground her teeth with violence, and her jaws were often firmly clenched, apparently by the contraction of the muscles of the right side: she seemed to die at length (in February, 1829) from difficult respiration, and want of the power of swallowing."

## CHAPTER VII

# PATHOLOGICAL ANATOMY

There are two equally important aspects of the pathology of intracranial tumors: one, the gross characteristics of the neoplasm, including the secondary alterations of the meninges and brain which it produces; the other, the histological nature of the lesion. To these a third may be added,—namely, the degenerations which occur in the conducting paths and their end stations. In the case of the tumors under discussion, much remains to be learned in regard to all three of these factors.

Satisfactory studies of tumors in gross have been long handicapped owing to the distortions produced by the customary method of removal of the brain at autopsy, stripped of its meninges, with subsequent fixation of the tissue. Unquestionably, for a proper investigation of the relation of the tumor to its environment, primary fixation of the brain by intracarotid injections with a subsequent removal of the hardened tissue so far as possible within its intact meningeal envelope, is a necessary procedure, as has been emphasized in another connection.[44] Like all other things which are worth while, this performance requires time and practice, but it is time well spent, and prospective neurological surgeons above all others would do well, whenever opportunity offers, to familiarize themselves with the intracranial conditions associated with states of tension which are disclosed during the process of removing the previously hardened brains of tumor cases.

### Gross Appearances of the Lesion

(1) **The tumor itself.**—Small tumors and their origin in the distal part of the nerve. The view has been advanced by Henschen[81] that acoustic tumors originate in most, if not in all, instances in the peripheral portion of the nerve and possibly, indeed, within the auditory canal. Certainly all examples of early tumors which have been chance postmortem findings have been so situated. Six of these small tumors have been put on record: the first was described by Toynbee[184] in 1853, as follows:



Fig. 179.—Toynbee's drawing of his case of "acoustic neuroma." (a) N. cochlearis; (c) N. vestibularis; with (b) a branch to the tumor. (Nat. size.)

"In the internal auditory meatus, besides the portio dura and portio mollis nerves, both of which were in a healthy state, there was a tumor about the size of a small pea (Fig. 179). This tumor was of the consistence of the white

matter of the brain, and it received at its posterior part a small filament from the vestibular nerve; while, from its anterior part, a small branch entered the cochlea. The tumor was composed of matter very similar to gelatine, in which nerve-tubules were observed to be distributed."

Other small tumors, for the most part without any clinical history, have since been described by Habermann, Panse[136] (1904) (Fig. 180), Alexander[4] (1907), Henschen[79] (1910) (Fig. 181), Wolff[207] (1912) (Fig. 182), Quix (1912), and recently (1915) another case has been reported by Henschen[81] which represents by far the most important and thoroughly studied of all. The patient (Case 36) had died of hemorrhage from a gastric ulcer and the small tumor (Fig. 183), which had given no recorded clinical symptoms, was disclosed at autopsy as a coincidental lesion. The petrous bone was decalcified and serial sections were made through the tumor, which was reconstructed in wax (Fig. 184), so that the exact relations to the nerves could be determined. The radix vestibularis was the branch chiefly involved and it may be noted that even in this young tumor the facial nerve as it lay within the canal was much flattened.

Fig. 180.—Section of pyramidal bone showing tumor filling and widening canal. A chance post-mortem finding. (After Panse: twice nat. size.)

Attention to the probable peripheral seat of origin of these acoustic tumors had been drawn by Henschen in his dissertation in 1910, and he laid special

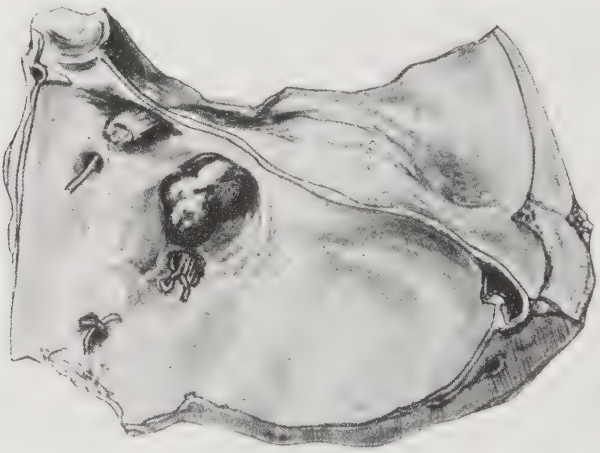

Fig. 181.—An early tumor described by Henschen (1910: Fall XII).

stress upon what had been observed by many others before him,—namely, that the porus acusticus internus is commonly occupied by a process of the tumor which may serve to

enlarge it. It was suggested that this might prove to be of some diagnostic significance and subsequently (1912)[80] he succeeded in demonstrating that the

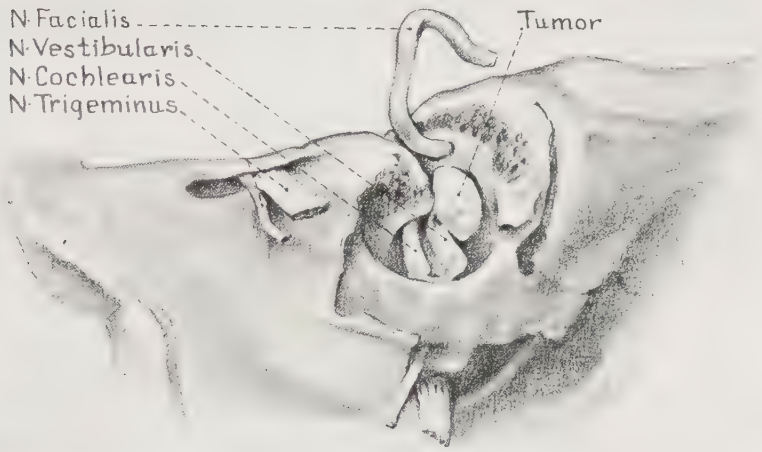


Fig. 182.—Wolff's case of small tumor arising in the canal from the vestibular nerve.

dilated internal meatus might be shown by the X-ray, a matter to which we have already referred and shall again return.*

The distention of the internal auditory meatus, often with more or less absorption of the adjacent temporal bone, so often noted by the earlier writers, had become largely forgotten or its significance overlooked until Henschen drew renewed attention to it. In a great number of the early pathological descriptions of these tumors the fact that a projection of the tumor lies within the auditory canal is either specifically mentioned or is apparent from the description or illustration. It is true that these were all examples of large tumors which had given cerebellopontile-angle symptoms and caused an ultimate fatality thereby, and under these terminal conditions the exact point of origin of the lesion was obscure.

Fig. 183.—The tumor projecting from the porus (nat. size) in Henschen's 1915 case (*cf.* Fig. 184).

* The distinction between the endotheliomas (psammomata) which originate from the meninges within or near the porus and the true acoustic tumors must be continually borne in mind, for early in their course they give the same symptoms. The psammomas, as Virchow[189] clearly pointed out, are more certain in the course of time to dilate the canal than the acoustic tumors.

It was a natural supposition that the growth had come to project into the canal. For example, in John Whiting's letter to Charles Bell in 1829, from which a quotation has already been made, the following description of the lesion occurs.

"The first and second pair of nerves on the left side were as usual; the third was slightly displaced by the tumor; the fourth undisturbed; the fifth appeared to come from the fundus

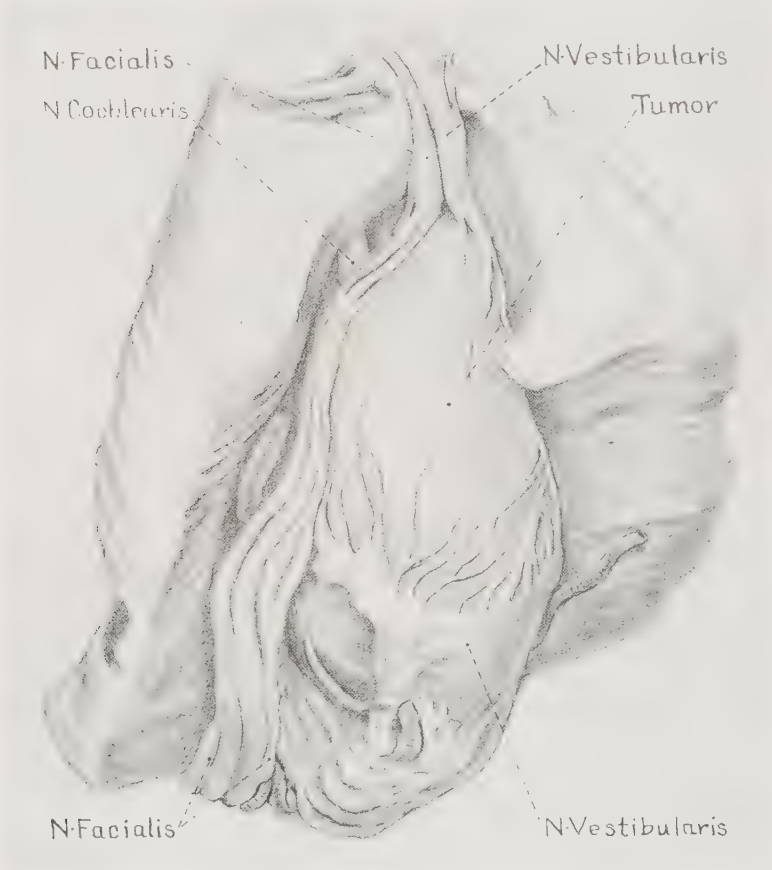


Fig. 184.—Reconstruction in wax of Henschen's 1915 case of early tumor (*cf.* Fig. 183).

of the tumor, passed under the dura mater at its usual place; it was flattened and thin as if from pressure, and could be traced along the coat of the tumor no further than within about half an inch of its origin. The sixth pair was healthy; but the seventh, both portio dura and mollis, was completely involved and lost in the tumor from a quarter of an inch from its origin to the meatus internus; and into this foramen no nervous structure could be seen to enter, but a substance resembling the membranous portion of the tumor and apparently a process of it; both portions of this nerve, however, were distinct from each other at their origin, and of their usual appearance."

In Cruveilhier's plate (Fig. 2) the large absorption defect in the temporal bone was clearly shown, and in 1840 Weiglein made a similar observation in his case (*cf.* p. 194). In 1862 Virchow gave a typical clinical history and accurately described an acoustic tumor which not only produced the usual deformation of structures in the lateral recess but projected into and caused a pressure atrophy of the internal auditory meatus, which was dilated to one-half a centimeter in diameter. He regarded the tumor as a true neuroma of the acusticus which had undergone sarcomatous degeneration—a sarcoma fusicellulare. Westphal[197] in 1874 reported a case as a spindle-celled sarcoma, and the tumor had grown into the canal. Klebs[96] also, in 1877, in describing a tumor designated as a "neuroma fasciculare lymphangiectaticum n. acus-

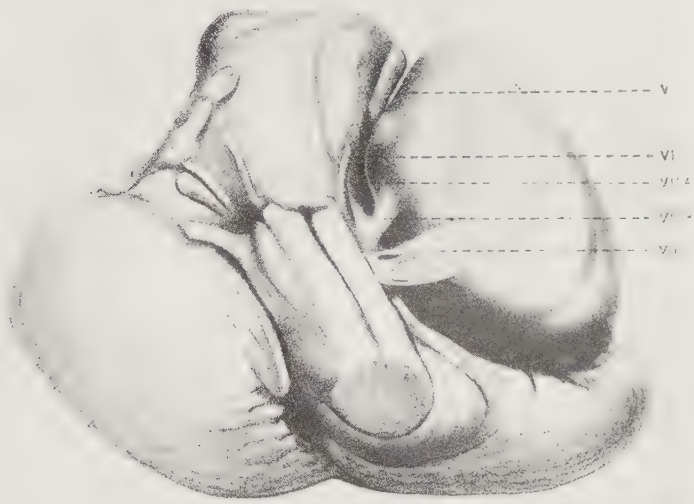


Fig. 185.—S. G. Shattuck's drawing of Sharkey's 1888 case.

tici," mentions its projection into the meatus. Sharkey[163] in 1888 says of the tumor in his case (Fig. 185):

"It lay in the occipital fossa, and terminated in a short nozzle, which was lodged in a cavity in the petrous part of the temporal bone. The cavity showed no signs of disease and the bone around it was quite healthy. It was in fact the internal auditory meatus expanded by the pressure of the tumor."

A similar description of a case was given by Druault[32] in 1898 and another example occurs in Politzer's *Lehrbuch* of a "spindle-celled sarcoma" (?) which had completely filled the internal auditory canal (Fig. 186): the patient had been deaf for ten years and had only shown pressure symptoms for three months before death. Ballance[16] also mentions the fact of the porus being dilated in one of his cases, and it was noted also by Askanazy in his pathological notes accompanying some of Funkenstein's cases:[64] in one of them the growth had even dilated the facial canal and penetrated as far as the genicu-

late ganglion. Many other examples from the literature might be cited in which the presumable extension of the growth into the canal, even so far as to penetrate the lamina cribrosa and produce great destruction, had been observed, and among later writers the condition is more often noted than not.

On the other hand, if these tumors tend to originate from the nerve within the canal some pressure absorption of the bone may occur. According to Fumarola,[63] Mingazzini in 1897 described a tumor which he thought had originated within the canal, producing secondary involvement of the nervous structures in what he termed "the angle." Panse noted in 1904 that the small tumor which he described (Fig. 180) had caused some pressure absorption of the walls of the canal, and if such a condition is demonstrable by the X-ray before the growth protrudes into the lateral recess and becomes sufficiently large to provoke the cerebello-pontile-angle syndrome, it might be of great diagnostic value, as Henschen intimates. However, as indicated in the chapter on symptomatology, our radiographic methods in this direction need to be perfected, and as a matter of fact it is quite probable, from the cases reported in the literature as well as from our own experience, that a tongue of the tumor may project into the canal without distending it in the least.

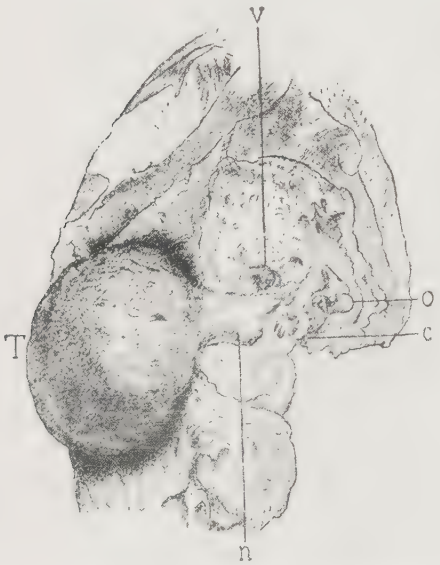


Fig. 186.—Politzer's case of an angle tumor arising from the acusticus and filling the internal auditory canal. (T) tumor: (n) its extension: (c) cochlea: (o) cavum tympani: (v) vestibule.

Though only the last twenty cases in this series have been subjected to thorough X-ray studies, and though our methods of securing proper exposures are as yet imperfect, the dilatation of the porus has been so often absent or inconspicuous that one is led to suspect that some tumors, at least, may arise from the endoneurium of the free portion of the nerve and not all of them within the canal as Henschen contends. Alagna's[3] case is one of a very few in which it is specifically stated that there was not the slightest projection of the tumor into the porus, but no postmortem example of an early tumor starting from the free portion of the nerve, so far as I am aware, has been described, unless possibly the case reported by Zange[211] may be of this nature. This tumor, the drawing of which resembles the usual acoustic tumor, was called a "spindle-celled sarcoma with areas of cystic degeneration," and it arose apparently from the sheath of the N. cochlearis, or at least this was

more compressed than the vestibular branch. The growth, moreover, merely projected into the porus acusticus internus, but was not attached therein, being readily dislodged. It affected the cerebellopontile angle in the usual fashion, being easily enucleable. It had merely flattened the auditory and facial fibres.

*The external appearance of the larger tumors.* Acoustic tumors of a size sufficient to elicit a more or less typical cerebellopontile-angle syndrome have a similar and characteristic external appearance. Those of moderate size are more or less oval in shape and as they undergo a further enlargement they conform to the resistant pyramidal bone on the one side, to the base of the posterior fossa below and the tentorium above, whereas on their free side they crowd away from the so-called angle the relatively unresisting cerebellum, the brain stem and the cerebral nerves.

In the fresh the tumors vary greatly in their color and consistency. They are greyish yellow in appearance, and the more yellowish they become, due to a more extensive fatty degeneration, the easier they are to enucleate by the method to be described. The more greyish and translucent the tissue, the more fibrous the tumor and the more difficult it is to scoop out the contents of the capsule.

In all of the examples which I have seen the tumors have been large enough to have completely engulfed the acoustic nerve, though even in growths of such magnitude as in Case XV (Fig. 66) a few fibres of the central end of the nerve may still be made out at its delicate point of attachment in the angle before they disappear on the surface of or within the tumor. As Virchow[190] long ago pointed out, at this stage of a growth it may be difficult to tell whether the growth has originated from the facial or the acoustic nerve, for the former may be also enveloped in the growth.

Unlike the pseudo-neuromas of the peripheral nerves these growths are diffuse throughout the endoneurium and consequently cannot be shelled out of a more or less definite capsule, nor does the involved nerve appear to assume the spindle shape so characteristic of the isolated tumors of the peripheral nerves, though in one of Henschen's sketches (Fig. 187) a suggestion of this arrangement is given, and at operation the tumor in Case XXVI, though smaller, presented a similar appearance.

The contour of the larger tumors becomes more or less irregular as they come to conform to the walls of the posterior fossa and at the same time the surface often becomes somewhat nodular, and individual nodules may deeply indent the side of pons or medulla (*cf.* Fig. 66). Over the surface and lying in the arachnoid membrane are arterial branches (Fig. 31) from the basilar artery destined for a cerebellar distribution, and though these vessels need not enter the tumor they are of such a size and so envelope the growth as to cause hemorrhage of serious moment in case an attempt is made to dislodge one of these lesions by the method of finger insertion so often described.

The size of the tumors which have been observed postmortem in this series have varied from a growth 2½ to 3 cm. in its long axis to one of 7 cm., as in Case III, and of 5 cm. in Case XV, but growths of such exceptional size would hardly be met with except in the case of patients previously subjected to a wide suboccipital decompression, which will permit a degree of enlargement incompatible with an intact skull.

There is one matter of significance in connection with the possible seat of origin of these tumors—viz., the almost invariable presence of a defect on the surface of the tumor corresponding with the situation of the porus, which can be seen on specimens removed postmortem even though its connection with the meatus had been overlooked. A good example of this occurs in even such an early representation of one of these tumors as that by Cruveilhier in 1835 (Fig. 2), and in not a few of the photographs of tumors *in situ* which accompany articles on cerebellopontile lesions can a similar scar be detected. It is apparent in the photographs of the brains of Cases XV and XXX (Figs. 66 and 167).

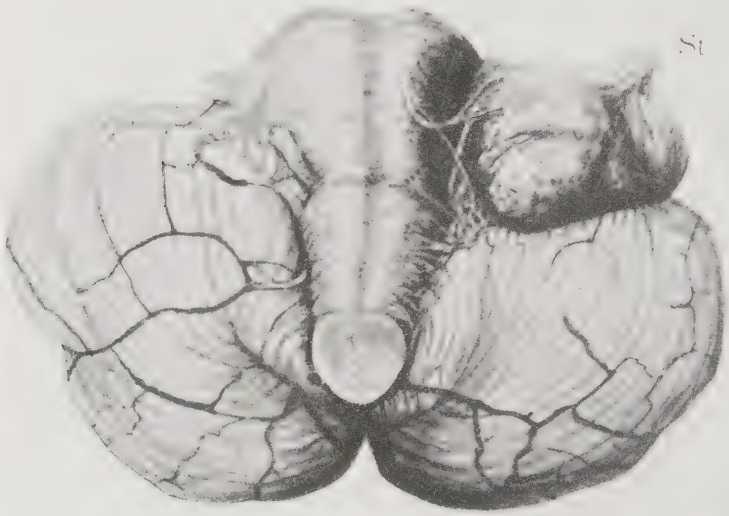


Fig. 187.—From Henschen (Fall XIII), showing acusticus fibres spindling from the stalk on the surface of the growth. (St, stalk.)

It is a source of great chagrin to have to confess that in none of the seven cases in this series which have come to autopsy at our hands has an examination of the pyramidal bone been made, and this is not mitigated by the knowledge that others have similarly failed in this respect. The tumors differ from the true extracerebellar fibro-endotheliomas in having a very small area of attachment despite their considerable size, and as it is well-nigh impossible to remove the brain within the meninges and preserve the membranes which adhere to the pyramidal bone, the relations at this area are likely to be lost. Hence the tumor gives the impression of lying loosely in the subarachnoid membrane of the angle without definite firm attachment anywhere.

Henschen expresses emphatically the belief that careful study would re-

veal an extension of the tumor into the porus in all cases* and it must be admitted that it is rare to find it specifically stated, as in Alagna's[3] report, that there was no such projection. Henschen's explanations of the past failures to observe the point of tumor attachment are threefold, for (1) either the conical projection or plug becomes detached together with the tumor mass on removing the brain or (2) the extraordinary softness of the tissue permits it to be torn away from the surface and the position of the tear is mistaken by the observer for an irregularity of the tumor surface or (3) the projection is so intimately attached to the bone in the neighborhood of the internal meatus as to give the impression that the growth arises either from the bone or from the dura. Henschen believes that the second of these conjectures is the most probable and I am in accord with this opinion.

In the accompanying figures (Figs. 188, 189 and 190) from Henschen[79] and from Lange[106] the stalk of the tumor as it appears within the canal on sections of the petrous bone is well shown. Fig. 191, also from Henschen,[80] shows the appearance from behind of a greatly enlarged area of absorption in a case of acoustic tumor. All of this is of importance in view of the possible aid to diagnosis afforded by the X-ray.

Fig. 188.—Henschen's Case XII, 1910. Stalk of tumor within canal: no great dilatation of porus. (St, stalk.)

(2) **The tumor in its relation to the meninges.**—It has not been sufficiently emphasized that an acoustic tumor is not only subdural and extracerebellar but lies within an arachnoid capsule. This doubtless may be difficult to recognize postmortem, but at operation, when the arachnoid spaces are distended with fluid, it is unmistakable.

* Henschen made a careful review of the recorded cases with this particular point in view, and found that in the larger number of the cases with autopsy reported in the literature no examination of the porus was made at all, whereas in the others the description was too incomplete to justify any definite conclusion, partly owing to preceding surgical manipulations. However, in 30 out of 40 dependable reports the porus was said to have been more or less dilated.

In a recent case, similar to Case XXX, of a large unilateral tumor with bilateral deafness, the temporal bones were removed together with the brain and subsequently dissected away. There was no projection of the tumor into the porus acusticus, which was normal in size, though it had been thought from the X-rays to be dilated. There was, however, a definite projection of the growth into the jugular foramen, which was considerably widened.

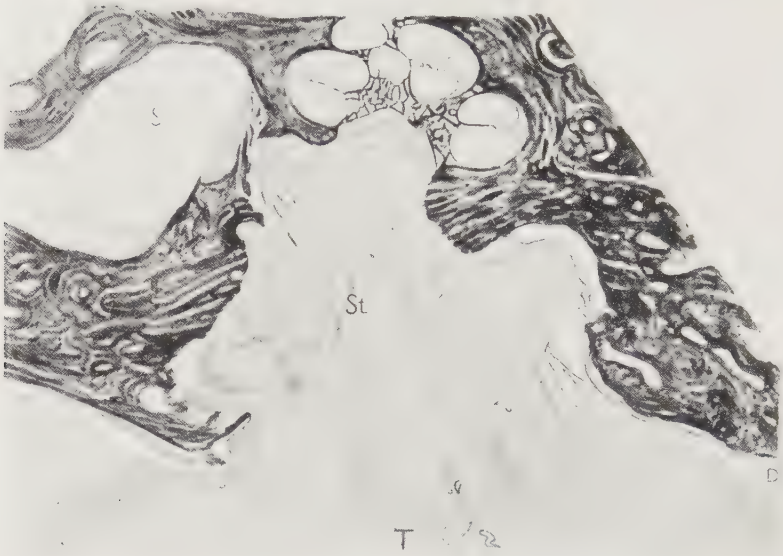


Fig. 189.—Henschen's Case VI, 1910. Stalk of tumor within canal: great dilatation of porus. (T) tumor: (St) stalk.

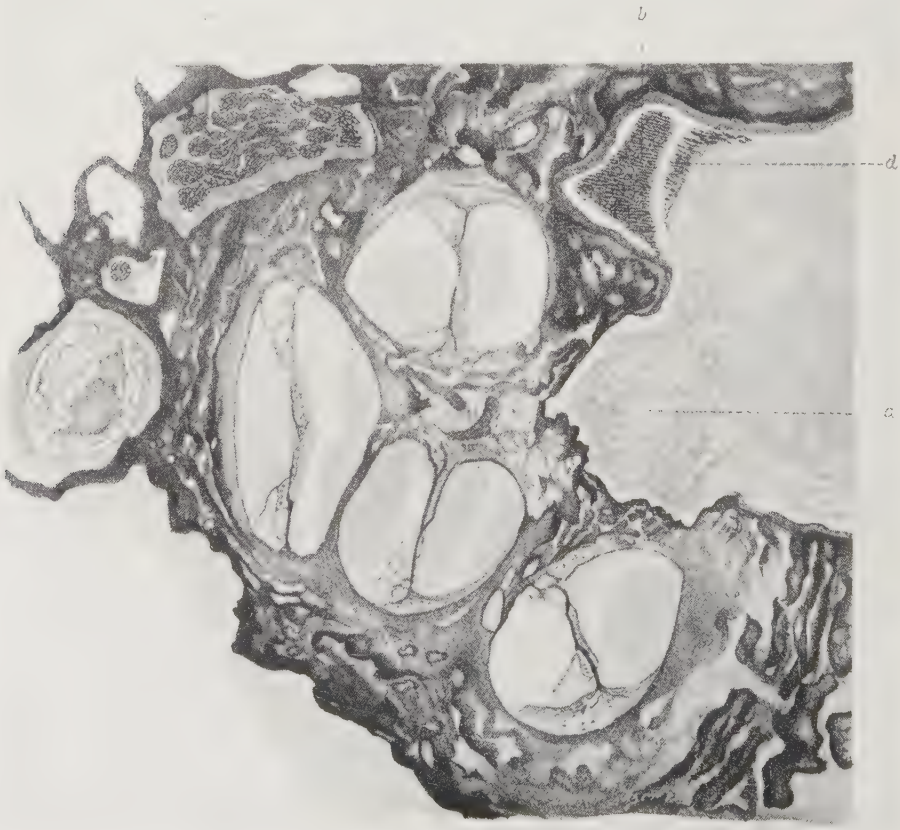


Fig. 190.—(*a*) Tumor; (*b*) N. facialis; (*c*) Ganglion geniculi; (*d*) N. vestibularis (from Lange).

Even when fluid from the posterior fossa has been thoroughly evacuated and an exploration of the angle is made, the first thing encountered is a thickened membrane like the wall of a delicate cyst, bridging across from the edge of the cerebellar cup to the dural surface, and this membrane may have

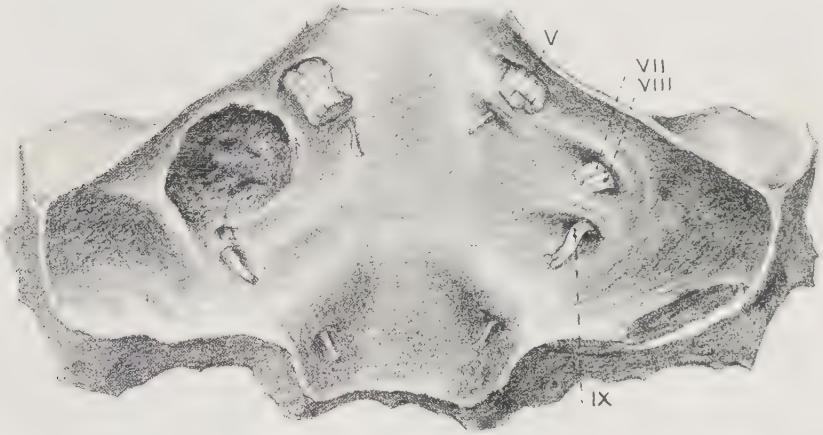


Fig. 191.—Illustrating the pressure absorption fossa produced by a left acoustic tumor (after Henschen).

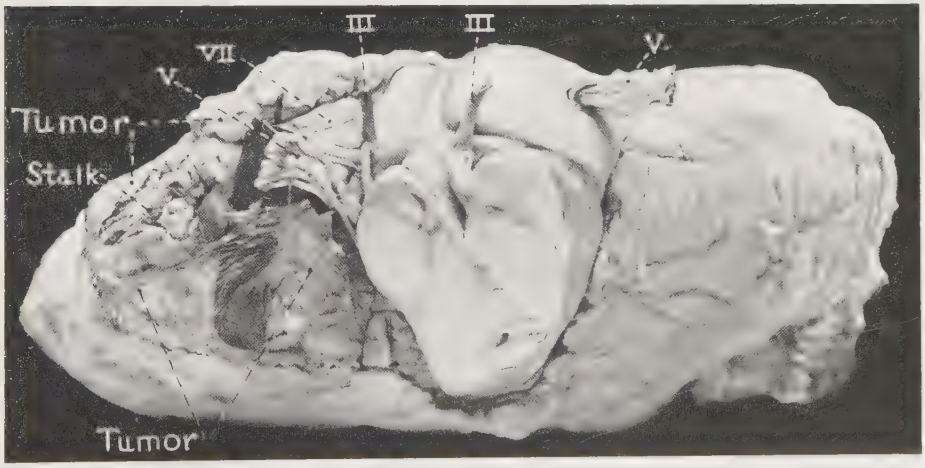


Fig. 192.—Showing superior view of hind brain from Case XV, with strip of black paper inserted between the right acoustic tumor and its enveloping arachnoid. (Photo. nat. size.)

to be broken through before the cerebellum can be drawn to the side so as to expose the tumor. It is quite probable that many an exploration is checked at this stage for lack of understanding of the condition. The membrane extends over the superior surface of the tumor (Fig. 192) and, in fact, envelopes the growth, though the concealed portion may not be demonstrable.

Attention has been called to the obstructive distention of the lateral cistern in connection with the matter of fluctuation of symptoms, and it will be again touched upon from its surgical aspects. In our present connection it will suffice to say that the cistern of the lateral recess which sends its tubular prolongations around the Gasserian ganglion, and encompasses the VII$^{th}$ and VIII$^{th}$ pair as well, is probably fed by the tuft of choroid plexus projecting from the foramina of Luschka, the *plexus choroideus ventriculi quarti* (Fig. 196). The plexus itself may be enormously displaced by the tumor, and in the only case in which I have carefully traced it (*cf.* Fig. 196) it lies below the tumor at the cerebellar margin, two centimeters away from its former

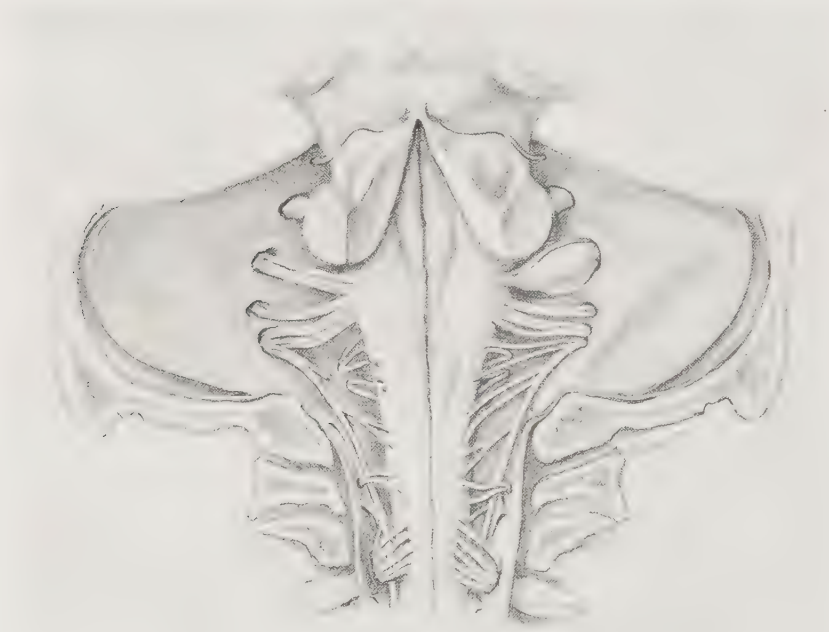

Fig. 193.—Drawing (nat. size) of the brain stem, cerebral nerves, and their foramina of exit viewed from behind. A fictitious early tumor of the right acusticus is shown.

position in what was the angle. It doubtless continues to secrete and there may consequently be a pronounced local disturbance of cerebrospinal fluid circulation owing to obstruction by the tumor of the foramina of outflow of fluid from the cistern. In the absence of tumor, as is well known, chronic inflammatory processes involving this lateral cistern may lead to local accumulations of fluid which may closely simulate, not only in their symptomatology but in their appearance, the fluid accumulations which overlie actual tumors of the angle.

In the operative notes for the cases in this series, the occurrence of a cystic cap on the posterior aspect of the tumor was recorded in thirteen out of the twenty-four cases in which the tumor was

exposed at operation. It is quite probable, however, that it was present though unrecorded in the operative notes of other cases, for in only two (Cases

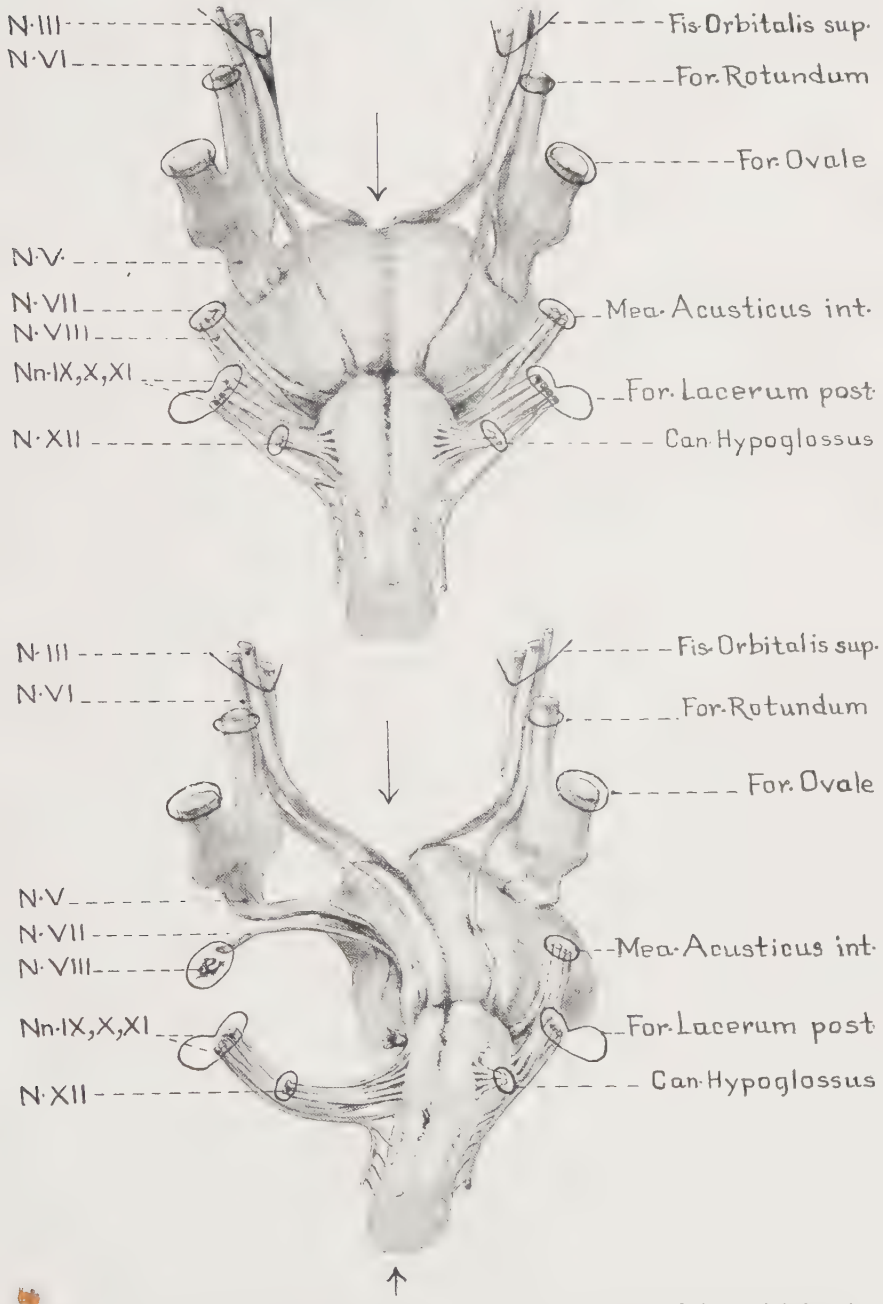


FIG. 194.—Showing from below the normal disposition of the cerebral nerves in relation to their foramina of exit contrasted with the disposition of the nerves dislocated by a right acoustic tumor (nat. size).

XXIII and XXVII) is it specifically mentioned that there was no encysted fluid. Furthermore, it is quite probable, as in Cases IV and XXVIII (on her first operation) and in Cases XXXI and XXXII, that a large number of operations have stopped short of the tumor exposure after the mere evacuation of the encysted fluid enveloping the growth. Needless to say, this covering arachnoid cyst would be difficult to demonstrate at autopsy.

(3) **The tumor in its relation to the cerebral nerves and brain.**—(a) *Distortion of the nerves.* The extracerebral conducting paths from the V$^{th}$ to the XII$^{th}$ inclusive are clustered in very close proximity to one another at the cerebellopontile angle (Figs. 193 and 194). As the tumor arises from the acusticus, this nerve need not be considered in this connection except to recall that it lies midway in the anatomical series. Only in the case of small tumors is the nerve still to be traced, for when the growth has reached such a size as to produce cerebellopontile symptoms, the nerve as such has gone. Occasionally intact fibres (*cf.* Case XXVI) may be detected on or near the surface, as Alexander and Frankl-Hochwart,[5] Jumentié,[92] Bassoe[18] and others have shown, but as a rule they are infrequent and difficult to demonstrate. Such an appearance as that shown in Shattuck's drawing of Sharkey's case (Fig. 185) must be largely imaginary, though in Case XV of this series a small tag (*cf.* Fig. 196) taken to represent the VIII$^{th}$ was detected.

The most striking distortion, when the tumor has reached any considerable size, affects the trigeminal and the facial nerves. In their normal intracranial course they are about a centimeter and a half in length, but they may be elongated to five centimeters or more without appreciably affecting their function.

The *Nervus facialis,* from its immediate proximity to the acusticus, naturally is subjected to distention and compression before the trigeminus, and that it often so effectively escapes serious functional impairment is most remarkable. This is the more so in view of the seeming primary source of origin of many of the growths within the porus where, as it would appear, the facial could hardly escape from the effects of pressure.

The accompanying drawings (Figs. 195 and 196) from the two fatal cases (Nos. XV and XIX) show better than can any description the amazing elongation to which these two nerves are capable. In the drawing (Fig. 196), where both nerves are shown, the N. facialis has become reduced to a paper-thin wisp of tissue as it neared the porus and yet the patient showed merely a slight expressional weakness of the corresponding lower facial musculature. It may be added that the VII$^{th}$ nerve is always found, as would be expected, encircling the upper pole of the tumor, the hemicircumference of which necessarily represents the length to which the nerve has been drawn out. Thus if the tumor were spherical and 3 cm. in diameter, the facial nerve, which runs practically from one end of attachment of the acusticus to the other, would approximate 4.7 cm. in length.

The *N. abducens,* according to my experience, never comes into direct contact with the growth, though it is commonly so described, due, I presume, to a misunderstanding of the relations which has come about from the study

of brains not hardened before removal. Even as shown in Fig. 196, where a nodule of the growth deeply indented the olive, the nerve has escaped from direct pressure. A homolateral abducens palsy nevertheless is common and I am inclined to ascribe it to the same type of vascular constriction to which has been attributed the internal squint so frequently observed in cerebellar tumors of other types.[44]

The *Nn. glossopharyngeus, vagus* and *accessorius* are not only nearer the VII$^{th}$ and VIII$^{th}$ nerves at their origin but also their foramen of exit is nearer to the porus than is the trigeminal foramen (*cf.* Fig. 194). One might expect in consequence of this that these nerves would show clinically the effects of

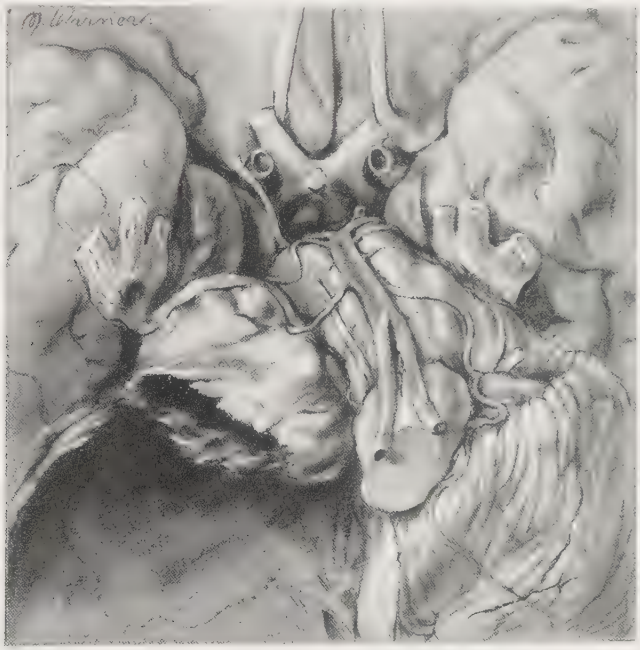

Fig. 195.—Drawing of the tumor and brain stem of Case XIX, showing the great elongation of the N. trigeminus (*cf.* Fig. 97).

compression earlier and more often than they do, for they must be compromised at a comparatively early date and in advanced cases are found greatly elongated and flattened. That they do not more often show clinical signs of functional impairment is probably due to the fact that a slight disturbance in the territory of these nerves is difficult of clinical detection, whereas in the case of the V$^{th}$ and VII$^{th}$ a loss of the corneal reflex and slight emotional asymmetry of the face is a sufficient telltale.

The nerves are found to be more or less elongated and distorted by the lower pole of the tumor in all the cases which have been seen postmortem and in the presence of a large tumor like that of Case XV (Fig. 196) the dislocation may be as marked as in the case of the V$^{th}$ and VII$^{th}$ nerves.

(b) Distortion of the pons, cerebellum and medulla. The deformations of the brain stem itself need little comment. They are often notable and have been observed by all. The pons suffers primarily and becomes indented even by the medium-sized growths

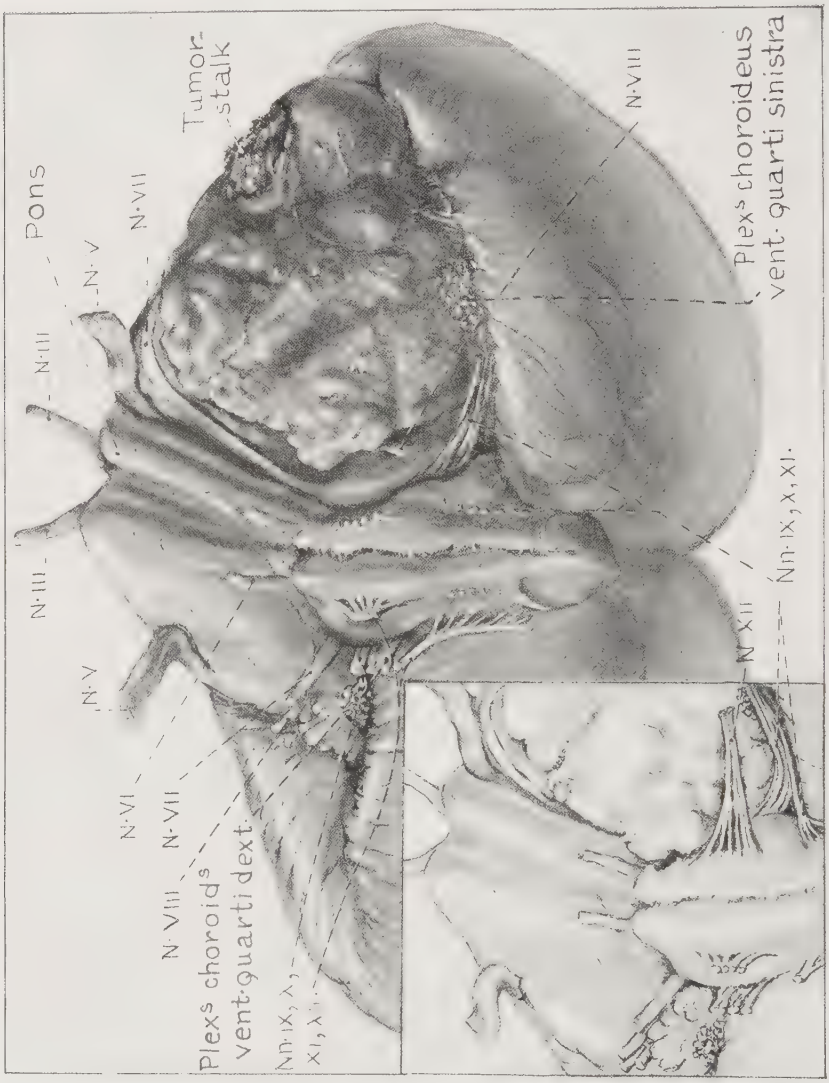


FIG. 196.—Case XV. An acoustic tumor (nat. size: *cf.* Fig. 66) slightly dislocated (*cf.* insert for normal relations) to show the origin of the VII$^{th}$ and VIII$^{th}$ nerves and the distorted arrangement of the V$^{th}$, VII$^{th}$, IX$^{th}$ and X$^{th}$ nerves, the XI$^{th}$ and XII$^{th}$ being cut at their roots. The choroid tuft on the right has been dragged down with the tumor.

(e. g., Fig. 31), but by the larger tumors it may become so flattened that it appears to be little more than half of the original bridge, the tumor almost reaching the median line. The medulla also shares in the moulding by these larger growths (e. g., Fig. 196). The olive may become greatly indented and indeed the whole bulb may be found pushed far to the opposite side.

Even with these extreme medullary deformations no contralateral sensorimotor disturbance may have been observable before death. Herein the spinal cord shows a marked difference from the bulb, for when pressed upon by a tumor sufficiently to cause an indentation, palsies invariably result. This difference probably lies in the fact that, in the case of the spinal tumors, the cord is pushed against an unyielding wall.

The cerebellar distortion may be insignificant or, on the other hand, enormous. The sketches of Case XVI show an extreme degree of dislocation of both upper and lower surfaces: but it may be added that only in case of a decompression to relieve tension would a growth be capable of reaching these huge dimensions. Though the flocculus and the brachium pontis primarily feel the effects of the tumor, in the course of its further enlargement the entire upper portion of the hemisphere may become pushed backward, the lobus quadrangularis above and the tonsil with the lobus biventer below, until the hemisphere becomes merely the nest in which the lesion lies.

(4) **Distant effects of the tumor.** Cases in the stage at which surgical relief is sought, at the present day at least, have a large tumor of the angle which has caused marked secondary complications, due, in the main, to the obstructive dilatation of the ventricles. The tension consequent upon this factor leads not only to bulging of the third ventricle, with more or less pressure absorption of the dorsum sellæ, but to the familiar choked disc with distention of the sheath of Schwalbe.

In addition there occur cerebral herniations of more or less marked degree through all possible openings into which the cortical tissue may become moulded. Notable is the foraminal herniation—the so-called pressure cone at the foramen magnum (*cf.* Fig. 249), the tonsillar lobes of the cerebellum being squeezed down around the medulla and in extreme cases even into the canal as far as or below the arch of the atlas.

Equally characteristic are the minor cortical protrusions which occur at the situations of the arachnoid villi, not only along the margins of the major sinuses, longitudinal, lateral and sigmoid, but also in great numbers over the tips of the temporal lobes (Fig. 66) and spreading up over the surface of the hemisphere in the course of the sphenoparietal sinus which accompanies the middle meningeal vessels.

Scant attention has been paid to these minute cortical herniations for the obvious reason that the envelopes are usually stripped from the brain during the process of removal. They however have doubtless been observed by many and are especially well shown in cases of cerebellopontile tumor in view of the slow progress of the lesion, though they are by no means restricted to these particular growths.

In 1903 Fraenkel and Hunt[59] called attention in one of the cases which they had studied to what they termed "multiple punctate depressions over the temporal and parietal lobes." They had no explanation to offer for these lesions. The true description of a careful histological study of these minute cortical herniæ has been made by Beneke[20] and later by Wolbach,[206] but Cruveilhier[41] evidently understood their nature, and in 1840 Weiglein[194] described them as *Fungi medullares.*

They of course may occur wherever arachnoid villi are to be found, structures which represent the points of exit for the cerebrospinal fluid from the subarachnoid spaces, as Weed[193] has shown. The villi project into the layers of the dura and naturally are more numerous along the parasinoidal expansions of the longitudinal sinus, where pathological dilatation of the villi as granulations of Pacchioni are likely to appear with advancing age.

They are by no means confined to this situation, however, and in almost every suboccipital operation in which some dislocation of the cerebellar hemisphere is required, as in the exposure of a recess tumor, one may see these small cortical protrusions drawn out of their minute pockets in the dura adjacent to the lateral sinus. Due to the internal hydrocephalus resulting from long-standing acoustic tumors, they may be particularly well developed and, as originally described by Cruveilhier, protrusions of considerable size may take place through areas of bone absorption in the cranial base.

We see, therefore, that the gross intracranial changes which an acoustic tumor is capable of producing are of three kinds—those relating to the common seat of origin of the growth in the meatus, those relating to the nervous structures in what is called the cerebellopontile angle, and those which are distant and are attributed to the internal hydrocephalus. We have seen that nearly a century ago Cruveilhier clearly described most of these conditions, and the secondary disturbances were accurately observed by his contemporary Weiglein as follows:

"The sella turcica was entirely abnormal—at the situation of the eminence at its anterior end was found a cavity, and its sides were missing also; its posterior margin, however, was extremely sharp-edged. The fossa itself was unusually deep, almost spherical, and was occupied by a distended cyst filled with water-clear fluid, which was larger than a hazelnut and which at the same time was pressing on the chiasm of the exceedingly atrophied optic nerves.

"The posterior wall of the petrous portion of the temporal bone was entirely absorbed through pressure of the growth, which had enlarged in the shape of a triangle whose base, one inch long, was turned towards the front and whose still more deviated vertex was turned towards the back. The skull was thin, the parietal bones especially being very thin and transparent, and it had practically no diploë; the depressions of the frontal bone corresponding to the convolutions of the brain were unusually rough to touch and bounded by exceedingly sharp-edged protuberances. The surface of the orbital cavity of the frontal bone was of paper thinness; in the right orbital cavity itself, back of the *Fossa lachrymalis*, was an excrescence of medulla-cerebri-like substance the size of a small hazelnut; in the left was another as big as a pea, and four smaller ones, one being still covered by the periosteum; finally, in the left mucous cavity of the frontal bone was found a *Fungus-medullaris*-like excrescence as big as a bean; all of these communicated through little openings in the frontal bone with the cranial cavity, where they were almost equally as big."

## The Histology of the Lesion

These tumors in question have been described under many designations. Though the term "fibrosarcoma" predominates, other terms, which have been met with in cases which appear to be unquestionably acoustic tumors,

are as follows: steatoma of the older writers, fibroma, sarcoma, neuroma, glioma and endothelioma, or combinations of these names, as fibrosarcoma, myxosarcoma, cystosarcoma, fibroglioma, neurofibroglioma, neuroblastoma, neuroglioma, gliosarcoma, sarcoma fusicellulare (Virchow), neuroma fasciculare (Klebs), gliofibroma (Sternberg), neurofibroma (Henneberg and Koch), endothelial sarcoma (Mingazzini), gliomes polymorphes angiomateux (Alagna[3]), fibrocystoma (Langdon[105]), neurinoma (Verocay), fibroblastoma (Borst).

Without doubt an extensive search would reveal other terms, all of which, however, depend largely upon the author's interpretation of the quantitative significance of the relation of the glial and fibrous elements of the particular growth studied. It is probable that the psammomas of the region often attributed (Gompertz[71]) to the sheath of the acusticus are really endotheliomata and of meningeal rather than of endoneurial origin, for so far as I am aware psammoma bodies are not found in true acoustic tumors, though in all probability corpora amylacea may occur.*

Naturally no satisfactory histological description accompanied the accounts of the early tumors, though in a number of them, as in Bell's case (Fig. 1), the gelatinous cystic areas which may reach a considerable size were noted. In 1855 Rokitansky,[150] in commenting upon what he called gelatinous sarcomata, described as "a sarcoma of the dura mater" what from the illustration appears to be an unmistakable acoustic tumor:

> "Eine rundliche an der Dura mater ringsum den rechten Porus acusticus haftende hühnereigrosse succulente gallerartige, hie und da leicht weisslich-opake Geschwulst. Sie bestand hier aus einer höchst zartfaserigen von oblongen Kernen durchsetzten Textur in Form eines Maschenwerkes, das übrige war eine formlose Substanz, in der nebst oblongen viele runde Kerne von 1/200 Mill. Durchm. eingetragen waren. Nebst den Kernen zeigten sich hie und da auch kleine Zellen von 1/100 Mill. Durchm."

Rokitansky's[151] statement, as may be recalled, was to the effect that neuromas occur in all nerves except the olfactory, optic and acoustic, but to this Virchow[187] took exception in so far as the acusticus is concerned, in a short paper on the subject of the nerve tumors.

Indeed little progress has been made since Virchow[190] admitted in 1864 that in spite of the characteristic gross appearance of these tumors their nature is far from well determined. In the cases which he had studied he

---

* I have seen no example of an endothelioma arising from the meatus, all the examples of such tumors in this region having taken their origin from the dura of the petrous bone more posteriorly. They however have been described. Virchow's case[189] is a classical example, and doubtless Fester's[57] cases—cases of what he terms "Fibro-Psammoma von Nervus acusticus und Nervus facialis ausgehend und auf dem Porus acusticus internus aufsitzend"—are of the same order.

Gompertz[71] has observed concentric amyloid bodies in the sheath of the acoustic and facial nerves within the canal, and Alexander with Obersteiner[6] has shown that with advancing years corpora amylacea are commonly seen in the cochlear branch of the nerve where it enters the meatus at the outer limit of the glial elements which it contains, and in an examination of 24 acoustic nerves Henschen states that psammoma bodies were often observed in the perineurium. Goerke,[70] finally, has described the presence of corpora amylacea in the two tumors which he has studied.

speaks of a fascicular arrangement of fibres which resembles a neuromatous structure, and in one case he had little doubt but that the lesion was a true neuroma which had undergone sarcomatous degeneration.

The story of our own relation to the terminology of these tumors has been an illuminating one. The tissues have been carefully examined as they were met with from case to case, but no coördinate study was made of the entire series until recently. Fragments of tissue from all cases in the Baltimore series had been sent to Dr. Mallory, who was good enough to report upon them without knowledge of the clinical symptoms or source of the fragment except that it came from a brain tumor, and the diagnoses returned were either fibrosarcoma or endothelioma—more often the latter.

The tissues from the Boston series of cases had been reported upon by

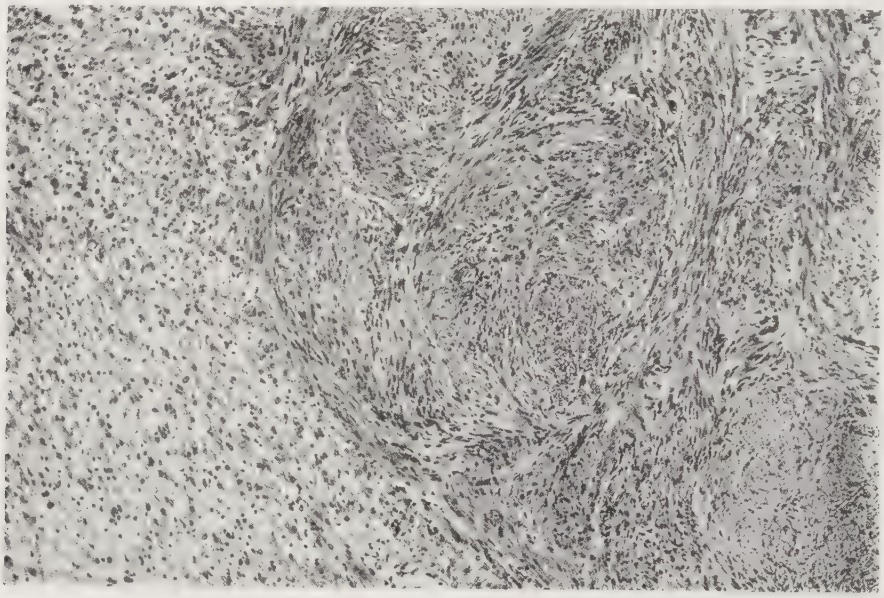

Fig. 197.—Showing (Case VIII) masses of dense interlacing fibrous bands to right and loose reticular gliomatous-like area to left (×80).

Dr. Councilman or his assistants, and the primary diagnosis, which was usually "glioma" (e. g., Case XIV) because of the demonstration of supposed glia fibrils, had in almost all cases been subsequently shifted to "endothelioma," doubtless because of my insistence from the clinical side that these were extracerebellar and benign lesions and could therefore have no relation to the gliomas, for they never extended by infiltration.

The discussion came to a head in connection with the tissues of Case XXII, which had clinically been regarded as a recess tumor of acoustic origin, and this presumption was strengthened by the operative findings. The tissues, however, were so unmistakably glioma that we were induced to review the entire subject, with the disclosure of the fact that we had been glossing over a group of tumors of a perfectly unmistakable and characteristic type and

been designating them, as had our predecessors, by various terms depending upon the chief character of the bit of tissue which happened to be sectioned.*

It became evident at once that the tumors show two main types of tissue, with which we have already become thoroughly familiar from the pathological notes and photographs appended to the case histories. A single fragment may happen to consist largely of one type of cell, and if the diagnosis is based on this alone, the designation of glioma,

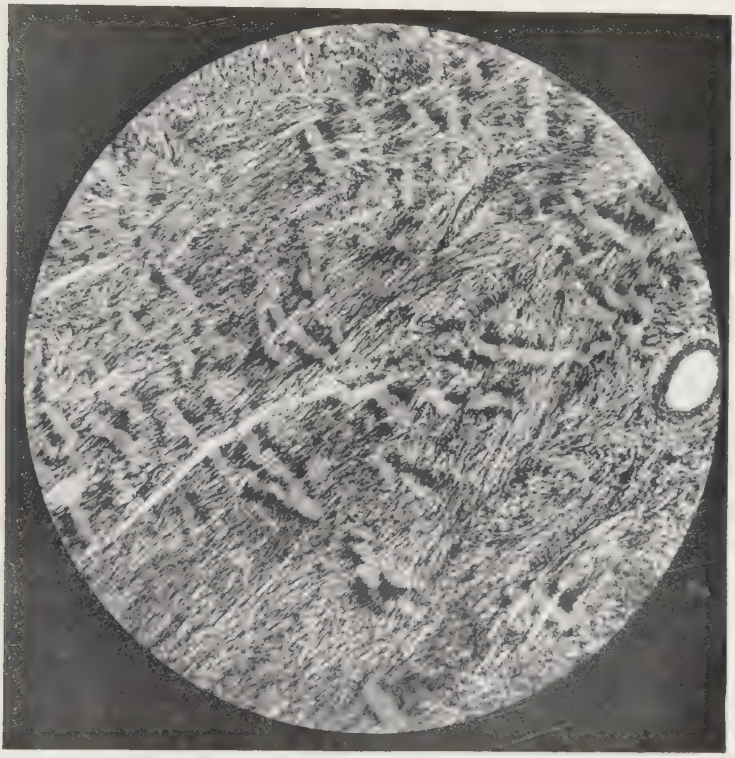

FIG. 198.—Case I. Low power photograph (× 20) of fibrous area showing the regimental disposition of the nuclei entrenched on each side of the collagen zones.

fibroma or sarcoma would naturally be made. These two types of tissue are composed, the one of dense interlacing fibrous bands, the other of loose reticular tissue (Fig. 197). When they occur together the two are in most cases fairly sharply delimited from one another, and either may appear to predominate, depending possibly upon

* Henschen[81] states that in the cases published between 1910 and 1915 the lesion was designated as a fibroma 17 times, fibrosarcoma 17 times, sarcoma 8 times, endothelioma 4 times, neurofibroma 11 times, neurinoma 8 times, glioma, fibroglioma, gliosarcoma, etc., 28 times, while in 20 cases no diagnosis was given.

For example, the series of cases from Eiselsberg's clinic were reported by Leischner as neurofibrosarcoma 1, neurofibroglioma 2, fibroglioma 3, fibroma 1, fibrosarcoma 2.

the age of the tumor or upon its point of origin in the nerve, those of peripheral origin being more fibrous, those of central origin more gliomatous.

The fibrous bands, which often show a tendency to become hydropic (*cf.* Case VI), are composed of masses of elongated cells with oval nuclei. These nuclei have a striking tendency to arrange themselves in more or less orderly fashion, either in parallel rows or in whorls. No satisfactory explanation of the tendency of the nuclei to cluster is at hand. The palisade arrangement* is particularly noticeable in the tissues of Case I (Figs. 198 and 199), and ex-

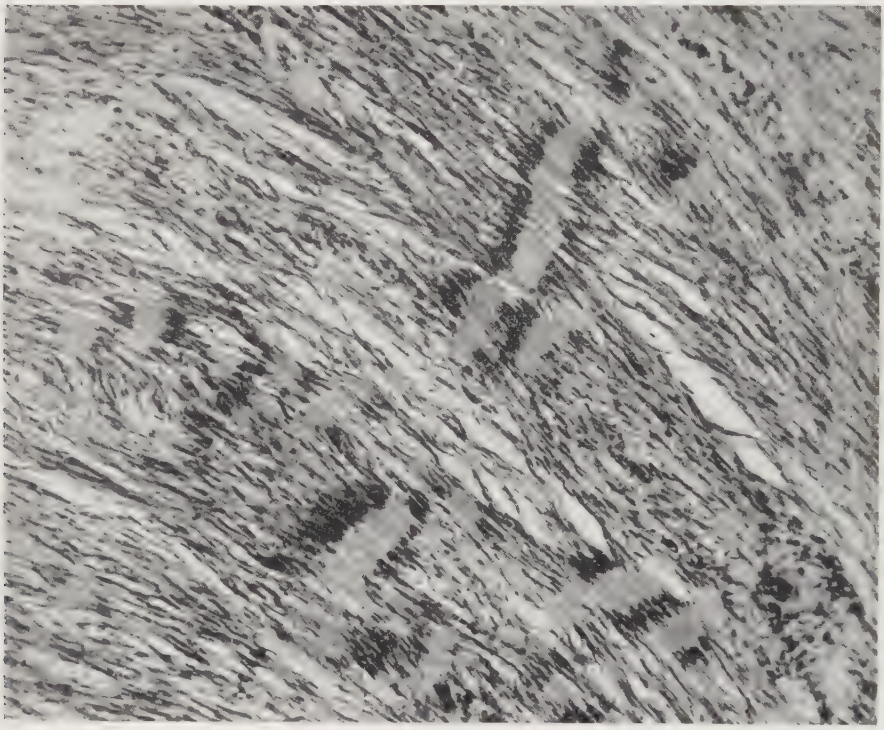

Fig. 199.—Showing (× 150) hydropic fibrous area with palisade arrangement of nuclei. (From Case I.)

amples of whorl formation are apparent in several of the photomicrographs accompanying the case reports (e. g., Figs. 61, 81, 82, 98). The cells may be so numerous in some cases (e. g., Fig. 68) as possibly to justify the designation of fibrosarcoma, but there are no evidences of malignancy in the manner of growth of the tumor, and mitotic figures are of exceptional rarity (Fig. 200). The tissue with Mallory's aniline blue does not stain like a fibroma but acquires a dull purple in sharp contrast to the brilliant blue of the small amount of true connective tissue which

* Dr. Mallory has shown me a section of a uterine myoma with an exactly similar palisade arrangement of the nuclei.

is to be seen about the blood vessels or in the capsule of the tumor. Similarly with the van Gieson stain, on which Henschen lays great stress, the bundles acquire a characteristic tinctorial yellowish-brown reaction with a reddish tone to the collagen fibrils in the nuclei-free zones.

The reticular tissue, on the other hand, appears in areas of greater or less extent between these fibrous bands, and has an œdematous or hydropic appearance, with relatively scant round cells of varying size, with sparse protoplasm lying in a loose tissue network. In this network glial fibrils or near-glial fibrils may often be detected (Figs. 148 and 201) with

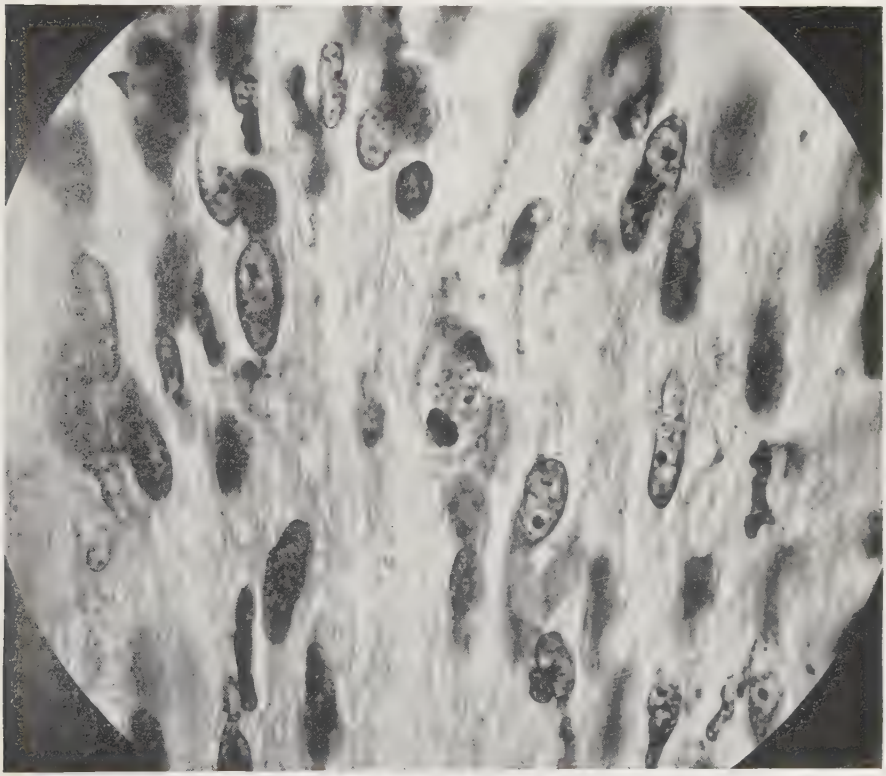

Fig. 200.—Showing, in center of field, a diaster (×1000. From Case XXV. Kindness of Dr. F. B. Mallory).

Mallory's phosphotungstic acid hæmatin stain, and it is on their disclosure that the diagnosis of glioma has naturally hinged. The stain, however, is never entirely satisfying, and in our earlier pathological reports it was commonly stated that the tissue contains fibrils "resembling" glial fibrils.

Occasionally, too, cells suggesting ganglion cells may be found (Fig. 202). Verocay observed them in four cases, and Alagna[3] lays great stress on the presence of these "éléments pseudo-ganglionaires." Whether they are actually tumor cells or merely relics of the preformed gan-

glion cells which occur in the nerve is uncertain. It is the impression of my colleague, Dr. Goodpasture, that at least some of the cells which we have heretofore regarded as ganglion cells may be undifferentiated fibroblasts

Fig. 201.—Margin of fibrous and reticular areas (Case XIII), showing fibroglia and in the reticular area sharply staining fibrils of the neuroglia type (× 600: phosphotungstic acid hæmatin).

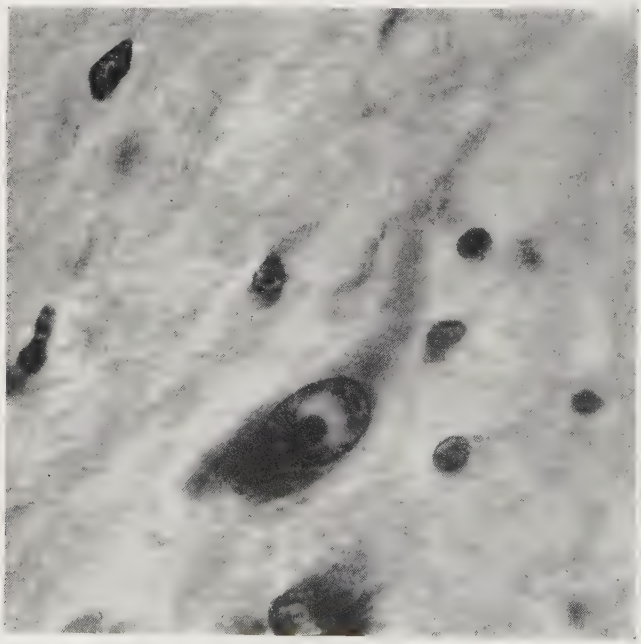

Fig. 202.—Case XXVIII. Probable fibroblast with cytoplasm so disposed as to resemble a ganglion cell (× 1000).

(e. g., Fig. 203), which in some of the tumors are present in large numbers in what seem to be newly forming fibrous areas. These cells have an abundant cytoplasm and sharply staining, often irregular nuclei.

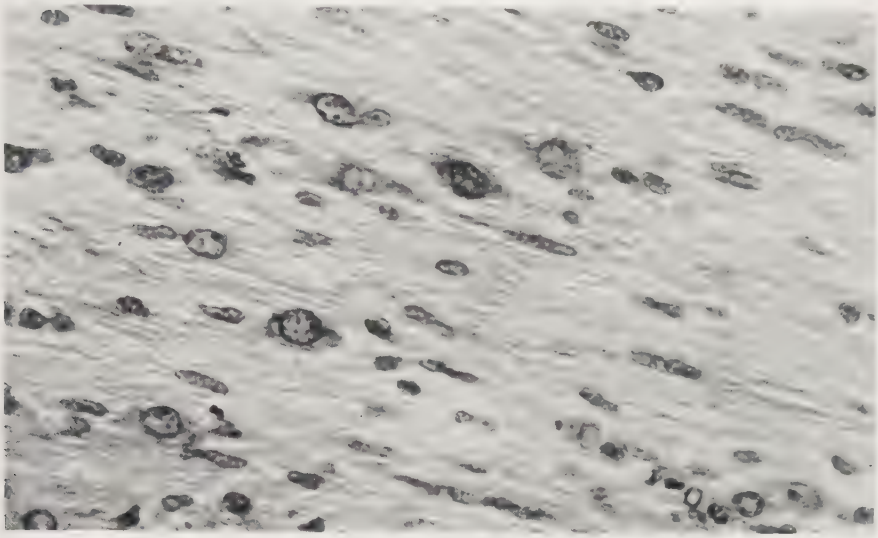

Fig. 203.—Case XXVII. Showing (× 600) young fibrous tissue with cells of varied shapes showing cytoplasm.

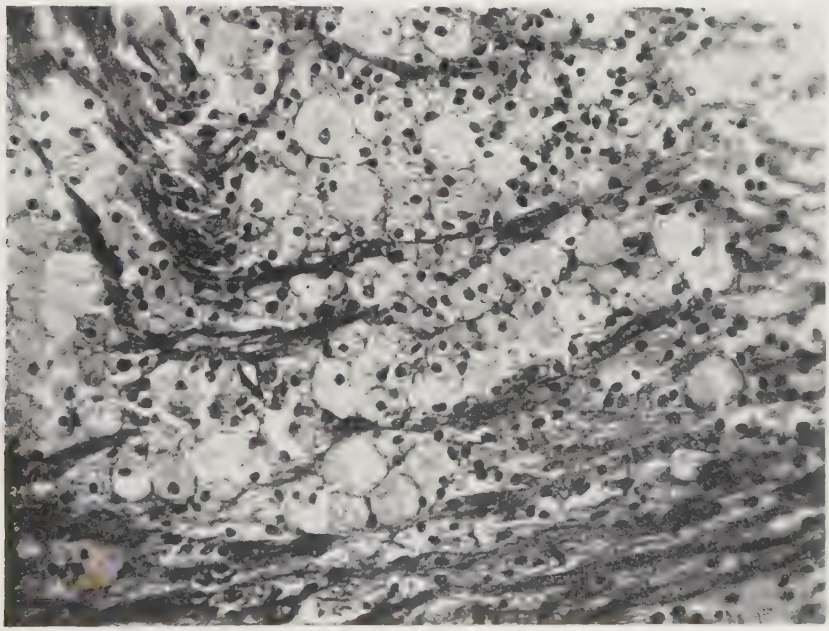

Fig. 204.—Showing fibrous area highly infiltrated with fat cells (Case VII: × 300).

Certain of the tumors (e. g., Case XXI, Fig. 109; Case XXIX, Fig. 164) become extensively impregnated with fat contained in phagocytic fat cells. These for the most part lie between and separate the cells of what appear to be young fibrous bands (Fig. 204). The fat stained with Alzheimer's Scharlach R (Fig. 205) is anisotropic and transmits polarized light with crossed Nicol's prisms. It is found both in and out of cells and is probably largely cholesterin. Dr. Goodpasture regards it as a mixture of neutral fat and lipoid.

Pigmentation also is frequently seen, apparently from diapedesis of blood cells in degenerated areas. Many of the tumors show a marked tendency to become hydropic, and another very

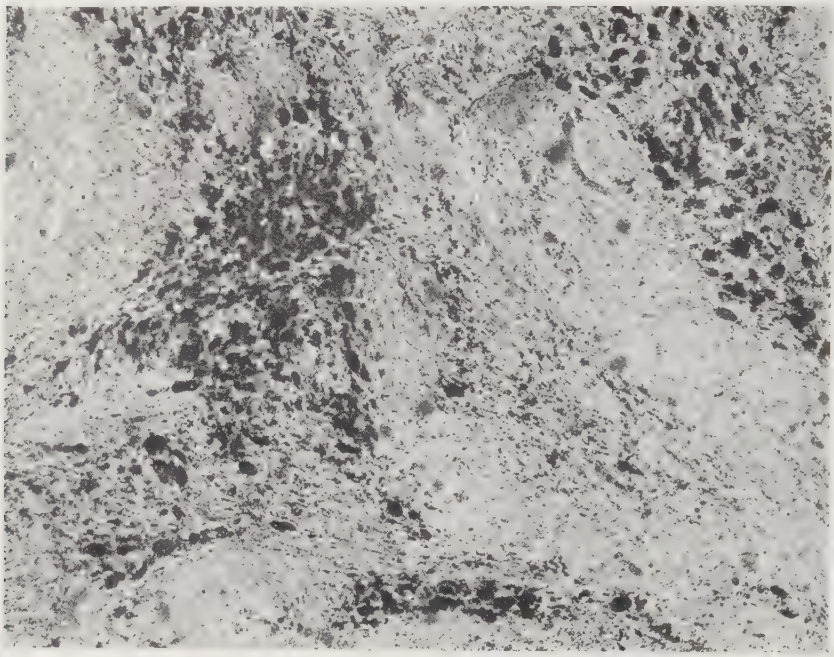

Fig. 205.—Moderately infiltrated area (Case XXIX) stained for fat (× 80).

striking characteristic of the tissue, more or less common in the true gliomas, is the tendency toward hyaline transformation. This occurs particularly about the blood vessels (Fig. 206), but there may be large areas showing little more than hyaline with occasional cells, and cysts may form in these areas just as in the endotheliomata. Hydropic degeneration with cyst formation, however, is far less common than in many of the true gliomas of the brain itself, and the cyst content is often gelatinous and entirely unlike the straw-colored fluid of the true gliomatous cyst. At times the hyaline deposition about the blood vessels assumes a whorl formation (Fig. 207) resembling the formation of the psammoma bodies in the endotheliomata, but lime deposition has not been seen in any of these cases.

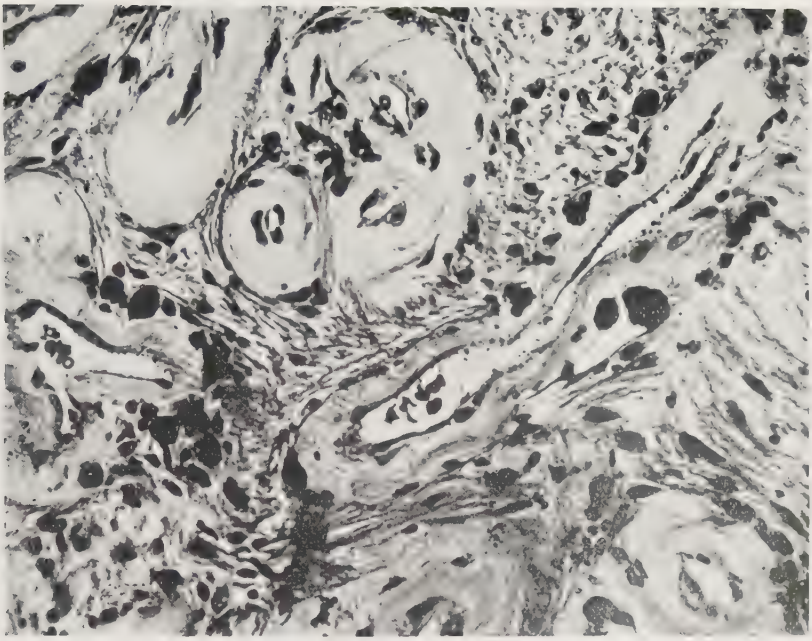

FIG. 206.—Case X. Showing (× 300) hyalinized blood vessels and pigment deposit at the junction of fibrous and reticular areas.

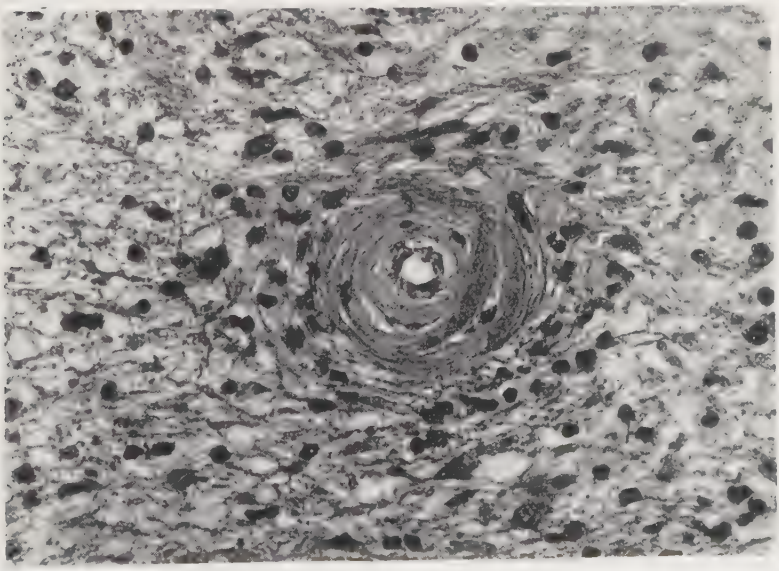

FIG. 207.—Showing hyaline deposition in a whorl about a vessel in reticular field. From Case XIII (× 350).

As a rule the tumors are sparsely vascularized, but in some cases the vessels in certain areas are sufficiently numerous to give to the tumor an angiomatous appearance. Occasionally the presence of nerve fibres, doubtless preformed acoustic fibres, may be detected (Askanazy, Bassoe[18] et al.) in these growths, usually about their periphery, but in none of the large tumors to which our studies have necessarily been restricted have they been observed. The tissue in most cases has merely represented the intracapsular portion of the growth, and the failure to encounter nerve fibres may thus be accounted for.

In summary, the tissue characteristics which make these tumors so definite and unique is the combination of fibrous zones in which the nuclei tend to dispose themselves in palisades or whorls, together with a loose reticular tissue containing glia-like fibrils, in which fat and hyaline metamorphosis commonly occurs.

Dr. Councilman has been good enough to give me the following note which records his impression of most of these acoustic tumors, seen in the Boston series.

"These tumors as a class have a remarkable sameness of appearance and structure. Macroscopically they have an irregular or lobulated but smooth surface. The color is pale yellowish grey with areas more densely yellowish and opaque, corresponding to foci of degeneration, and the section gives about the same appearance as the surface. In consistency they are firm, tough and evidently fibrous, this being evidenced not only by their toughness but by the appearance of fibrous bands and streaks on the cut surface. They are rather dry on section, although small cysts in the interior are occasionally seen.

"Sameness in structure is shown not only in the character of the tissues which compose them but also in the arrangement of these tissues and the forms of degeneration. They have the histological characteristics of slow growth, the nuclear material is relatively small in amount. The nuclei are poor in chromatin, they are closely associated with the generally fibrillar basic substance and rarely show a surrounding differentiated cytoplasm. Nuclear figures are not found, nor is there much appearance of direct nuclear division.

"They contain few vessels and these usually are of the venous or capillary type, arteries being rare. Active growth of the lining endothelium, so common a feature in the glioma, does not occur. Hyaline degeneration of the vessels is common. In the typical cases of this each vessel is outlined by a broad hyaline area which takes the connective-tissue stain. Atrophic nuclei may be seen within the hyaline mass and the lining endothelium is either absent or represented by small shrivelled nuclei. The hyaline forms both within and without the vessel, the lumen is encroached upon, becomes irregular, and the vessel finally closed. The very common areas of necrosis and hyaline degeneration in the tumors are associated with this vascular degeneration and are due to a gradual anæmia. Other vascular lesions, such as thrombi, are not found save the fresh operative thrombi. Hemorrhages other than the operative are rarely found. That they do occur is shown by the not uncommon areas of hematogenous pigment, the granules being either free or enclosed in cells.

"The tumors rarely contain extraneous cells in the form of lymphoid and plasma cell infiltration, although in areas of fatty degeneration large phagocytic fat-containing cells are usually present. Such fat-containing cells often lie in small masses separated by small fibrous bands. Fat is also present in the areas of hyaline degeneration and necrosis in granules and in formless clumps is also contained in the fat phagocytes. All the fat present stains with Scharlach and does not stain with Nile Blue.

"The basic structure of the tumor is fibrous. This tissue occurs in large bands which interlace throughout the tumor and in thin lines separated

by a looser tissue. In part the bands are composed of fine wavy fibrils, in part the fibrils are fused together, the tissue appearing homogeneous. These bands often form whorls converging to a single point as in spindle-cell sarcomas and myomas. The nuclei vary in number, areas rich in nuclei alternating with areas containing few. They are long, contain little chromatin, and are closely associated with the intercellular substance without surrounding cytoplasm. They often show a remarkable arrangement which has been noted by other observers. This is an arrangement in closely packed masses, each nucleus parallel, the mass forming a straight line across the band. There follows an area devoid of nuclei and then a similar nuclear palisade. There are also indications of this arrangement but without the formation of the definite palisades. Such palisades can be continued along a band for a considerable distance in a way suggestive of the striations of a muscle fibre. Between the nuclear masses the parallel fibrils of the band are evident. The condition is more common in areas where the fibrous bands are in whorls. Such an arrangement of the nuclei, which has also been described in the tumors of peripheral nerves, is rarely found in other types of tumors and seems incapable of explanation. The nuclei in the palisades are much more numerous than elsewhere in the bands, even supposing those in the blank places have moved up into the series. It suggests, however, that the nuclei may have moved from the blank areas owing to a strong negative chymotaxis, but there is no analogy for such a condition either in normal or pathological tissues.

"The fibrous tissue itself is peculiar. While it has the structural characteristics of white fibrous tissue composed of fibrils, wavy or straight, often fused, it does not give the staining reactions of this with either the Mallory aniline blue stain or with the van Gieson. With the Mallory stain it takes a reddish-lilac color and with the van Gieson a yellow tone; in both stains there is a sharp contrast with the walls of the vessels and the small amount of collagen tissue associated with them. With phosphotungstic acid hæmatin stain it takes a pale blue.

"In varying amount alternating with the fibrous tissue and often with sharp delimitations is a tissue reticular in character with wide or narrow œdematous spaces and with nuclei in relation with the reticulum. The structure resembles closely certain types of gliomas and it is this which has caused certain observers to apply the term glioma or glio-sarcoma to these tumors. There is nothing which is absolutely distinctive of the glioma save the presence of glial fibrils, although in any glioma there may be areas where such fibrils are not present. Definite glial fibrils were found in two of the tumors, in one associated with the reticular tissue and in the other there were large fibrils in some loose œdematous tissue not distinctly reticular at the edge of one of the fibrous bands. In other tumors, rather doubtful very short fibrils were found in the reticulum. The nuclei in the reticular tissue are round, contain rather more chromatin than do those in the fibrous bands, but have not central round mass of chromatin so often found in the glioma nuclei. They lie at the irregular nodal points of the meshwork.

"Cells strongly resembling ganglion cells were found in one of the tumors. Nerve fibres were never found nor was there any elastic tissue present save in connection with vessels."

I am aware that Dr. Councilman has felt some hesitation in pronouncing upon these lesions without further study, one aspect of which would necessitate a detailed histological examination of the finer anatomy of the cerebral nerves, particularly of the acusticus. Scant attention appears to have been given to this subject, though in 1906 observations by Levi[111] on the posterior spinal roots, and by Hulles[88] on the sensory roots from the medulla were published from Obersteiner's laboratory.* As

* Two years later Alexander and Obersteiner[6] made a special study of the Nervus cochlearis and observed that with advancing age there occurs a deposit of corpora amylacea in the portion of this nerve lying within the meatus, and these bodies occur at the glia septum which really demarcates the peripheral from the central portion of this nerve. This septum, therefore, is much farther out than Hulles had been led to believe.

Lhermitte and Klarfeld[114] and Henschen[51] have more recently pointed out, the auditory nerve consists of two portions which differ genetically and morphologically. The boundary between them lies ordinarily in the porus, though occasionally it is placed a little more distal and, not rarely, a little more central. The distal segment is for the most part constructed like a peripheral nerve with axis cylinders, neurilemma and a connective tissue, endo- and perineurium. In the central segment, on the other hand, the fibres have no neurilemma and endoneurium consists of a glial tissue, just as in the spinal cord. Glial prolongations extend also, in some cases, into the distal segment. As already stated, it is Henschen's view that the tumors develop from the peripheral portion.

This is said to be also true of the trigeminus and, to a lesser extent, of the vagus and glossopharyngeus nerves, which may also be the seat of the tumors. In the acusticus, moreover, the only nerve we have examined, clusters of ganglion cells may be found for some distance from the medulla. The point at which the encasement of glia ends and the fibres become supported by connective tissue and acquire a neurilemma sheath seems to lie at a variable distance from the brain stem in the free portion of the nerve—5 mm., according to Hulles, and much farther out, according to Lhermitte and Klarfeld. Henschen[51] has concluded from the examination of a series of acoustic nerves that the nerve in men averages from 17 to 19 mm. in length and the transition zone between glia and fibrous tissue is from 10 to 13 mm. from the brain stem. In women the nerve averages 16 to 17 mm. in length and the transition zone is from 7 to 10 mm. from the brain stem. He believes also that the transition zone is farther out in the vestibular than in the cochlear nerve. Small patches of glia may be found farther out than the glia boundary.

The histogenesis of the acoustic tumors unquestionably depends upon these two supporting elements, connective tissue and neuroglia, and it is not improbable that the tumors may arise from tissue rests near the zone of transition.* It is not unlikely that tumors (e. g., Case XXII) which appear to arise from the central part of the nerve are richer in neuroglial elements and may even show ganglion cells, for they have been observed in tumor sections by Askanazy, by Verocay,[176] Kolb[89] and Henschen, and their presence has been recorded in some of our sections.†

---

* It has been suggested by Borst[30] that some of the tumors of the peripheral nerves take their origin from the cells of Schwann, so that if these cells really act as neurocytes the tumors might be called true neuromas. In the tumors in question, though Verocay suggested that the cells were closely related to those of the neurilemma, they nevertheless do not possess the characteristic staining reaction of these cells. The relation of glia and neurilemma is not known. According to the older view they were regarded as of connective tissue origin, but of late they are taken to be ectodermal.

† Dr. Goodpasture has made an independent study of fragments from the more recent cases in the series and writes as follows: "The histological architecture of these tumors does not seem to me to necessitate the conclusion that they are composed of two genetically different tissues. Varying degrees of differentiation of fibrillæ, which stain more or less characteristically for collagen, are evident; and the reticular areas may well be regarded as early less differentiated portions of the tumor which may progress to the more fibrous form."

This is quite a new point of view and very possibly in this chapter too much stress has been laid upon the two types of tissue. He has pointed out, moreover, that the ganglion-like cells which had been observed in some of the sections may be nothing more than undifferentiated fibroblasts with abundant cytoplasm (Fig. 202). Inasmuch as the histological aspect of these growths constitutes the most interesting feature of this story, it is important that the views of as many skilled pathologists as possible should be recorded.

We have seen that the tumors vary considerably in the proportion of the fibrous and reticular areas which they possess and, what is more, the tissue comprising the growths seems to be, as it were, transitional, for the fibrous elements do not stain quite like fibroblastic tissue nor are the glia fibrils, if such they are, in the reticular areas often fully formed: then, too, it is notable that the tumors do not possess the invasive characters of the gliomas which arise elsewhere.*

In short, there can be no question but that the lesion is a true nerve tumor,—hence neurofibroma or neuroglioma or neurofibroglioma,—for it arises from nerve-tissue elements even though in this case they are merely the binding or supporting structure for the conducting paths. This, it will be recalled, was Virchow's impression of one of the tumors he had observed, and Sternberg[174] subsequently concluded that they were mixed tumors of a gliomatous nature—gliofibroma—which, however, he attributed to embryonal tissue-rests occurring in the nerve rather than to the fact that the nerve normally contained these complex tissue elements.

Henschen emphatically favors the restoration of the term acoustic tumor, formerly applied by pathologists to these growths but for many years replaced by clinicians by the more general regional designation of cerebellopontile-angle tumor. The latter term, however, comprises a variety of lesions which give a similar clinical syndrome but which involve the acusticus secondarily rather than primarily.

Careful histological studies of these tumors have been made by Verocay,[186] by Jumentié,[92] who regards them all as types of glioma, by Henschen,[91] and many others; among them Henschen's description and conclusions seem to me to be the most dependable. Verocay suggested the use of the term neurinoma for these unmistakable lesions, but inasmuch as his discussion pertains largely to generalized neurofibromatosis it may best be taken up in the succeeding chapter. If as an alternative to "acoustic tumor" a histological designation is preferred, the term acoustic fibroneuroma is probably preferable.

## The Degenerations Produced by the Lesion

In only one of the fatal cases in this series (Case XV) have the degenerations in the corticospinal paths produced by the lesion been studied, and though it is a subject for a neuropathologist, it may suffice to say that despite the large size of the growth the changes observed, as was true of the case studied by Alexander and Frankl-Hochwart,[5] were very slight. Naturally some evidence of degeneration would be expected, dependent upon the extent to which the nerves and brain stem have suffered from pressure, but aside from the changes in the acusticus the degenerations are very inconspicuous. This has been emphasized by Jumentié,[94]

---

* Sézary and Jumentié[162] have subdivided these tumors, which they insist are gliomas, into three types depending largely upon the degree of degeneration which is seen. Jumentié, moreover, describes a gliomatous infiltration of the meninges in his Case 4, and it is not impossible that this may occur in Cases XXII and XXVI of this series.

who finds that of all structures the dentate nucleus shows the chief alteration, but even here they may be very slight even with large tumors.

*The middle ear.* As early as 1871 a careful study of the changes in the middle ear produced by an acoustic tumor was made by Boettcher,[26] and they have since been fully described, among others, by Gomperz,[71] Goerke,[70] Alexander and Frankl-Hochwart,[5] Panse,[136] Funkenstein,[64] Henschen,[79] Quix,[141] Zange[211] and Lange.[106] It has been shown experimentally that division of the acusticus leads to a degeneration in the vestibular branch as far as the vestibular ganglion but not beyond, whereas the cochlear branch degenerates to the ganglion spirale and beyond to its peripheral end cells. This on anatomical grounds is what might also be expected as a result of the lesion in man under consideration, but as a matter of fact other elements, such as pressure disturbances, vascular stasis and other changes due to the long presence of the tumor, serve to modify the experimentally induced picture.

In Panse's case, in which the acusticus was fully engulfed in the tumor with only a few intact fibres remaining, there was atrophy of the ganglion spirale and disappearance of the cells of the organ of Corti. The ganglion vestibulare was also degenerated as well as the peripheral sensory end cells.

In Alexander's[5] case likewise a few acoustic fibres remained within the tumor, but the vestibular apparatus was histologically normal, whereas the cochlear division with the ganglion spirale and the organ of Corti were replaced by connective tissue.

In Quix's case the cochlear and vestibular nerves were completely degenerated, including their ganglia, and yet the peripheral cells in Corti's organ were completely unchanged. He attributes this to the fact that the porus was free and that the stria vascularis and the arteria acustica interna were not involved, his conclusion being that the mere stretching of the nerve does not lead to degeneration of the special sense cells provided the circulation of the blood and lymph remains intact.

In a case in which the tumor appeared to arise from the sheath of the cochlear branch sending a detachable projection into the canal, Zange found the N. vestibularis practically normal despite blood stasis, with extravasation in the labyrinth and vestibular apparatus.

Four post-operative cases from Krause's clinic were studied by Lange,[106] and he points out the high degree of stasis and extravasation and pigmentation which occurs in all parts of the labyrinth, which he attributes to both blood stasis and lymph stasis, whether from the general effect of pressure or the local effect of the growth. The degenerations were variable and in three of the cases inconsiderable, but they tended to support the experimental findings except that the special sense cells of the organ of Corti did not participate in the changes but remained fairly well preserved.

The possibility that a so-called "choked labyrinth," comparable to the well-recognized papillœdema of the opticus, may prove to be a recognizable clinical symptom in cases of brain tumor, is a matter which has been speculated upon but deserves thorough investigation. It is quite probable that the presence of an acoustic tumor will effectually block the cerebrospinal-fluid pathway to the perilabyrinthine spaces, and that in consequence the effect on the labyrinth under these circumstances will be very different from the effect of a mere general increase in tension of the fluid.

The situation is comparable to different effects on the optic nerve and retina under the circumstance of a pituitary tumor which so blocks the optic sheath that fluid cannot be forced along it, and produces degenerative changes without a choked disc, in contrast with the effects of an increase in cerebrospinal-fluid tension produced by a distant tumor. On a similar basis it is not improbable that the functional disturbances in the acoustic nerve so often observed on the side contralateral to the tumor, may be due to the increased tension of the cerebrospinal fluid, causing possibly a secondary atrophy of some sort (*cf.* Case XXX), whereas the changes on the side of the lesion due to the direct pressure of the tumor, are of an entirely different order and are comparable to the so-called primary atrophy of the optic papilla seen in pituitary lesions.

However this may be, it would appear that an acoustic tumor provokes variable degenerative alterations in the internal ear, dependent upon a number of factors—the size of the lesion, its duration, the extent of its penetration into the canal, and so on. These are matters with which the writer has no personal knowledge, and from confused statements in the literature it is apparent that the subject needs further study.

## Summary

The isolated tumors involving the Nervus acusticus arise from the endoneurium which is peculiar to this nerve and gives them their distinctive histological appearance.

They seem to originate, as a rule, in the distal portion of the nerve within the auditory canal and consequently may cause through pressure absorption a dilatation of the porus acusticus internus.

From this point the tumors spread inward throughout the nerve until it becomes completely enveloped. The adjoining structures in the cerebellopontile angle suffer from secondary compression effects. Ultimately an internal hydrocephalus is produced, and the general pressure phenomena of an intracranial tumor rapidly supervene.

The growth is composed of two main sorts of tissue—a dense fibrous tissue and a loose areolar tissue possessing some of the architectural characteristics of a glioma. The tumors are specific for the acusticus and should not be confused with other growths arising in the cerebellopontile angle.

CHAPTER VIII

# BILATERAL ACOUSTIC TUMORS, GENERALIZED NEUROFIBROMATOSIS AND THE MENINGEAL ENDOTHELIOMATA

Though acoustic neuromas, as we have seen, commonly occur as single lesions, examples of an involvement of both nerves are not unknown. However, when bilateral tumors are found they are usually, though not always,

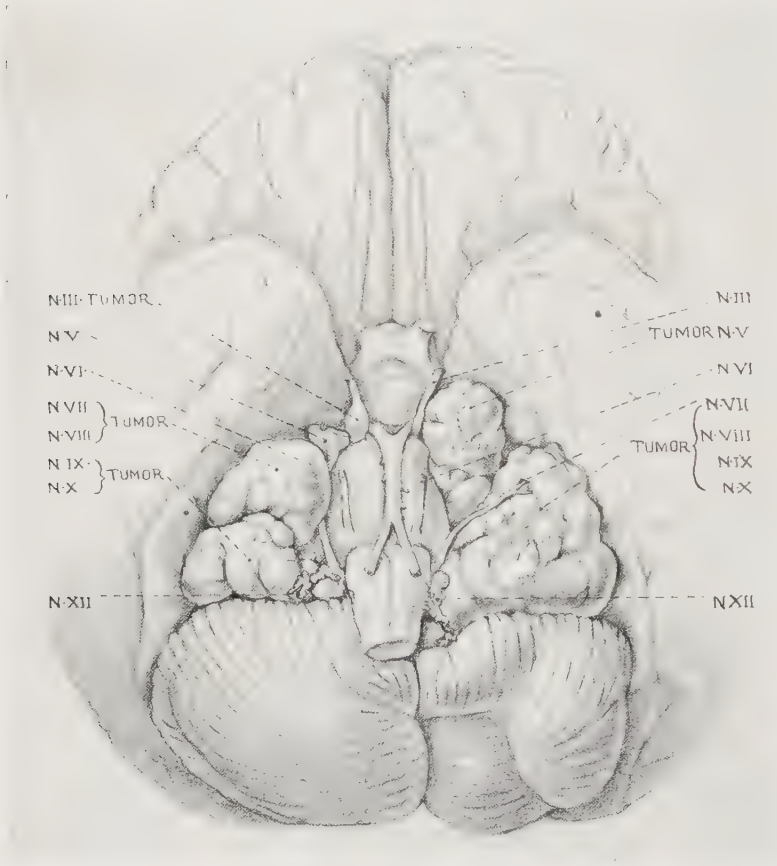


Fig. 208.—An example of multiple and bilateral cerebral nerve tumors in a child of eleven with inherited generalized neurofibromatosis. Bilateral deafness before death. Redrawn from Berggrün.

an expression of a more or less wide-spread disorder characterized by tumefaction of the cerebrospinal and peripheral nerves. Under these circumstances the intracranial symptoms may occur early in life, as in Berggrün's remarkable case of a child aged eleven (Fig. 208).

The earliest recorded examples of bilateral recess tumors in association with central neurofibromatosis appear to have been those of Wishart[205] in 1822* and of Knoblauch[97] in 1843, though wide-spread attention was not drawn to them until the appearance in 1902 of Henneberg and Koch's important study.[78] The first case in their oft-quoted article was a typical one of von Recklinghausen's disease with the usual multiple neurofibromas of the skin, peripheral nerves, extra and intradural spinal nerves, also of the IX$^{th}$ and X$^{th}$ cranial roots with bilateral acoustic tumors of the cerebellopontile angle.

There have been many other similar cases reported, possibly the best known, owing to the distinction of the author, being that which was made the

Fig. 209.—The illustration accompanying Raymond's oft-quoted case report.

subject in 1898 of one of Raymond's *cliniques*.[146] No diagnosis other than that of presumable tumor was made at the time of his first report, but a subsequent autopsy revealed the bilateral lesion (Fig. 209). Since then the condition, though comparatively rare, has become well understood, though ordinarily these bilateral lesions are merely an expression of generalized neurofibromatosis and are more important from the standpoint of the general disease than from that of the involvement of the VIII$^{th}$ pair of nerves. A case has recently been described by Bassoe[18] (Fig. 210), which is of interest from the fact that hearing was preserved in the ear on the side of the larger growth.

* Wishart regarded the tumors as originating from the VII$^{th}$ pair just where they enter the meatus auditorius internus.

Statistics compiled from the literature regarding the relative frequence of isolated and bilateral acoustic tumors are misleading for the reason that the bilateral lesions are so comparatively rare that most of them are likely to be put on record. In 1915 Henschen had assembled the records of 245 verified cases of single tumor and 24 of verified bilateral tumors, usually associated either with generalized neurofibromatosis or what Mossé and Cavaliés have termed central neurofibromatosis. This

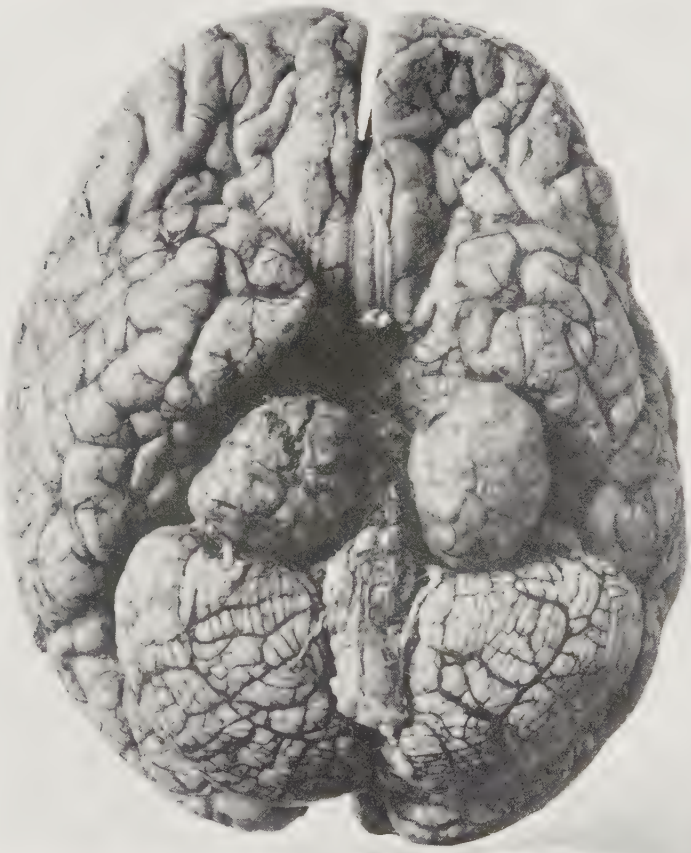

Fig. 210.—Bilateral acoustic neuromas in a case of central and peripheral neurofibromatosis. Some hearing retained on the right. Kindness of Peter Bassoe.

apparent ratio of one bilateral to ten isolated tumors is unquestionably far too large, and one to one hundred or more would actually be a more probable ratio.

No example of a bilateral lesion has occurred among the 23 verified cases in the present series, though, as may be recalled, there were one or two suspects (e. g., Case VIII) owing to the bilaterality of some of the cerebral nerve symptoms and to the presence of some cutaneous soft fibromas. However,

with our present appreciation of the seat of origin of these growths one would hardly venture today upon a diagnosis of a bilateral lesion without bilateral deafness, no matter how wide-spread might be the palsies of the other cerebral nerves. It must be realized that patients with bilateral deafness have been found to have unilateral tumors (e. g., the first cases of v. Voss,[191] and Fraenkel and Hunt[59]) whereas contrariwise, with a bilateral tumor deafness may not be complete (e. g., Sternberg's[174] and Bassoe's[18] cases).

Patients who were found to have bilateral tumors have occasionally been operated upon. Thus, as recorded by Stewart and Holmes,[177] a patient (Case 22) with bilateral tinnitus followed by deafness was operated upon by Horsley, who removed a "fibroma" from the left recess. Eleven months later there was found at autopsy an unsuspected tumor in the unexplored right recess. Funkenstein[64] fully records a case operated upon in 1903 by Garré, who found a tumor in each recess and attempted to remove them: the patient did not survive and the autopsy showed a wide-spread central neurofibromatosis. Similar experiences may have occurred to others.

We have seen in the chapter on symptomatology that, possibly through dislocation of some sort, bilateral cerebral nerve symptoms may be present without there being a bilateral lesion and, indeed, the contralateral symptoms on the part of the V$^{th}$ and VII$^{th}$ may be the more pronounced (*cf.* Case XXIII). A localizing diagnosis, however, must hinge on deafness, which far outweighs all other extracerebellar symptoms in its importance, and the diagnosis of a bilateral process can with safety only be made when there is bilateral deafness (*cf.* Case XXX).

The literature contains many interesting examples, the larger number described on a pathological rather than a clinical basis, but in some of them unusual symptoms had been produced. Thus Stark[170] records a case of bilateral tumor which had led to a secondary internal hydrocephalus with a cerebrospinal rhinorrhœa and which was further remarkable in being accompanied by a bilateral atrophy of the tongue.

Whether any of these cases mentioned in the literature, in the absence of the cutaneous manifestations of von Recklinghausen's disease, were diagnosed before operation or autopsy as having bilateral acoustic tumors, is not apparent nor is it entirely clear whether any of them were unaccompanied by evidences of generalized neurofibromatosis. There is no reason, however, why such a condition should not be capable of clinical recognition, though, as has been told in connection with Case XXX, such a diagnosis was ventured upon owing to bilateral deafness as well as to bilateral cerebral nerve symptoms of other sorts, but events showed that after all the tumor was unilateral.*

---

* Since these notes were written another case, almost the counterpart of Case XXX, has been under observation. There were complete deafness, blindness, loss of taste and smell, with wide-spread cerebral nerve symptoms. The first recorded symptom was loss of hearing on the left, and the stereo-Röntgenograms (Figs. 235, 236) were thought to show an extensive absorption of the petrous bone surrounding the left porus, whereas the right was normal. At operation a unilateral tumor was found on the left. The two cases show that the symptoms which might be expected in case of a bilateral tumor may be exactly simulated by a single tumor of advanced standing and that the diagnosis under these circumstances may depend upon the X-ray findings alone.

## Acoustic Tumors and the Endotheliomata

This present study of the acoustic tumors, as already stated, was undertaken as a digression during the preparation of a monograph upon the subject of the meningeal endotheliomata, with which they had been tentatively incorporated owing to many mistaken histological diagnoses. Obviously they are tumors of an utterly different pathological character. There would, nevertheless, have been some justification in including them with the meningeal tumors in view of the fact that the two types of tumor are so frequently associated that there has been a recent tendency to group them together (Ribbert and Askanazy).

There have been occasional reports (e. g., Langdon[105]: Funkenstein's[64] Case 3, Leischner's[109] Case 7, and Henschen's[79] Case 13) of unilateral acoustic tumors accompanied by multiple "fibro-psammomas" usually situated on the falx. Examples of bilateral acoustic tumors with either "multiple or single meningeal fibro-sarcomas and psammomas" (doubtless endothelial tumors) have also been reported (e. g., Biggs's[25] case and Henneberg and Koch's[78] second case). Moreover, when the acoustic tumors are bilateral they are very apt to be merely a local expression of a more widespread process (central or general neurofibromatosis) of the von Recklinghausen type, and, what is still more significant, multiple endotheliomata of the cerebral or spinal meninges are a not uncommon accompaniment of central neurofibromatosis.

In what appears to be the earliest recorded case of central neurofibromatosis—namely, that of Wishart[205] in 1822—bilateral acoustic tumors producing deafness were accompanied by multiple meningeal tumors, the larger of which had perforated the bone in the fashion characteristic of the endotheliomata.

A later example was given by Fraenkel and Hunt[59] in 1903. The patient had multiple cerebral nerve symptoms, with complete deafness and the usual evidences of cerebellar involvement. The autopsy, which unfortunately was limited to the brain, showed bilateral acoustic tumors, whereas on the dura were more than one hundred separate "psammomata of the fibrous and alveolar variety" (doubtless endotheliomata) of varying size, the chief involvement being along the falx. Corresponding cases, either with single or multiple endotheliomata in addition to the acoustic tumors, have been reported by Askanazy, Leischner[109] (Cases 7 and 10), Funkenstein[64] (Case 1), Verocay,[186] Westphal[198] (Case 2), and doubtless by others.

It is apparent, therefore, that generalized neurofibromatosis, isolated tumors of the acusticus, and fibro-endotheliomata of the meninges are in some fashion correlated lesions. It would seem probable that some anomaly of development of the nervous system and its envelopes must be the underlying factor, for on such a basis could one best account for the multiplicity of these lesions: and it is to be noted in this connection that the more outspoken expression of the

disorder represented by von Recklinghausen's disease even shows an hereditary tendency.

We have been given the opportunity of making a comparative study of the lesions in two cases of von Recklinghausen's disease. In both cases the nerve tumors show the same histological appearance which has been found to characterize the isolated acoustic tumors. The fibrous tissue elements have the same peculiar staining reactions which clearly distinguish them from true connective tissue, and it would be interesting to know whether in the generalized cases the acoustic neuromas also tend to develop from the distal end of the nerve within the porus, but no observation seems to have been made of this.

One of the most thorough studies of this tissue has been made by Verocay,[186] who, as stated in the preceding chapter, suggested the name neurinoma for these peculiar nerve tumors. A summary of Verocay's observations upon one case of generalized neurofibromatosis and four isolated acoustic tumors is of sufficient interest to justify its incorporation here in full.

*Verocay's summary.* (1) The tissue of the multiple nerve tumors, which until a short time ago was regarded as connective tissue, is not connective tissue but a peculiar neurogenous tissue. The nerve fibre cells themselves or corresponding embryonal cells, which possibly have not reached the normal structure of nerve tissue, constitute the basis of the tumor.

(2) The macro- and microscopic picture of the tumor may become somewhat modified under several conditions (distinct abundance in connective tissue, serous œdema with eventual formation of cystic spaces, hyalinoid change of tumor tissue, increase in the number and polymorphous character of the nuclei (Neurinoma sarcomatodes)).

(3) In regard to the nerve fibres, in the case described it was substantiated that there is not only a degeneration of the same (swelling, vacuolization, irregular walls of the axis cylinder) but also a new formation (regeneration), though both to a slight degree.

(4) The fact that ganglion cells are so frequently found in many of these growths is most easily understood if one regards the ganglion cells themselves as an integral part of the tumor and traces them back as a normal development of the same mother cells as the nerve fibre cells.

(5) Gliomas in the central nervous system, which after more particular investigation of cases of multiple nerve tumors is shown not to be such a rare occurrence, form no true accidental combination but stand in close histogenetic relation with the nerve tumors.

(6) The entire process in all probability depends upon an early embryonal disturbance of development of the specific elements of the nervous system, which may have affected cells which are capable of producing ganglion, glia and nerve fibre cells (Neurogliocytes (Held)).

(7) In cases of multiple nerve tumor, especially in the presence of ganglion-cell-holding tumors and gliomas, it would seem correct to speak of a "system disease" of congenital anlage.

(8) The multiple fibro-endothelial tumors of the meninges observed in many cases may also depend upon a congenital anomaly. This may be because of the fact that, under the influence of some faulty development of the ectodermal portion of the nervous system, the adjoining mesodermal elements (later meninges and connective-tissue portions of the nerves) also have experienced a disturbance of development. These elements become the basis for the fibro-endothelial tumors of the meninges. This hypothesis would also make it seem probable that the participation of the connective tissue in the structure of many nerve tumors can be the greater and occasionally the controlling feature of the tumor picture (mixed tumors, fibroneurinoma or neurinofibroma).

This view of Verocay, as will be recognized, is merely an amplification of the conclusions reached by Sternberg ten years before in regard to the development of the isolated acoustic neuromas. In generalized or central neurofibromatosis, as we have seen, many of the cerebral nerves may be the seat of tumefaction, but it is significant under these circumstances that the acusticus rarely escapes. This predisposition of the acusticus to the formation of these tumors is more strikingly shown by their so frequent occurrence as isolated growths and for this fact no adequate explanation has been as yet offered.

## Summary

Acoustic tumors, as a rule, occur as isolated unilateral growths. Unsuspected bilateral tumors, however, have been occasionally disclosed at operation or autopsy. These tumors, moreover, whether single or bilateral, may in rare instances be an expression of generalized neurofibromatosis and the histological character of the lesion is the same whether they occur as isolated lesions or in company with the more wide-spread disorder. Furthermore, multiple endotheliomata of the meninges may accompany bilateral acoustic tumors. Doubtless these lesions are all remotely correlated and are attributable to the same or a similar developmental anomaly.

The isolated acoustic tumors are far more common than the bilateral ones and far more easily recognized. Nevertheless, even in the absence of the telltale von Recklinghausen syndrome, it should become possible to determine, from the clinical symptoms aided by the X-ray, the presence of a bilateral lesion, even though misleading bilateral symptoms may be provoked by a single tumor.

## CHAPTER IX

## DIAGNOSIS

In the introductory chapter I have possibly spoken too lightly of the case of diagnosis of these lesions. Mistakes may of course be made, and it was pointed out 50 years ago by Gairdner and Haldane[65] that cases with single tumors may present greatly contrasted symptoms.

The history of the patient with presumed bilateral tumors (Case XXX) shows how complicated the matter of diagnosis may become, and even such an apparently simple story in its present form as that, for example, of Case XXV, actually gave us a good deal of difficulty, as the provisional clinical diagnosis indicates. When the various blocks are all numbered and there is a plan before his eyes, a child may correctly put together a more or less complicated structure. Just so with a clinical diagnosis. It is very easy where some one has thrown out the irrelevant symptoms and put the significant ones in proper order.

It would be ideal could the lesion be recognized when the acusticus alone is involved, that is, before there is evidence of implication of the other structures in the recess, but so many disorders may cause tinnitus, labyrinthine vertigo and deafness that until the otologist comes to our aid and helps to differentiate the various conditions which occasion these symptoms, we are not likely to recognize *in vivo* the acoustic tumors at this early stage.

When, however, these primary auditory symptoms have been followed by numbness of the corresponding side of the face, by periods of diplopia and lowering of vision, occipitofrontal pain and stiffness of the neck, unsteadiness of gait and ataxia of movements, and in the end by difficulty in swallowing and awkwardness of articulation, we may become reasonably sure of the diagnosis on the history alone. And, after such a history, a tyro could hardly go wrong if the neurological examination reveals a choked disc, cervical rigidity and tenderness, together with the following local signs largely confined to one side: deafness and absent labyrinthine responses, a loss of the corneal reflex or an even more wide-spread trigeminal insensitivity, a lowering of taste perception, an expressional weakness of the lower face, nystagmus, and evidences of muscular incoördination of the cerebellar type. Indeed a correct diagnosis, at least of a lesion in the cerebellopontile angle, is often made by the house officer after a few moments' interview with the patient before his admission.

But it is not always so simple, for with every case there is something new,

and the moment one begins to feel an overweening confidence in his diagnostic saddle he is pretty sure to take a cropper. It is the old story of visualizing a condition so vividly on insufficient grounds as to make all symptoms fit into a preconceived diagnosis. For this reason it is a wise rule never to be told of a previous diagnosis, if this can be avoided, until one has made his own study and come to his own independent conclusion. But even so it is possible for the observer to become lost in the same clinical maze which entangled his predecessor.

Some months ago a neurologist sent a patient with his diagnosis of the case enclosed in a sealed envelope "to be opened in the operating room." Our clinical diagnosis was "a right cerebellopontile tumor: possibly an acoustic tumor despite the absence of deafness." The diagnosis in the envelope was also a "tumor of the right cerebellopontile angle." The operation disclosed an endothelioma arising from the dura and involving the left hemisphere, the cerebral nerve symptoms indicating a recess tumor on the right having been utterly misleading.

Such an experience may not be unusual and a search would doubtless reveal other instances of a similar diagnostic error. Thus in the first case in Henschen's dissertation,[79] a large right acoustic tumor was found at autopsy in a case which had been diagnosed, despite right-sided deafness, as a left cerebellar lesion owing to the extensive left-sided cerebral nerve symptoms. A misplacement of the tumor as exemplified by these cases is merely one form of diagnostic error which may be made in connection with the cerebellopontile-angle symptom-complex.

The more common diagnostic mistakes may be divided into three groups: (a) those in which the tumor syndrome is misinterpreted and the symptoms are ascribed to an altogether different lesion; (b) those with a correct diagnosis of tumor but the lesion incorrectly localized; (c) those with a tumor diagnosis and correct localization in the cerebellopontile angle but the relation of the growth to the acusticus unappreciated.

(a) **The tumor syndrome misinterpreted.**—Errors frequently arise (1) when some of the classical signs are wanting or when some concomitant condition like that of a preceding disorder of the ear adds confusion, (2) when the general picture is obscured by the dominance of some one symptom like trigeminal pain, facial spasm or paralysis, a contralateral hemiparesis of the body, and so on.

A list of some of the erroneous diagnoses which have been made in cases of cerebellopontile tumor, whether or not of acoustic origin and either before pressure symptoms supervene or later on when these are manifest, are as follows:

Ménière's disease (a common error: *cf.* Sharkey[163] and Case IV).

Bell's palsy: tic spasmodique: Jacksonian epilepsy (*cf.* Ziehen,[214] and Case XXII).

Trigeminal neuralgia (*cf.* Lexer's[112] and Weisenburg's[196] cases: also Case I).

Multiple sclerosis (*cf.* Goodhart's[72] case with discussion: also Raymond[146]).

Multiple neuritis of the cerebral nerves (*cf.* Bruns's case: also Case XXX).

Occipital neuralgia (*cf.* Virchow's case).

Torticollis (*cf.* Case XXXVI).

Progressive bulbar paralysis (*cf.* Hubrich's[87] and v. Leyden's[115] cases).

Paralysis labio-glosso-laryngea (*cf.* Morély's[130] case). A bulbar hemisyndrome—luetic (?) (*cf.* Foix's[58] case).

Tabes dorsalis (*cf.* Souques's[168] case, and Case XVII).

Basilar meningitis, tuberculous or syphilitic (a common error).

Meningitis serosa circumscripta lateralis (a common error: *cf.* Case IV).

A gastric disorder (ulcer or carcinoma) (a common error: *cf.* Case XVII).

All of these erroneous diagnoses have been made in cases of actual cerebellopontile tumor, and it must be recognized that mistakes may be made the other way round,—namely, a tumor diagnosis when the lesion proved to be other than a neoplasm,—an aneurysm, an abscess, and, more common than all, a circumscribed collection of fluid in the lateral cistern due to a local chronic inflammation of the meninges.

### Chronic Serous Arachnoiditis vs. Tumor

This local expression of the condition called meningitis serosa circumscripta is above all other conditions the one most likely to cause diagnostic confusion either before or, indeed, even at the time of operation. It is the most common source of what is known as a "pseudo tumor cerebelli," for symptoms typical of an intracranial tumor may be produced thereby and with the customary methods of removal of the unhardened brain a local accumulation of fluid in a slightly thickened arachnoid cistern would be evacuated in the process and thus no lesion would be found to account for the symptoms.

The close symptomatic resemblance between these local accumulations of fluid in the lateral cistern and a true cerebellopontile tumor were admitted by Oppenheim, who in 1905 said: "Die Aehnlichkeit der Erscheinungen zwischen die beiden Krankheiten ist so gross dass es kein sicheres Unterscheidungsmerkmal geben kann." This is especially the case when, as so often happens, the chronic local arachnoiditis is a sequel of an otitis media which has left the ear so damaged as to impair auditory impulses and thus simulate the effects of an acoustic neuroma.

There is one other way in which confusion may arise between these two conditions—namely, through the intermediation either of a lumbar puncture or of an inconclusive exploratory operation.

A fluctuation of symptoms, as we have seen, is a characteristic of true acoustic tumors for reasons which have been ascribed to varying degrees of tension from obstruction of fluid in the enveloping arachnoid (p. 175). The same fluctuation of symptoms and probably from the same cause is characteristic of the conditions of chronic local serous meningitis without tumors. It is well known that a lumbar puncture may serve to temporarily alleviate the symptoms in a case of meningitis serosa, doubtless by the altered pressure conditions which serve to let the encysted fluid evacuate itself. Unhappily the same thing may occur, and for

the same reason, after lumbar puncture in certain cases of true recess tumor. I say, unhappily, not only because a misinterpretation of the true condition is likely to result therefrom but far more for the reason that in the presence of an actual recess tumor the withdrawal of fluid from the spinal meninges by a lumbar puncture is fraught with great risk. The literature contains many examples of death following this measure (e. g., J. Zange[211]).

Not only may these two conditions be confused owing to the fluctuation of symptoms and by the apparent beneficial effects of a lumbar puncture in favorable cases, but they may be confused even during the act of exposure of the recess in the course of an operation. This was pointed out in connection with many of the operations recorded with the case histories, for in the majority of them it was necessary to evacuate an overlying arachnoid cyst before the tumor was disclosed, and if the growth was not readily brought into view and the patient's condition not of the best, the temptation was strong to abandon the procedure at this stage and rely upon a decompression together with the cyst evacuation to give relief, which it usually does, leaving the lesion uncertified. Hence in our series of 35 cerebellopontile-angle tumors which occur in the unverified group, there are unquestionably a considerable number of actual tumors of the angle, not a few of them, as we have reason to believe from recent reexaminations of the patients, being examples of acoustic tumor (*cf.* Case XXVIII).

(b) **Erroneous tumor localization.**—A mistake in localization in the presence of an actual tumor is favored (1) when false or misleading symptoms pointing to an involvement of the cerebral nerves of the recess are produced by contralateral or even by more distant tumors, (2) when the local symptoms are so masked by the general pressure phenomena as to obscure the picture.

Some examples of distant tumor which have been mistaken for cerebellopontile lesions are (1) tumors of the corpora quadrigemina (e. g., cases cited by Bruns, Nothnagel, Weihland) and the error is especially likely to occur when the posterior corpus is involved together with the internal geniculate body which is connected with the cochlear nerve and is the reflex center for hearing: (2) a psammoma of the third ventricle (Higier's[85] case): (3) tumors of the temporal lobe (e. g., Mingazzini's[126] case): (4) tumors of the Gasserian ganglion: (5) of the cortical facial area (*cf.* Keen and Druault[52]): and (6), above all, curiously enough, tumors of the frontal lobe (e. g., Lonque's and Fumarola's[63] and Hermanides's[82] cases).

Particularly in the case of the last mentioned source of error the mistake may work both ways—namely, a frontal tumor (or abscess: *cf.* Ziehen[215]) may be mistaken for a posterior lesion (*cf.* Collier[39]) or, what is still more common, a cerebellopontile lesion may, owing to frontal symptoms associated with general pressure phenomena, be mistaken for a frontal-lobe tumor. This latter error would have occurred in one of the unoperated, and therefore of course uncertified, cases in

my own series had it not been for the fact that the X-ray unexpectedly showed an unmistakable dilatation of the porus acusticus internus on one side, a chance discovery which led to a careful review, with the aid of relatives, of the story of the patient's malady—a review which elicited a different chronology of symptoms from that which had been previously recorded. The patient herself was completely disoriented, blind, deaf, and bedridden. Hermanides's dissertation[82] contains record of a case operated upon by v. Eiselsberg in 1894 under the presumption of a cerebellar lesion, whereas a frontal tumor was found postmortem, and still more striking is the fact recorded by Tooth[181] that in the National Hospital series five similar mistakes had been made. Many other examples of the same error might be cited (e. g., Winkler and Rotgans[204], Obs. XLI).

In case of extreme doubt under these circumstances an important surgical aid in diagnosis is afforded by puncture of the lateral ventricle, either as an isolated procedure or in association with a subtemporal decompression. If the ventricle is found greatly dilated it certifies, or at least favors, a posterior lesion.

The most interesting example of mistaken localization which has occurred in the writer's series was a case (cited on p. 218) of an endothelioma involving the left cerebellar hemisphere with the production of extracerebellar signs pointing toward a recess tumor of the opposite side. Contralateral symptoms, it may be recalled, were not infrequent in the cases of unilateral acoustic tumor constituting this report, and this is a matter of more or less common observation. Just how the nerves of the opposite side may become affected is not clear, and the usual explanation on the basis of stretching from a dislocation of the brain stem is quite unsatisfying, particularly when one realizes to what an extent the nerves on the side of the tumor may be distorted and stretched without serious impairment of function.

(c) **Acoustic neuromas versus other extracerebellar recess tumors.**—We come now to the more important and more refined question of tumor differentiation. In the historical note it was pointed out that fifteen years ago all subtentorial tumors were usually grouped together merely as "tumors of the posterior fossa." Subsequently the extracerebellar in contradistinction to the intracerebellar tumors came to be distinguished and the symptom complex, particularly of those occupying the cerebellopontile recess, was made clear.

It now becomes apparent that the acoustic tumors in the long run can be sharply differentiated from most other tumors which may occur in the lateral recess and of which there are many varieties. As has been indicated, this is a matter which rests largely upon the history of onset—of the chronology of the inaugural symptoms, which only too often are obscure in the patient's mind and not carefully inquired into by the examiner with the idea of a possible acoustic tumor in mind. Without a clear history and with clinical symptoms full blown at the time of the first examination, the differentiation admittedly may be difficult.

There are many lesions which in their advanced stages give typical cerebellopontile-angle symptoms with more or less complete interruption of auditory

and labyrinthine responses, without which, of course, the diagnosis of an acoustic tumor would hardly be made today, though in the past we were less clear in regard to this. In illustration, one or two examples from our series of 12 verified cases of recess tumor which proved to have another origin than the VIII$^{th}$ nerve may be given.

*Endotheliomata of the recess.* In the tumor series of 273 verified cases there have been 55 endotheliomata. Eight of them had arisen from the meninges in the posterior fossa, usually with their point of attachment in the region of the sigmoidal sinus. In none of them was the histological nature of the lesion correctly conjectured before operation.

They are, of course, the most favorable for operation of all cerebellar lesions and have in all certainty been often confused, particularly by surgeons, with the more common acoustic tumors, and not a few of the supposedly total extirpations of the latter have in reality been the more easily and completely enucleable meningeal lesions. This is one reason why the reports in the literature are so difficult to interpret unless detailed histological descriptions accompany the case records, and this unfortunately is rare.

Fig. 211.—Psammoma arising from the porus internus. From Virchow.

As indicated in the foregoing chapters, some of the classical cases which have been widely quoted as illustrations of acoustic tumors appear to the writer to have been in all probability meningeal endotheliomata possibly compressing the acoustic nerve, rather than tumors actually arising from it. The two conditions should be sharply differentiated, as Grasser[74] has also emphasized. An endothelioma, however, may actually arise from the arachnoidal tufts within the internal auditory meatus and give precisely the same symptoms as an acoustic tumor arising from the nerve within the canal. A few indubitable cases have been recorded (e. g., Virchow's case[189] (Fig. 211)), and it is my impression that a histological study would have shown that Sandifort's (p. 2) and Ballance's (p. 245) cases were probably of this character. Under these circumstances the auditory nerve is merely pressed aside like the others and is not actually fused in the growth, as in the true tumors of the acusticus.

None of the eight cases in the writer's series had this point of origin, though in Case XXXIV, which follows, the symptoms were such as might have been expected from a tumor originating in the internal meatus. In six instances no pre-operative diagnosis other than "cerebellar tumor, situation and nature undetermined" was ventured upon. In another case, already cited (p. 218), the lesion was diagnosed as "a cerebellopontile (probably acoustic) tumor" owing to cerebral nerve symptoms, which were utterly misleading, for the tumor was found compressing the opposite side of the cerebellum.

The last of the eight cases of subtentorial endothelioma recorded in Table 3 (p. 17) deserves inclusion here in this chapter for the reason that no doubt whatever was felt as to its being an acoustic tumor.

## Case XXXIV

P.B.B.H. Surg. No. 5489. **Meningeal fibro-endothelioma of left cerebellar fossa simulating an acoustic tumor, with Ménière's syndrome. Operation: extirpation of tumor. Recovery.**

*Sept. 30, 1916.* Admission of Mrs. E. G. K., a trained nurse, 54 years of age, referred by Dr. J. W. Courtney of Boston.

Past history unimportant except for a mastoid operation on the right 14 years ago, since when hearing on that side has been somewhat impaired. No definitely related trauma. A suspicious story of a marital luetic infection.

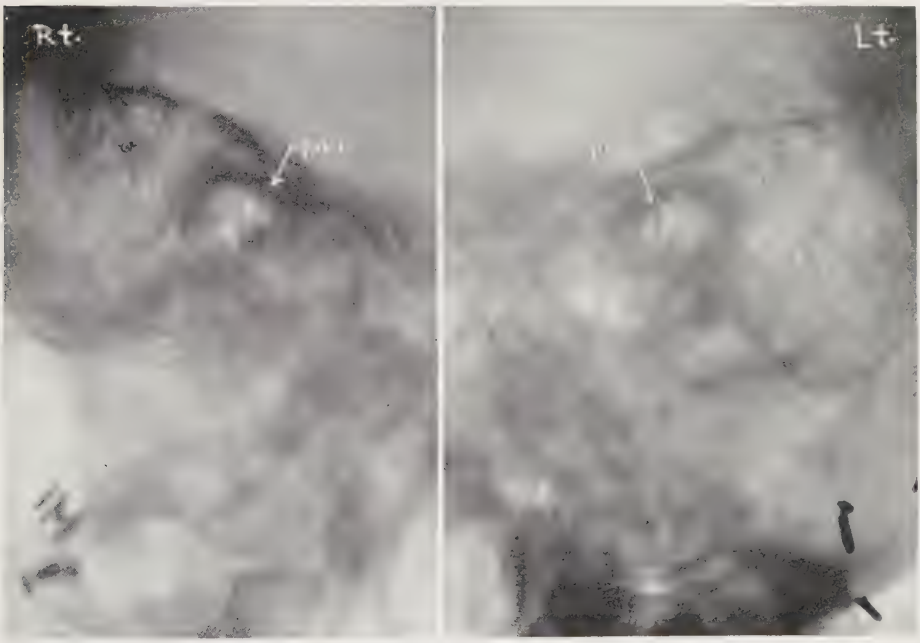


Fig. 212 Fig. 213

Figs. 212, 213.—From the pairs of stereoscopic plates showing normal right and left pori interni (*p.a.i.*).

**Chronology of symptoms.**—Ten years ago a period of severe occipital headaches of sudden onset associated with nausea and vomiting, causing confinement to bed for 4 weeks. Since then occasional spasmodic headaches, usually suboccipital: also occasional vomiting, but never definitely in connection with the headaches. Ever since this illness of ten years ago she has been conscious of a little unsteadiness on her feet.

Six years ago two attacks of sudden unconsciousness with falling: no convulsion.

For four or five years gradual loss of hearing on the left and associated with noises of a "sea-roaring" character, first noticed in connection with using a telephone. She continued at work until a year ago, when attacks of

vertigo appeared, at irregular intervals, described as a "whirring" and turning round of things in her head. Would fall backwards in these attacks if she was standing, but the attacks would be as likely to occur when she was recumbent. Occasional vomiting with the attacks. During the year the attacks became more frequent and severe, and gait became considerably worse.

Six months ago awoke one morning with a tingling numbness of the entire right trigeminal area. This has persisted. No diplopia or facial weakness has ever been observed. Of late considerable difficulty in using mouth—drooling, dysarthria, dysphagia.

The most striking feature of the case were the severe and sudden attacks of extreme vertigo with falling if she was up, and usually an extreme rotation of objects always to the left. During these attacks always has to lie on right side. She had been treated for syphilis and for Ménière's disease. No suspicion of her having a tumor, though seen by many doctors.

Fig. 214.—Case XXXIV. Patient four weeks after operation.

**Positive neurological findings.**—(A) *General pressure.* No choked disc, though the cup and lamina are somewhat obscured by an old process. The X-ray shows slight secondary deformation of posterior clinoid processes.

(B) *Localizing.* (1) *Cerebellar.* A well-sustained, fairly coarse nystagmus on looking to the right: a few coarse twitches to the left, sometimes not obtained. During the attacks of vertigo, however, a spontaneous nystagmus develops, with the quick component to the left. No Rombergism. Gait unsteady: staggers more or less: broad base. Some incoördination of left side: thinks this due to weakness.

Deep reflexes somewhat exaggerated but equal.

(2) *Extracerebellar. Cerebral nerves.* $V^{th}$ = A marked hypæsthesia of the right (contralateral) face, with corneal hyporeflexa. Jaw in median line. $VI^{th}$ = Negative. Never any diplopia. $VII^{th}$ = Negative.

$VIII^{th}$ = Hearing on right slightly impaired. On left: persistent tinnitus for 5 years. Slight perception for loudest voice sounds retained while right ear being irrigated. Left labyrinth inexcitable to caloric and rotary tests. No dilatation of porus on X-ray (Figs. 212, 213).

$IX^{th}$, $X^{th}$, $XI^{th}$ = Marked difficulty of articulation and swallowing. $XII^{th}$ = Tongue slightly to the left.

**Clinical diagnosis.**—"Left acoustic tumor with cerebellopontile-angle syndrome and contralateral trigeminal involvement."

*Oct. 26, 1916.* **Operation.**—Usual bilateral suboccipital exploration. Disclosure of endothelioma attached to dura over sigmoid sinus at posterior part of petrous bone and presenting at lower angle of exposed field. Enucleation of tumor. Closure.

**Post-operative note.**—Considerable post-operative increase in dysarthria, and temporary double vision, but a very good convalescence. Wound healing perfect (Fig. 214). Great improvement in all respects soon appeared. Subsidence of vertigo. Complete




Fig. 215.—Case XXXIV. The tumor (nat. size): endothelioma.

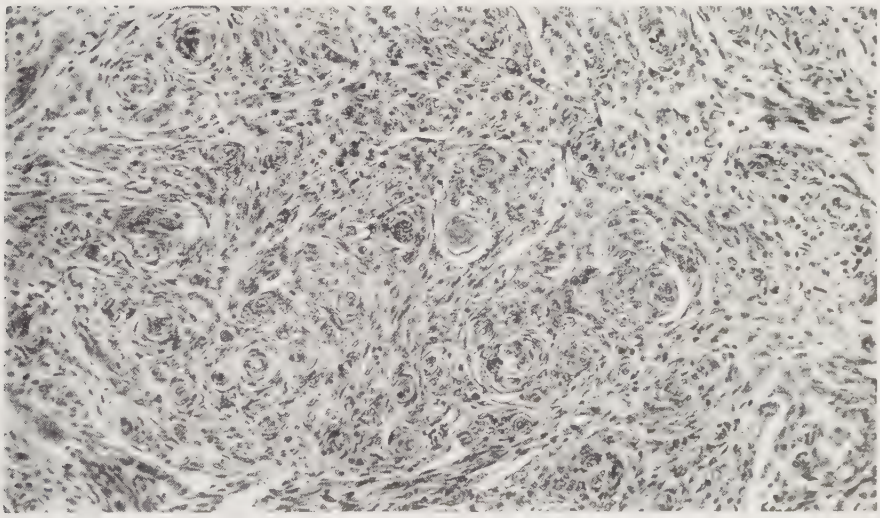

Fig. 216.—Case XXXIV. Meningeal fibro-endothelioma (× 80).

relief of discomforts. Hearing very largely regained. Some nystagmus, unsteadiness, the tinnitus, and the persistent right facial numbness were still present at the time of her discharge. Labyrinth remains inexcitable.

**Subsequent note.**—*Mar. 13, 1917.* Reports for observation. Still some unsteadiness. Some contralateral numbness (subjective and objective) of right trigeminal area. Slight nystagmus. Labyrinthine reactions normal right and left, though auditory function somewhat below normal. General condition excellent. Stereo-Röntgenograms show normal pori interni on the two sides.

**Pathological note.**—The tumor (Fig. 215) is, in gross, characteristic endothelioma, measuring 5.5 cm. in its long diameter. It is intact except at one aspect, where the surface is torn, evidently representing the area of meningeal attachment. On section the tumor shows (Figs. 216, 217) the characteristic architecture of a fibro-endothelioma with numerous whorls, though few psammoma bodies were present.

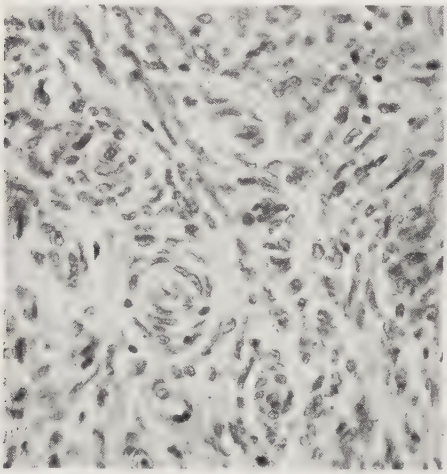

Fig. 217.—Case XXXIV. Higher magnification (× 300) of the tumor.

**Comment.**—The operation in this case was undertaken with considerable misgivings, as the patient was a very stout woman, and it was thought beyond peradventure that she had an acoustic tumor. The finding of an enucleable endothelioma greatly simplified the operative procedure, however, and though the tumor lay in the recess and had seriously affected the acoustic nerve by pressure, the relatively complete restoration of function in the nerve as shown at the last examination shows how different are the postoperative results in this respect from those after operation on true tumors of the acusticus. Without doubt cases of this sort represent the larger number if not the entire number of the reported successful "extirpations" of cerebellopontile-angle tumors.

It must, however, be remembered from what has been stated in the preceding chapter that an acoustic tumor may occur in association with an endothelioma, and had hearing in this case not been restored after the operation, the possibility that a tumor of the acusticus was present in addition to the meningeal tumor would have had to be considered.

---

In the following case, despite the disappointments of three negative explorations, we each time felt certain that there must be a recess tumor which the operation failed to disclose. At the time, admittedly, the differentiation of acoustic from other tumors of the recess was not clear, though we anticipated no doubt that what we now designate as an acoustic tumor and then regarded as an endothelioma was present.

## Case XXXV

J.H.H. Surg. No. 22671. **Papilloma of the plexus quarti ventriculi giving left cerebellopontile-angle symptoms. A subtemporal decompression: three negative explorations of**

**the angle: final transcortical exposure and removal of growth with fatality from pneumonia.**

*July 17, 1908.* Transfer from the medical service, on the recommendation of Dr. H. M. Thomas, of Clayton S., a farmer, 22 years of age, complaining of "headache and weak eyes."

*Past history* unimportant: no trauma.

**Chronology of present symptoms.**—For four months stooping has caused pain referred to his right temple. For six weeks subjective failure of vision: blurring. For one month dizzy spells with a sensation of fainting, but he has never fallen: also diplopia: also some subjective disturbance of taste. A loss of 24 pounds' weight in six months. Of late more or less persistent suboccipital headaches.

**Positive neurological findings.**—(A) *General pressure.* Bilateral choked disc of 3 diopters with hemorrhages and exudates. No X-ray studies.

(B) *Localizing.* (1) *Cerebellar.* Symptoms inconspicuous. A slight nystagmus on looking to left. Romberg positive with falling to left.

(2) *Extracerebellar. Cerebral nerves.* V$^{th}$ = No note on areflexa. VI$^{th}$ = Definite weakness on left with diplopia. VII$^{th}$ = Definite weakness left: incomplete winking: palpebral cleft wider than right.

VIII$^{th}$ = Negative (rough tests only).

**Presumptive diagnosis.**—"A subtentorial tumor, presumably a cerebellopontile lesion."

*July 17, 1908.* **Operation I.**—A palliative left subtemporal decompression disclosing considerable tension: no attempt to puncture ventricle.

*Aug. 7, 1908.* Discharged free from discomforts.

Fig. 218.—Case XXXV. *July, 1909.* Showing subtemporal decompression: palpebral cleft wider on left: tendency to hold head to left.

*Oct. 5, 1908. Readmission* owing to incomplete subsidence of choked disc and continued suboccipital discomforts. Decompression without special tension (Fig. 218). General condition much improved. Gain of 20 pounds' weight. No advance in local symptoms, which remain as before, with slight facial weakness, nystagmus and some unsteadiness.

*Oct. 8, 1908.* **Operation II.**—Suboccipital exploration and decompression. Nothing abnormal was found except a dilated lateral cistern, to which the symptoms were ascribed. Convalescence uninterrupted. Healing satisfactory (Fig. 219).

*Nov. 3, 1908. Discharged.* Subjectively much improved: discs flat: local symptoms unchanged.

*Dec. 28, 1908. Second readmission.* Leading an active outdoor life: walks several miles without tiring: marked gain in weight: no discomforts. No measurable swelling of

discs but slight haziness. Vision 20/20. Possibly some increase in local symptoms. *Discharged.*

*Feb. 8, 1909. Third readmission.* Practically no change in condition over last admission. Thinks he cannot hear so well in the left ear as in the right, but tests show no disparity on the two sides. *Discharged.*

*May 11, 1909. Fourth readmission.* A very evident advance in the local symptoms, shown by increased unsteadiness, especially on arising in the morning. Slight dysmetria of left arm and relative adiadococinesia. Considerable coarse tremor of hands. Extracerebellar symptoms as before. No deafness. *Discharged.*

*Oct. 18, 1909. Fifth readmission.* Definite increase in cerebellar symptoms with considerable weakness and ataxia on left and more pronounced nystagmus.

*Nov. 11, 1909.* **Operation III.**—Suboccipital reëxploration of the left cerebellopontile angle. Evacuation of a multilocular arachnoid cyst containing clear fluid, but no tumor could be identified.

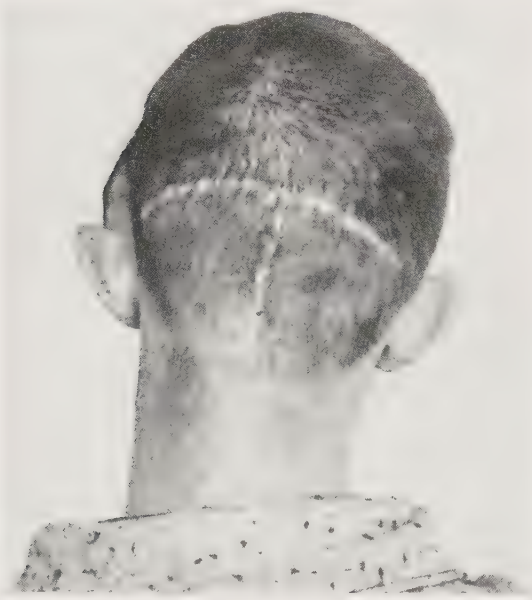

Fig. 219.—Case XXXV. After first suboccipital exploration.

*Dec. 1, 1909. Discharged:* general condition excellent, but local symptoms persist.

*July 28, 1910. Reports for observation.* Considerable unsteadiness and subjective weakness of left arm and leg but walked 2½ miles to train this morning. Subjective numbness of left arm. Complains of drowsiness and sleepiness. No headache or vomiting.

**Neurological findings.**—Positive Romberg: some incoördination of left arm and leg. Nystagmus to right and left: coarser to left. A period of subjective numbness of the right hand. *Cerebral nerves.* II$^{nd}$ = Optic discs flat: slight obscuration of nasal margins. V$^{th}$ = Left corneal areflexa. VI$^{th}$ = No diplopia since first operation. VII$^{th}$ = Slight weakness as before. VIII$^{th}$ to XII$^{th}$ inc. negative.

*Oct. 10, 1910. Sixth readmission.* Complaining of return of suboccipital discomforts. Ataxia, unsteadiness, tendency to deviate to left, nystagmus as before. No tinnitus or deafness: labyrinthine tests normal. Discs flat: vision normal. Some diplopia is present when lying on his back: disappears when erect. Subtemporal decompression remains full: no protrusion of old suboccipital wound.

*Oct. 31, 1910.* **Operation IV.**—Third exploration of left lateral recess. Again a thorough exploration was made in the left recess with no findings other than an arachnoid accumulation of fluid, the evacuation of which completely relieved tension. Exploratory punctures through the left cerebellar hemisphere were also negative.

*Oct. 10, 1911. Seventh readmission.* Other than for some progress in the left-sided weakness with increased unsteadiness and ataxia, the condition remains about as 3½ years ago. Left facial weakness still present; left corneal areflexa; occasional diplopia; loss of taste on left side of tongue; tinnitus

referred to both ears for past two weeks and patient now recalls variable periods of tinnitus since the onset. Tests for hearing and labyrinthine function normal. A slight return of the choked disc with two diopters swelling.*

*Oct. 24, 1911.* **Operation V.**—Fourth suboccipital exploration. The original flaps were again reflected, exposing the cerebellum. The left hemisphere was transversely incised, and at a depth of 1 cm. the smooth surface of a soft reddish enucleable tumor was disclosed. The enveloping cerebellum was carefully wiped from the tumor surface by wet cotton pledgets and the mass was easily enucleated, leaving a smooth-walled cavity except at one point in the depth about at the angle, where was a small remaining fragment of the growth. The great cavity was filled with saline and the wound closed.

Fig. 220.—Case XXXV. Choroid plexus papilloma of left lateral recess causing cerebellopontile symptoms with but slight acoustic involvement (nat. size).

The immediate recovery was excellent but a pneumonia developed to which he succumbed on *Oct. 30, 1911.*

**Pathological note.**—The tumor (Fig. 220) measures 6 by 6 by 5 cm.: definitely encapsulated, with a smooth, highly vascularized surface. The tumor is intact except at one point, where the small fragment remained adherent alongside of the pons. *Histologically* (Fig. 221) the growth is a typical choroid plexus papilloma, containing psammoma granules.

**Comment.**—This case was seen at a time when no more refined a diagnosis than a tumor occupying the cerebellopontile-angle was ventured upon, though

* The patient was seen at this time by Professor Saenger of Hamburg, who also felt certain that there must be a left cerebellopontile-angle tumor, basing his localizing diagnosis chiefly on the loss of the left corneal reflex. An acoustic tumor was not specifically mentioned, but this was doubtless the diagnosis in the minds of all.

I doubt not that we vaguely anticipated finding what we then regarded as an endothelioma and now recognize as an acoustic fibroneuroma. With our present understanding of this latter condition, in the absence of any significant auditory disturbances, the case, despite the involvement of the V$^{th}$, VI$^{th}$ and VII$^{th}$ nerves and the slow progress of the symptoms after the decompression, would have sufficed to show that we were dealing with a recess tumor of another sort.

This patient's history illustrates very clearly the relation of the cerebrospinal fluid disturbances to the local symptomatology. The original de-

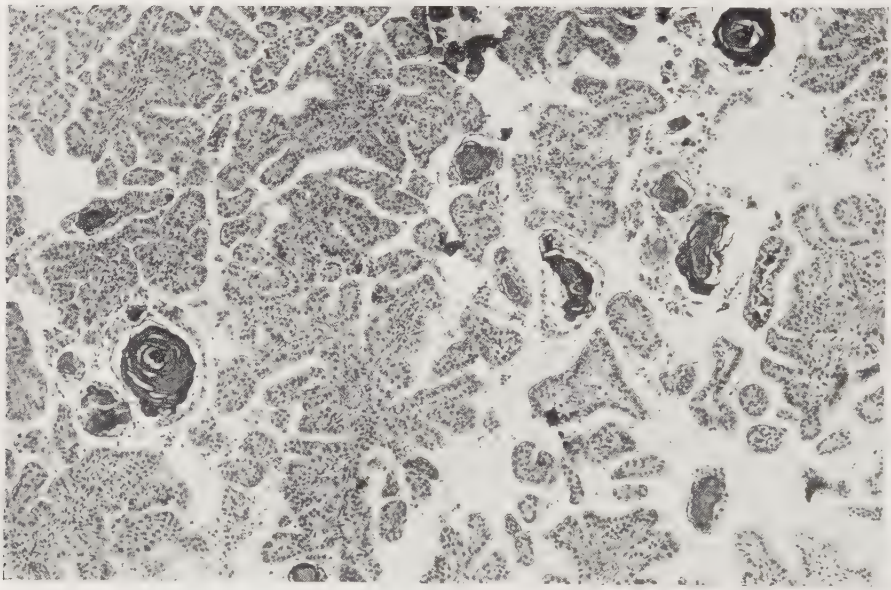

Fig. 221.—Case XXXV. Papilloma of plexus quarti ventriculi lateralis (× 80).

compression served to alleviate the general pressure symptoms and to preserve vision, but the local accumulations of fluid associated with the lateral recess cistern led, from time to time, to an aggravation of symptoms and to three successive explorations, in all of which, though the tumor was not disclosed, a dilated cistern was encountered, an evacuation of which relieved the symptoms greatly for a number of months on each occasion. Had not the final operation been performed the presumable diagnosis would have remained a chronic arachnoiditis circumscripta lateralis.

The following is another example of a cerebellopontile tumor which, despite the absence of auditory symptoms, was regarded, not only clinically, but from its appearances at operation, as an acoustic lesion. The experience shows that the nature of an intracranial tumor may often remain doubtful until it can be put under the microscope, and even then its precise character may remain obscure.

## Case XXXVI

P.B.B.H. Surg. No. 357. **Tumor of the right cerebellopontile angle. Symptoms advanced. Primary suboccipital decompression with exposure of presumed acoustic tumor. Attempted extirpation six months later. Fatality. Ependymal glioma (?).**

*Aug. 29, 1913.* Admission of O. J. R., 36 years of age, a physician, with the complaint of cerebellar tumor. He has suffered all of his life from migrainous headaches.

**Chronology of present symptoms.**—For four years he has had headaches of a new character, at first bitemporal, but for the past two years largely suboccipital: accompanied since the outset with periods of vomiting, projectile, occasionally blood-stained. Diagnosis made of gastric ulcer. No nausea or vomiting of late.

For past eight months symptoms much aggravated. Marked dizziness and vertigo, with severe suboccipital paroxysms, increased by movement and accompanied by spasms of the left trapezius. Diagnosis made of torticollis.

For six months staggering gait, which has become so bad that he is unable to walk without assistance.

For four months blurring of vision with diminishing acuity. Also periods of diplopia and paræsthesias of the left side of the face.

For past two weeks there has been difficulty in swallowing, with choking: thickness of speech; weakness of left face; tinnitus; and failure of memory.

Occasional cerebellar seizures have occurred for the past several months but of late they have become quite frequent and may be precipitated by slight changes in position. They are characterized by agonizing pain with screaming, by extreme opisthotonos to the left, involving entire spine. They usually last fully half an hour and are always accompanied by apprehension of impending death.

**Positive neurological findings.**—(A) *General pressure.* Marked distention of extracranial vessels. High grade of choked disc: 5 D. right, 6 D. left, with exudates and hemorrhages. Photophobia. Severe headache. Frequent vomiting.

(B) *Localizing.* Suboccipital tenderness. Opisthotonoid seizures with contraction and spasm of left suboccipital muscle. Unable to lie on left side: this position produces palpitation and fainting.

(1) *Cerebellar.* Nystagmus slight and variable: coarser to right than left. Marked incoördination, particularly right arm and leg. Station and gait impossible to test. Deep reflexes very active, especially right.

(2) *Extracerebellar. Cerebral nerves.* $V^{th}$ = Slight hypæsthesia over second division, with corneal areflexa. $VI^{th}$ = Negative: history of diplopia. $VII^{th}$ = Weakness of left face, apparent in emotion.

$VIII^{th}$ = Tinnitus; not localized. No deafness. Caloric tests give normal reactions right and left.

$IX^{th}$, $X^{th}$, $XI^{th}$ = Spasms of left trapezius when sitting up. Also flaccidity of left sternomastoid. Some change in voice; vocal cords not examined. Deglutitory difficulty and dysarthria.

**Clinical diagnosis.**—"Right extracerebellar (acoustic) tumor with contralateral symptoms."

*Sept. 2, 1913.* **Operation I.**—Usual suboccipital procedure. A very difficult approach necessitating ventricular puncture to lower tension. Thinning of suboccipital bone. Right lateral recess investigated, exposing what was regarded as a typical acoustic tumor. No fragment taken. Further manipulations contraindicated by patient's condition. Closure without drainage.

**Post-operative notes.**—Marked relief from previous symptoms. Subsidence of choked disc. Cessation of headaches, vomiting and paroxysmal attacks. Unexpected improve-

ment in cerebellar symptoms, with restoration of almost normal station and gait. *Oct. 1, 1913:* discharged greatly improved.

*Feb. 4, 1914. Readmission.* Until two weeks ago has been free from all pressure symptoms. Well enough to drive and to crank his automobile. Marked gain in weight. Recent return of incoördination of right side, though he walks well with a cane, without staggering.

*Examination* shows considerable tension of suboccipital protrusion. Nystagmus more definite than before, with slow jerks to right. Romberg positive with tendency to fall to right and back. Considerable ataxia right arm, with dysmetria, adiadococinesia, etc. *Cerebral nerves.* An early choked disc of 1.5 diopters. Slight left tinnitus and some choking on swallowing liquids, and slurring of speech. No objective cerebral nerve recess symptoms. Caloric tests show normal labyrinthine responses.

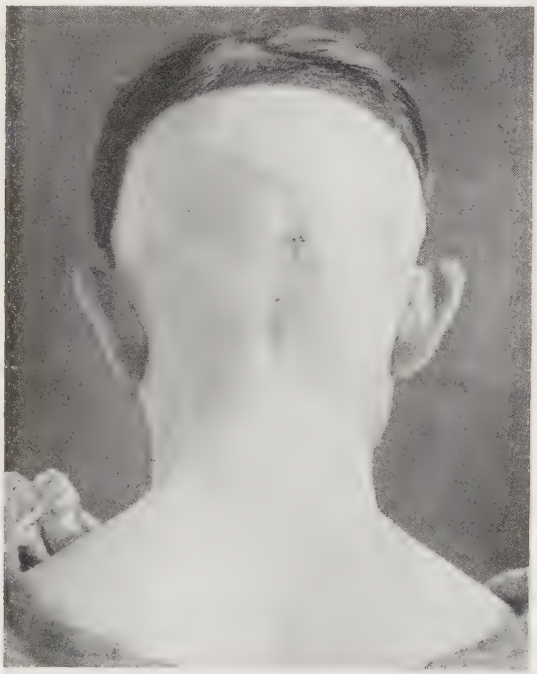

Fig. 222.—Case XXXVI. Before final operation, showing considerable suboccipital protrusion, more on right than left.

*Feb. 13, 1914.* **Operation II.**—Owing to the old operation it was found impossible to re-expose the tumor in the recess by an extracerebellar route. Consequently the right cerebellum was transected and the vascular wall of a cyst was exposed and partly freed by blunt dissection before it ruptured. The wall was tough and could be fairly well handled. At the base of the cyst was a vascular soft tumor, a large mass of which was scooped out by blunt dissection, provoking sharp hemorrhage, which was controlled with some difficulty by the emplacement of a large square of muscle taken from the gastrocnemius. Immediate transfusion.

**Post-operative notes.**—For some time his condition remained critical, with rhythmic respiration and poor pulse, so that he was left on the operating table for some hours. In view of this his recovery was surprisingly rapid and he was discharged on *March 6* greatly improved, with his discs flat and free from discomforts.

*July 10, 1914. Readmission.* His period of relief was short, and after three months the discomforts again returned, with considerable protrusion of the suboccipital wound (Fig. 222).

*July 16, 1914.* **Operation III.**—The wound was reopened: a large vascular enucleable tumor was exposed and its removal attempted. There was considerable hemorrhage, controlled with difficulty. He succumbed from loss of blood and shock after some hours.

**Pathological notes.**—A postmortem examination showed the tumor to have been completely removed, but extravasations of blood had spread into the ventricles and had doubtless been the immediate cause of death.

The growth, a most peculiar one, was called by Dr. Councilman a "telangiectatic glioma of unusual type" (Figs. 223 and 224). It is a most peculiar tumor, containing many

cystic spaces and cells of a highly differentiated character with an alveolar arrangement. Between these cells there lie many typical glia fibrils and were it not for the presence of these fibrils one might consider the tumor to be a carcinoma. The growth has been seen by a

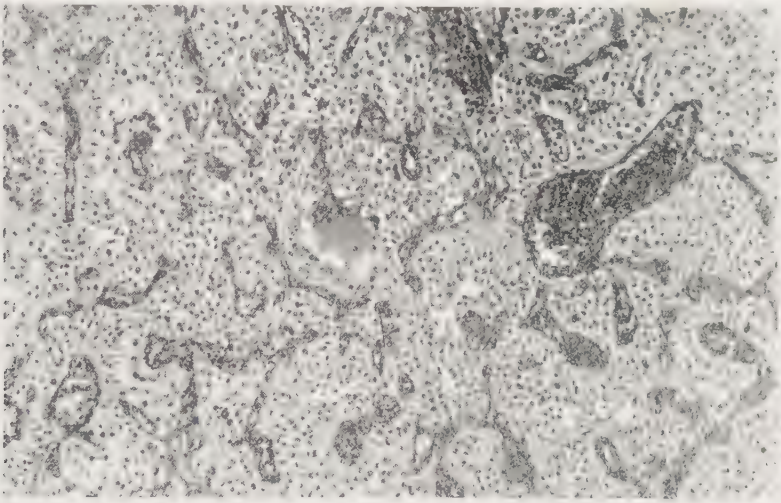

Fig. 223.—Case XXXVI. Low power, showing the peculiar architecture of the growth.

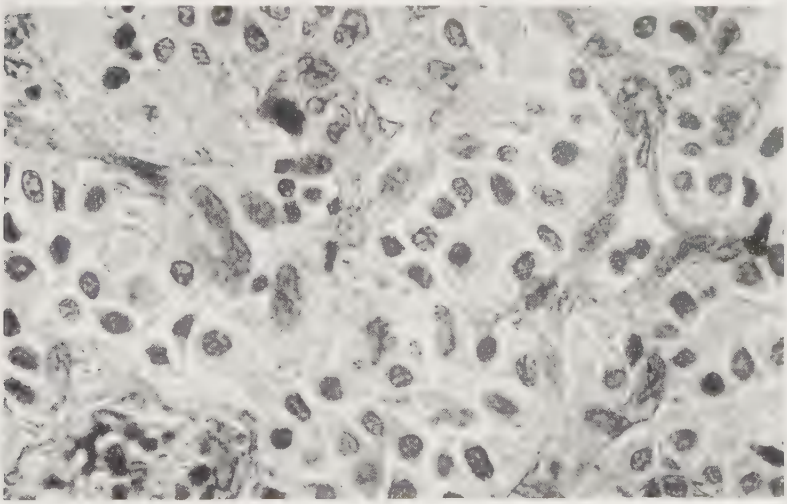

Fig. 224.—Case XXXVI. The same, higher magnification (glioma: × 360).

number of pathologists, and the consensus of opinion seems to be that it resembles most closely certain ependymal gliomas, such as those occasionally seen in the coccygeal region. Dr. Goodpasture, however, suggests that the tumor may possibly be a tumor of choroid plexus origin and that the fibrils are fibro-glia rather than neuroglia.

**Comment.**—Though this case was under observation only three years ago and the situation of the lesion in the right recess was clear, we were at that time still confused in regard to the differentiation of these recess lesions. The patient, a physician much interested in our study of his symptoms, appeared several times before the class, and though the diagnosis of a right cerebellopontile-angle tumor was made and tinnitus was present, the significance of retained hearing and a labyrinth responsive to caloric tests was not appreciated.

Moreover, when the lesion was exposed at the first operative session it so simulated the usual recess tumor, endothelioma as we then termed it, that no doubt was felt as to its character. This is a good illustration of the caution which must be exercised in making a diagnosis of a lesion on gross appearances alone without its being certified by a histological examination.

Before the first operation, the evidences of cerebral nerve involvement were slight, and such as they were they had completely subsided by the time of his second admission. This would not have occurred in the case of an acoustic tumor.

The three cases whose story has just been fully told come as close as any in their symptom complex to the VIII$^{th}$ nerve tumors, and yet the one essential chronological item of early tinnitus and following deafness was lacking. Nevertheless until the lesion was actually exposed, they were all three doubtless regarded as presumptive acoustic tumors.

It is true that in the last case an erroneous clinical diagnosis was thought to be supported by the gross appearances of the lesion disclosed at the first procedure, and in order to show how easily a glioma of the cerebellopontile recess may confuse an operator who approaches it from alongside of the cerebellum, the following illustration (Fig. 225) of such a lesion may be given. The tumor, as can be seen, has invaded the lateral recess, engulfed the local cerebral nerves, and poured itself over the pons, but the chief rounded mass of the growth occupies a mould in the anterior part of the right cerebellar hemisphere, where on being approached from behind it would have closely simulated a primary tumor of the type with which this monograph deals.

As a matter of fact, the tumor shown in this figure occurred in a child and it may be recalled, since it is of some diagnostic significance, that acoustic tumors are rarely, if ever, seen in the first two decades, but give their first symptoms, as has been pointed out in an earlier chapter, most often in the fourth. But even this we must take with reservation, for, as was true of Case XXIX of this series, so one of Henschen's patients (Case 35), 53 years of age, had been deaf from childhood, and Henschen is inclined to believe the tumor had existed from that time.

These few illustrations from our series of 19 certified tumors in or near the cerebellopontile angle which have proved to be other than lesions of the acusticus, may suffice to point out the chief differences in symptomatology. Many other examples might be given of growths arising (1) from the

middle ear or the pyramidal bone itself: an endothelioma (Grasser[74]): an epithelioma (personal observation): a myxofibroma (Bielschowsky and Schwabach[23]); or (2) from the base of the skull: sarcoma, adenocarcinoma and endothelioma (personal observations); tumors which penetrate the jugular foramen and protrude into the angle, giving extracerebellar symptoms; or (3) from the meninges: endothelioma or angioma (McCaskey[122]), and these above all others are most common and may most closely simulate the acoustic tumors. Then (4) a variety of other tumors or lesions

Fig. 225.—Pontile glioma in a child, extending into the right recess in such a way that when exposed from behind it might be easily mistaken for an acoustic tumor.

simulating tumor have been known to occur in the recess or become implanted there and give symptoms which might be accredited to an acoustic tumor: arachnoid cysts and cysts of the lateral choroid plexus (Virchow,[188] Sutton[180]): cholesteatoma (Eichelberg,[53] Babinski,[12] Püschmann[142]): teratoma (Kato[93]): epithelioma (Gowers,[73] Bruns[38]): cysticercus (Hildebrand,[86] Schlesinger,[157] Wollenberg[209]): psammoma of the choroid plexus (Sutton[180]): tuberculoma (Rosenthal,[153] Alquier[7]): syphiloma (Rosenstein,[152] personal observation): glioma (Lhermitte and Klarfeld[114]): metastatic tumors, such as adenocarcinoma (Siebenmann[165]): sarcoma (Jakob,[90] Trömner,[185] Biggs[24]): carcinoma (Bruns,[37] Bregman,[33] Bramwell[32]): pial

abscess (Weisenburg[195]): cerebellar abscess (Joffé): aneurysm (v. Monakow,[129]) and the list might be indefinitely prolonged with other illustrations.

It is not the purpose of this monograph to go into details concerning these multitudinous lesions which may arise in the recess and produce so-called cerebellopontile symptoms. They are only mentioned as being examples of lesions with which acoustic tumors have heretofore been grouped and more or less confused.

As a matter of fact, with our clearer appreciation of the importance of the chronology of the symptoms for the recognition of an acoustic tumor, we are likely to err only in the case of chronic serous arachnoiditis, of endothelial psammomas originating from the porus, and of true tumors of the acoustic, which possibly arise in its free portion (e. g., Cases XXII and XXVI).

There are two points in connection with the physical examination which deserve special note in this chapter on diagnosis. These concern the X-ray examination and the Bárány tests, both of which necessarily have been taken up in more or less detail when discussing the symptomatology of the lesions.

**Radiographic changes in the sella and porus.**—It is generally appreciated that every patient with a suspected brain tumor should be subjected to an X-ray study of the skull. In far the larger percentage of cases, it must be confessed, nothing of significance is revealed until the evidences of increased pressure appear, as shown (1) by a widening of the sinusoidal grooves and dilatation of the diploëtic vessels, (2) by a pressure absorption of the posterior clinoids, particularly when there is an internal hydrocephalus, or (3) by a diastasis of the sutures and a deepening of the convolutional impressions, changes confined largely to the early years of life.

Local indications of the lesion, however, may be disclosed, such as the bony thickening or bony absorption which may overlie the meningeal endotheliomata; or a growth itself in rare cases may cast a shadow if it happens to have extensive calcareous depositions, though the latter is unhappily rare. With the exception of the possible disclosure of the outline of the growth itself, these things are merely supplementary, and the X-ray gives, therefore, little more than confirmatory evidence of what the physical examination has already revealed.

There is one condition, however, in which the Röntgenologist's aid has become indispensable, and that is in pituitary disease. Our advances in this direction are the more striking when one recalls the vagueness of our knowledge of the sellar outlines of but a few years ago, long after Jacobson and Oppenheim first drew attention to the subject. As already noted, any posterior lesion which produces an internal hydrocephalus leads almost inevitably to some distention of the sella and to a thinning from absorption of its dorsum and base. Apparently in the presence of these recess tumors one sometimes sees an additional deformity, to which Schüller[159] has called attention—namely, a canting forward of the thinned dorsum from its usual erect position. This we have observed in several cases (e. g., Figs. 120 and 149), but it is

difficult at present to say whether it will prove to be of any actual diagnostic significance.

*The porus acusticus internus.* As in the case of the sella in pituitary disease, so with the porus in acoustic tumors we may look forward with expectation of a similar advance in our appreciation of the demonstrable radioscopic changes which may occur and to which Henschen[80] in 1912 first called attention.* Confessedly at the present time, and in view of the difficulty of the technique, some doubts must be felt as to the few observations which have been recorded as positive. A single observation or two without stereoscopic plates and comparative studies of the two sides may be most misleading, as we have painfully learned. On one occasion the porus on the side contralateral to the tumor, as was true in one of Henschen's[80] cases (Case 27), appeared to be the larger: on another, what was taken to be an abnormally large porus internus was observed when there were no acoustic symptoms: in others the demonstration of an unmistakable enlargement has been made after many unsuccessful attempts. Then, too, it must not be forgotten that the porus may become enlarged by growths in the recess which do not primarily arise from the acusticus, such as endotheliomata which may invade the canal and lead to a pressure absorption of its walls.

For the purpose of further detailed study of the conditions, as many of our patients with verified acoustic tumors as could return for the purpose have been re-examined with this particular point in view, and it was disappointing to find in how few of them Drs. Carr and Grey, who first devoted themselves to this quest, were able to demonstrate any enlargement of the canal.

As can be seen from the occasional X-ray prints accompanying the case reports, we were long doubtful as to the best position of the patient's head for the exposure. In some instances (Fig. 89) all four meatus have been projected on one plate, where they can be compared. In others the temporal bone near the tube has been eliminated by forward projection (e. g., Fig. 143): in others it has been projected downward (e. g., Figs. 132, 133) and this doubtless is the best position, though one may occasionally (e. g., Fig. 138) secure a clear view of the meatus even in a badly disposed arrangement.

Whether or not it is desirable to have the shadows of the internal and external pori superimposed or to have the internal thrown slightly above (e. g., Figs. 150, 151) or to the side (e. g., Figs. 175, 176), must await the decision of further experience. At best the correct interpretation of single plates, however, is practically impossible except in the case of an unusual area of absorption,† and not until we recently came to employ stereoscopic exposures as a routine have we been able to secure satisfactory views of the local conditions.

Most of our studies have been made on cases that have come under observation subsequent to those whose clinical histories have been given in Chapter

---

* His Case 33 of the 1915 series, a patient with symptoms of fifteen years' duration, appears to have been the first in which the diagnosis was aided or assured by the X-ray. At the time he could find records of only seven cases in which X-ray studies had been made.

† Since this writing a patient showing what was supposed, for the first time, to be an unquestioned enlargement of the porus internus was admitted to the clinic. It was found that the tumor did not extend into the porus.

IV, though, as related, several of the patients in repeated series have been re-examined. These later studies have disclosed some of the sources of our early misinterpretations, and have shown how the slightest change in position will

Fig. 226

Fig. 227

Figs. 226, 227.—Case XXVIII. Showing the different appearance which may be given to the pori on the same side by the slightest change in position. On the right the "collar button" appearance is well shown.

Fig. 228

Fig. 229

Figs. 228, 229.—Position I of the right and left porus of Case XVIII, showing what might have been taken to be a dilated right and a normal left meatus internus: tumor actually on left (*cf.* Figs. 230, 231).

alter hugely the appearances of the outline of the external and internal canals (*cf.* Figs. 226, 227). The accompanying figures (Figs. 228-231) of Case XVIII, for example, are an illuminating commentary on Fig. 89, which was

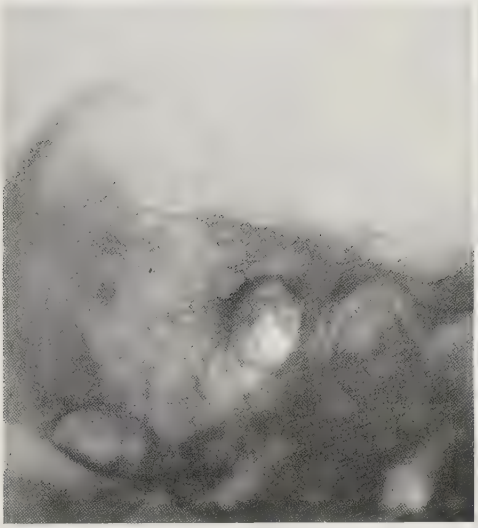

Fig. 230

Fig. 231

FIGS. 230, 231.—Same as in Figs. 228 and 229. Plates interpreted by stereoscopy, showing normal internal canals.

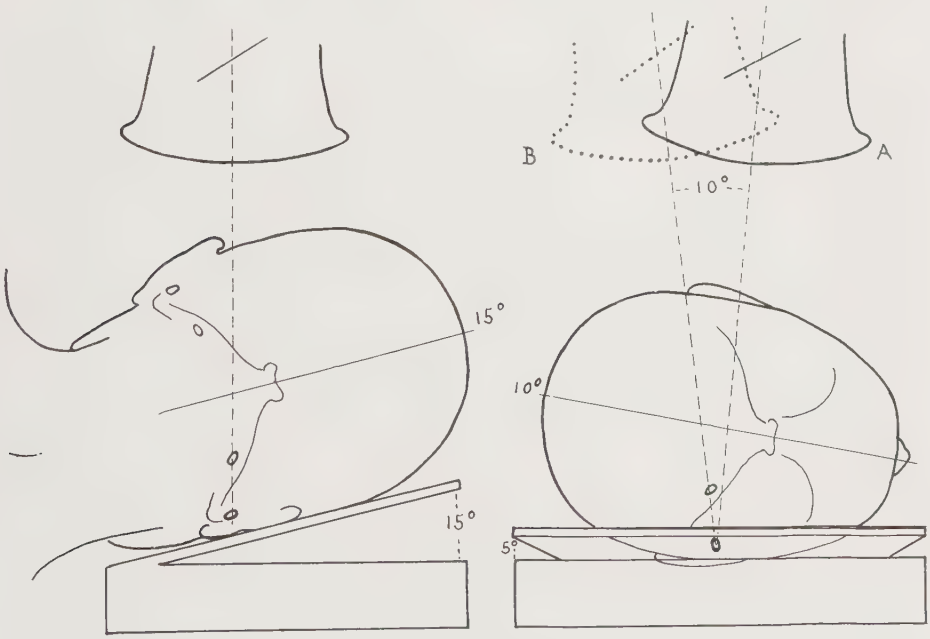


FIG. 232.—Diagram to show position of head for stereo-exposures of the right porus internus. Note position *A* and *B* of tube.

interpreted as showing an absorption of the left porus internus. In these figures the direct superimposition of the internal on the external canal of the right side could have been entirely misleading without stereoscopic confirmation. Similarly in Cases XXVIII and XXIX a series of careful post-opera-

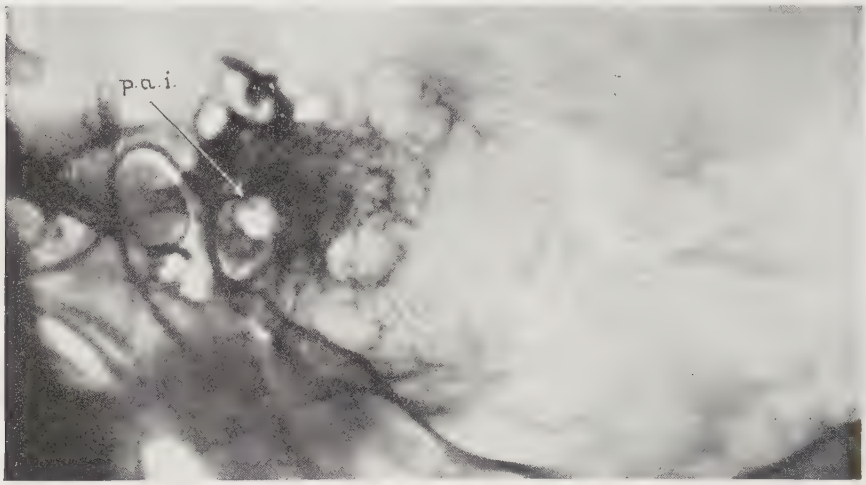


Fig. 233

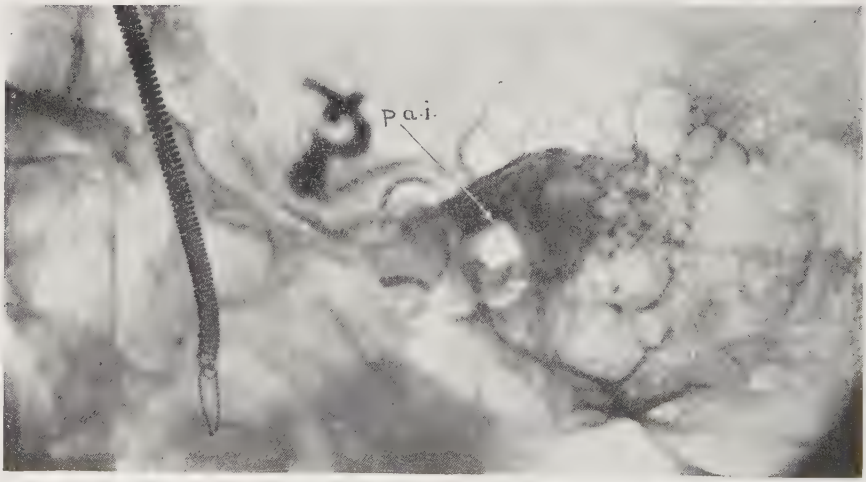


Fig. 234

FIGS. 233, 234.—Stereo-exposures of left mastoid, showing external and internal (*p.a.i.*) pori. Upper figure in position *A*: lower in position *B* (*cf.* Fig. 232).

tive stereo-exposures were made and they failed to confirm the original interpretation, based on single plates, that the canal was dilated.

In making stereo-exposures we have had the greatest success with the head about in the position shown in Fig. 232, and with the two exposures taken in the planes indicated. The angle from slightly in front is apt to superimpose

the two openings, but it is necessary to have the less exact superimposition of the other plate in order to get a perfect stereoscopic effect. Examples are shown in Figs. 233 and 234, the outlines of the two canals of a normal dried preparation. It is probable that by the use of clear stereo-Röntgenograms one may detect, in comparison with the normal side, slight evidences of pressure absorption around the affected meatus, even though the inner part of the internal canal is sufficiently intact to give the impression on a single plate of an opening of normal size. Doubtless much further study will be necessary in this direction. It would seem that if such a small tumor (a hazelnut size) as that described by Alexander is capable of dilating the meatus we should in time be able to demonstrate the condition with the X-ray, and if Henschen's

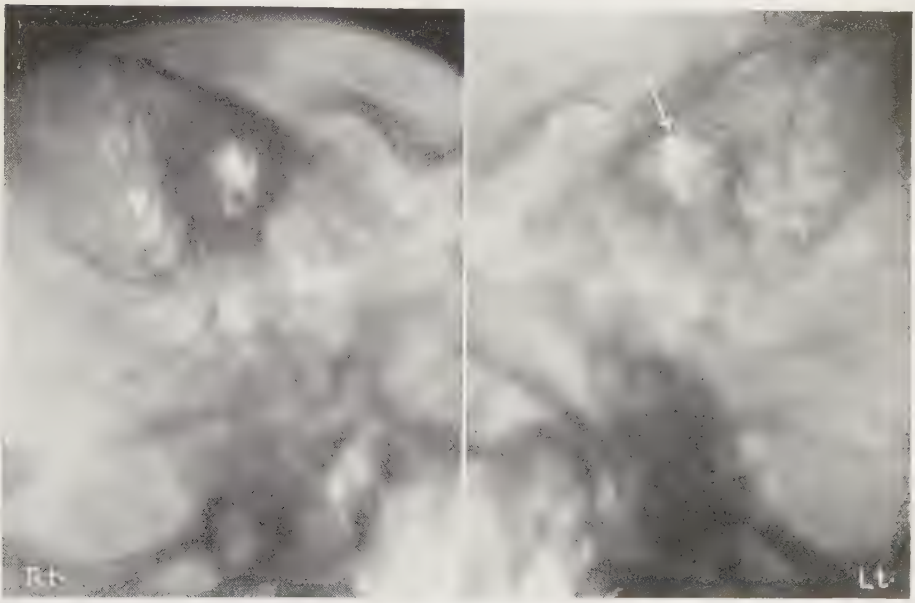


Fig. 235 Fig. 236

FIGS. 235, 236.—Prints of what were regarded as plates showing unquestioned pressure absorption of the left porus internus (arrow). A left acoustic tumor with normal porus internus was found.

contention, based largely on the fact that the five or six early tumors which have been chance postmortem findings have all originated in the porus, is correct it may become possible with perfected radioscopic technique, to make more precocious diagnoses. At the present time, unfortunately, our chief danger lies in misinterpretations of our Röntgenograms (Figs. 235, 236).

**The Bárány reactions.**[17] Like many other studies of prime physiological interest and significance, the more elaborate Bárány tests for labyrinthine function have not as yet served to give for the clinician, particularly in the case of acoustic tumors, much more than confirmatory evidence to what may be determined without them. They stand in much the same relation to disorders of the cerebellolabyrinthine path that the detailed studies of cerebellar function by Luciani, Horsley and Clark and others stand in relation to

our clinical diagnosis of cerebellar disease in general. However, they have aroused renewed interest in the subject of labyrinthine function and have given us new and more exact methods of investigating it and should be carried out in all patients suspected of having some impairment of its paths.

The main thing which one wishes to determine in the case of an acoustic tumor is whether the vestibular as well as the cochlear branch of the nerve is only partly or is completely thrown out of function. As Kümmel[104] emphasized in 1909, it is difficult enough to establish with certainty the existence of actual unilateral deafness in contradistinction to apparent deafness. Hearing may be much diminished and yet tones in the greater, or more commonly in the shorter, octaves be heard (Bezold), or the period of perception may merely be shortened. The difficulty is the elimination of tone perception referred to the sound ear, which mere closure by a finger does not accomplish. Bárány attempted at first to make the sound ear artificially deaf by a sound apparatus, but irrigation is much more simple, for if the affected ear is completely deaf, as Grey has pointed out, there will be no sound perception whatsoever during the irrigation of the other.

As regards the vestibular function, Bárány's caloric tests give the most accurate information through their liberation of vertigo and nystagmus. The cold and warm tests are complementary to one another, and the cold water test, for general purposes, is the most reliable and if the vestibular branch is destroyed, no change occurs in nystagmus, there is no dizziness or alteration of the pointing reactions. Dr. Grey, who has devoted himself for the past few years to the routine of these detailed tests in all the cerebellar or suspected cerebellar cases in this clinic, has been good enough to briefly summarize his views on the subject as follows:

"The caloric test of Bárány not only affords a means of gauging the functional activity of the vestibular division of the acoustic nerve, but it furnishes important corroborative data regarding the condition of the cochlear branch. In estimating the significance of any such findings, however, it is essential to correlate them with the condition of the external and middle ears, and with the results of the general neurological examination.

"The nature of the reaction is obviously dependent upon the location of the tumor. Since the integrity of certain fibre tracts running between the internal ear, the cerebrum, the cerebellum and the muscular system is necessary for the development of the reaction movements, the nystagmus and the falling phenomena, it is clear that the results from patients with acoustic neuromas will differ in certain respects from those with new growths springing from other structures in the cerebellopontile recess.

"Discomfort from the test in the way of dizziness and nausea or vomiting is experienced very rarely by patients with tumors lying below the tentorium. By way of explanation of this fact it has been pointed out that continued increased pressure in the posterior cerebral fossa rapidly exhausts the mechanism responsible for the development of vertigo and nausea.

"The response to the caloric test in the case of a true tumor of the VIII$^{th}$ nerve is usually very characteristic. Irrigation of the ear on the affected side leads to very little if any spontaneous nystagmus, to very slight or no reaction movements (and then only in the arm homolateral to the side of irrigation), to no vertigo or nausea, and to no alteration in the falling reaction. Hearing remains as it was found previous to the test. Irrigation of the opposite meatus results in a definite fine or coarse nystagmus, in well-defined reaction movements (usually of both arms), and in very slight or no dizziness. There is very often a distinct modification of the spontaneous falling reaction. On testing hearing, the patient as a rule is found to be deaf, demonstrat-

ing complete functional if not anatomical interruption of the cochlear division on the side homolateral to the disease.

"Where the new growth arises from some other structure in the cerebellopontile angle, on the other hand, the difference in the types of reaction between the two sides may not be so striking: usually there is more response from stimulation of the labyrinth on the affected side than is obtained in the case of a true acoustic nerve tumor: i. e., some nystagmus may appear, there may be fairly marked reaction movements, and, more rarely, the falling reaction may be modified. While the reactions, then, in patients with recess tumors other than those of the acusticus, are not so significant for diagnostic purposes, they are nevertheless much more constant and reliable than those obtained from subjects with intracerebellar growths.

"The nystagmus elicited by the caloric tests is always equally marked in the two eyes. The absence of conjugate movements noted in some patients with lesions in the neighborhood of the III[rd] nerves is, in my experience, never observed with tumors in the cerebellopontile angles. When the acoustic nerve is primarily the seat of the new growth it not infrequently happens that irrigation of the homolateral ear results in slight reaction movements, whereas there may be no discernible effect on the eyeballs; and tests for hearing may demonstrate a complete interruption of the cochlear paths. This has been not infrequently observed and indicates that some of the fibres of the vestibular division have escaped destruction by the tumor. Complete loss of vestibular reactions with some retention of hearing may also be seen, but it is less common.

"Besides furnishing information regarding the functional state of the labyrinthine fibres of the acoustic nerve, as well as the condition of the fibre tracts leading from Deiter's nuclei to the higher and lower centers, the caloric test affords a convenient means of estimating the conductivity of the cochlear branch. When one meatus is properly irrigated, practically all air conduction is abolished on that side. Loud voice sounds, even shouting, are not perceived except through the opposite ear. A patient, then, whose right or left auditory nerve is destroyed by an acoustic tumor becomes deaf when the meatus contralateral to the lesion is syringed.

"In judging what importance may be attached to the data secured from the use of this test, it is necessary to keep in mind that the reactions may vary to a certain extent from one examination to another, just as the clinical picture as a whole may show exacerbations and remissions. The exact location and the size of the lesion, of course, are responsible to some degree for these results. Undoubtedly one of the principal factors, however, is the degree of intracranial pressure, in which there are fluctuations from time to time. Tests conducted both before and after decompressive operations frequently show some restoration of reactions previously abolished and due either to a lowering of the intracranial tension in general or to a local release of tension with return of function in fibres previously blocked."

## Summary

Though in the acoustic tumors, as we have seen, there is usually a definite chronology with characteristic advance of symptoms, nevertheless other lesions in the angle, or even distant lesions, may produce symptoms which at times are difficult to distinguish from them. However, in the absence of a clinical history of primary involvement of the acusticus but with definite cerebellopontile-angle symptoms, the diagnosis of an acoustic tumor is probable if characteristic labyrinthine responses to caloric tests are abolished, if deafness is complete when the contralateral ear is irrigated, and if the porus shows a radioscopic enlargement. Moreover, recess tumors which originate from another source than the acusticus are apt to show some individual symptom which from the standpoint of the typical acoustic tumor syndrome is bizarre.

## CHAPTER X

# SURGICAL TREATMENT

It is my purpose in this closing chapter to give in some detail the technical steps of the type of suboccipital exploration for tumors of the posterior fossa which is favored in this clinic. The operation was first described[43] twelve years ago as a bilateral cerebellar exposure through a "cross-bow incision," and though it has admitted defects the procedure has become so far perfected that it is possible today to speak with a little more confidence as to its advantages.

The operation is advocated for all subtentorial growths whether or not they occupy the cerebellopontile angle, and its employment has made it possible to greatly reduce the mortality of these cerebellar operations, which in the past, particularly in the case of cerebellopontile lesions, has been so high as to be almost prohibitive. It may not be amiss to briefly tell the story of this gloomy corner of neurological surgery.

In reviewing the history of these acoustic tumors we have roughly traced the slow advance in our diagnostic ability, first to distinguish tumors of the posterior fossa in general, then the tumors of the lateral recess from those elsewhere below the tentorium, and finally the acoustic tumors from others in the cerebellopontile angle. All of this has taken place practically within the last twenty-five years. Consequently in the early operative attempts to remove what appear to have been acoustic neuromas, the tumors must have been stumbled upon, though the fact of their being occasionally found shows that a subtentorial lesion somewhere was anticipated.

As may be recalled, von Monakow,[129] in describing in 1900 what was regarded as one of the first of these tumors to have been correctly diagnosed during life, suggested that the acoustic neuromas might be favorable for operative removal. Impressions gained from the autopsy table are not always good surgical leads, and in this instance, owing to entanglement of the growth in lateral branches from the basilar artery, though it may appear to be merely waiting to be shelled out of its pocket, it is in reality almost impossible to enucleate without the production of embarrassing hemorrhage which can only be stilled by pressure, in the course of which pons and medulla may suffer greatly. The cerebellopontile angle, like the fence corner of the Gettysburg battlefield, might well be called the "bloody angle."

Thus one of the most difficult to enucleate of all brain tumors was regarded as surgically favorable, whereas, according to Starr's estimate in 1893,[171] on the basis of postmortem studies, only seven per cent of all intracranial tumors were considered operable—a percentage, it may be observed, scarcely larger than the actual percentage of the acoustic tumors taken by themselves.

A number of extirpations of cerebellopontile tumors, however, had been

attempted before 1900, unquestionably on the basis of more or less haphazard localizations. It has been stated that a case was operated upon by von Bergmann in Oppenheim's clinic in 1890, but the tumor was not found until after the patient's death, which quickly ensued. McBurney[121] likewise explored the posterior fossa unsuccessfully in 1891 on a case for Allan Starr in New York. In the following year Ballance[16] operated for Beevor in London with a successful result, though it is my impression from the records that the tumor, "a fibrosarcoma of the right cerebellar fossa" may have been a meningeal endothelioma (*cf.* Case XXXIV) rather than an acoustic tumor.* In 1893 Guldenarm (according to Winkler and Rotgans,[201] Obs. 13) operated for Winkler in Amsterdam on a case with early fatality.

In 1895 Annandale in Edinburgh had a brilliant surgical result, the first recorded, on a case of G. A. Gibson's[68]: the clinical diagnosis, according to Stewart's report,[176] had been a tumor of the right lobe of the cerebellum, but the clinical history and the operative note leave little doubt but that the described lesion must have been an acoustic tumor. In 1896 Gerster operated unsuccessfully for Stieglitz[178] in New York, and in the following year Bendani had a successful case for Murri[131] of Bologna. In 1899 v. Ziegenweidt[213] of Rotterdam, owing to pronounced contralateral cerebral nerve symptoms, explored the wrong side and his patient succumbed after a few days.

With the possible exception of Ballance's case, all of these seem to have been examples of undoubted acoustic tumors, though called fibrosarcoma or gliosarcoma. There must have been a great number of unrecorded failures during the last years of the century, but the story of such of these pioneer operations as were reported, with the attendant uncertainties of diagnosis, makes most interesting and instructive reading. Agusto Murri's clinical report[131] in particular is a most noteworthy one for the time.

The articles by Sternberg and v. Monakow in 1900 unquestionably served to focus attention on the subject of these angle tumors and in the early years of the century serious efforts were made to find some available approach to the recess, but unfortunately without adapting to the problem of intracranial surgery other than the rough methods of handling tissues then in general use.

## Methods of Access to the Tumor

That any of these early operations were rewarded by success is remarkable in view of the small cranial openings which were made and the fact that these openings must necessarily have become occluded by a cortical herniation the moment the dura was opened, for it was long before the importance of a large cranial opening was appreciated, and the cerebrospinal fluid element in the production of tension has only recently come to be moderately understood.

Guldenarm's early operations seem to have been made with a double flap above and below the lateral sinus. Gerster[178] in 1896 attempted to approach a tumor of the angle through an opening in the tentorium after elevation of

* It is stated that the growth was a solid tumor attached to the dura over the inner part of the posterior surface of the petrous. Ballance's diagram is necessarily somewhat imaginary, and as the growth was hooked out with the fingers the resulting paralysis of the V$^{th}$ and VII$^{th}$ might have occurred whether it was an acoustic neuroma or an endothelioma. There is no note of auditory symptoms and the patient was living twenty years later.

the occipital lobe, and a somewhat similar procedure seems to have been contemplated in the same year by Chipault under Raymond's[146] direction, with an exposure both above and below the lateral sinus. It is not impossible that these methods might be successfully developed and a recess tumor exposed in this way provided the lateral ventricle is punctured and tension thus relieved.

Though Sir Victor Horsley never described the procedure which he employed nor fully reported the results of his many operations for tumor, it is probable that his experience in the early years of the century was far greater than that of any other surgeon, for in 1903 he operated upon six patients for what appear to have been acoustic tumors, with at least one excellent recovery, according to Stewart and Holmes's report[177] (*cf.* Case 19). It is quite probable that he used, as was his favored custom, a two-stage operation, but whether bilateral or unilateral cannot be told from his scant operative reports. It is probable, however, that almost all of these earlier operations were conducted through an enlarged trephine opening exposing a single hemisphere.

**The unilateral operation.**—Early in 1903 Woolsey[210] described the method of approach which had doubtless been used by the majority of his predecessors—namely, a unilateral suboccipital craniectomy in one stage, and an operation was attempted on a case of Fraenkel and Hunt's[60] in which a tumor was removed piecemeal by the finger, with prompt fatality. It was in this same year that Krause described[101] a unilateral osteoplastic operation in two stages, devised primarily for the purpose of exposing and dividing the auditory nerve for persistent tinnitus. As a matter of fact, if a one-sided exposure is to be preferred, the Wagner osteoplastic resection to expose the cerebellum, as first employed by Guldenarm (1890), v. Eiselsberg (1894), Picqué and Mauclaire (1898) and Remy and Jaune (1898), is far less desirable than the simple, wide one-stage craniectomy described by Woolsey, but nevertheless, no matter how modified, all posterior unilateral measures have since come to be attached to Krause's name, with some justification in view of his careful description of the method[101] and his successful case operated upon in 1905 and reported by Ziehen,[214] and in the following year by Krause himself.[102]

This unilateral manner of approach, modified in one way or another, has from the outset been advocated by most surgeons. The variations proposed have been many,—by Elsberg,[55] Bergmann, Narath,[15] Ballance,[16] Baisch,[15] Frazier,[62] Chipault, Schede,[156] Garré,[66] Kocher, Picqué and Mauclaire[138] and others. The operation has been conducted either in one or, much more often, in two sessions, with or without an osteoplastic resection, with a transcerebellar or extracerebellar exposure of the lesion, or even with deliberate removal of a portion of the hemisphere (Frazier[62] and Borchardt[28]), and with various methods of dealing with the growth if successfully exposed.

All told, the first decade of this century was a bad period for cerebral surgery, largely due, I think, to the emphasis which was laid both by neurologists and surgeons on "celerity of execution," and I doubt not that with the expenditure of more time, greater precautions against loss of blood and traumatism, and a coincident lowering of tension by a ventricular puncture, there are possibilities for a unilateral one-stage operation. As heretofore conducted, the procedure has been accompanied by a shocking mortality. Thus Bor-

chardt[28] in 1906 assembled from the literature 18 verified cases with 13 fatalities (72.2 per cent): v. Eiselsberg[54] at the XVII$^{th}$ International Congress in 1913 reported 16 personal cases with 12 immediate fatalities (75 per cent) from operative shock, and at the same meeting Krause[103] admitted that in 31 cases operated upon for tumors of the cerebellopontile angle he had had 26 fatalities (83.8 per cent).

**The translabyrinthine operation.**—The fact that these recess tumors invariably affect the sense of hearing has led otologists from the outset to take an active interest in them and to suggest operative measures by a route with which they were more or less familiar through operations upon the labyrinth. There is considerable justification in the otologist's claim that careful studies of these cases from the standpoint of the skilled examiner who is familiar with the Bárány tests are often neglected and that if they were more commonly employed fewer diagnostic mistakes would be made.

In view of the serious nature of the so-called Krause method and its attendant high mortality, Panse in 1904 suggested an operation with an approach directly through the pyramidal bone (*cf.* Fig. 237), but he admits that the operation not only destroys the middle ear, which is of no great significance as its function has already been permanently impaired, but that it also inevitably leads to a homolateral facial paralysis. Obvious drawbacks to the procedure lie in the depth of the wound and the narrow field of action, circumscribed as it is externally by such important vascular structures as the sigmoid and superior petrosal sinuses, and deeper in by the carotid artery. Only in the case of a very small tumor largely confined to the canal and producing auditory and vestibular symptoms alone could a tumor be removed by such an operation, and patients with tumors of such small size would hardly be induced to court an operation of this magnitude with a certainty of a facial paralysis, even if the presence of the lesion could be certified beyond peradventure.

There are other and very serious disadvantages of the translabyrinthine operation. One lies in the fact that it does not serve as a palliative measure in case of the almost inevitable incomplete removal of the lesion. The suboccipital procedures, on the other hand, even though they may have afforded a less direct access to the lesion, nevertheless serve this important purpose as an immediate as well as future safeguard whether or not the growth be successfully removed. Another serious objection to the method, furthermore, is the resultant cerebrospinal-fluid leak through the wound or ear, which in the larger number of cases would almost certainly lead to a meningitis.

So far as can be found, very few cases have been operated upon by this method, though it was again warmly advocated in 1908 by Bárány and in 1909 by Kümmel of Heidelberg. Two years later it was undertaken by Kümmel in a single case with recovery and temporary improvement (*cf.* Marx[119]).

In 1911 Quix,[141] in Utrecht, excised a small tumor the size of a pea, and yet in six months' time intracranial symptoms appeared and the patient soon died,[145] an autopsy showing an acoustic tumor the size of a hen's egg, which makes it probable that only the fragment of the tumor projecting within the porus was originally seen and removed. Zange[212] has recently reported another case with the partial removal of a tumor diagnosed as a neuroblastoma of the acusticus, and Schmiegelow[158] (1915) has recorded two additional ex-

periences with the fragmentary intradural extirpation of tissue which proved in each instance to be glioma.

Schmiegelow, however, presents as arguments in favor of this procedure the shorter approach, the extradural situation of the larger part of the opera-

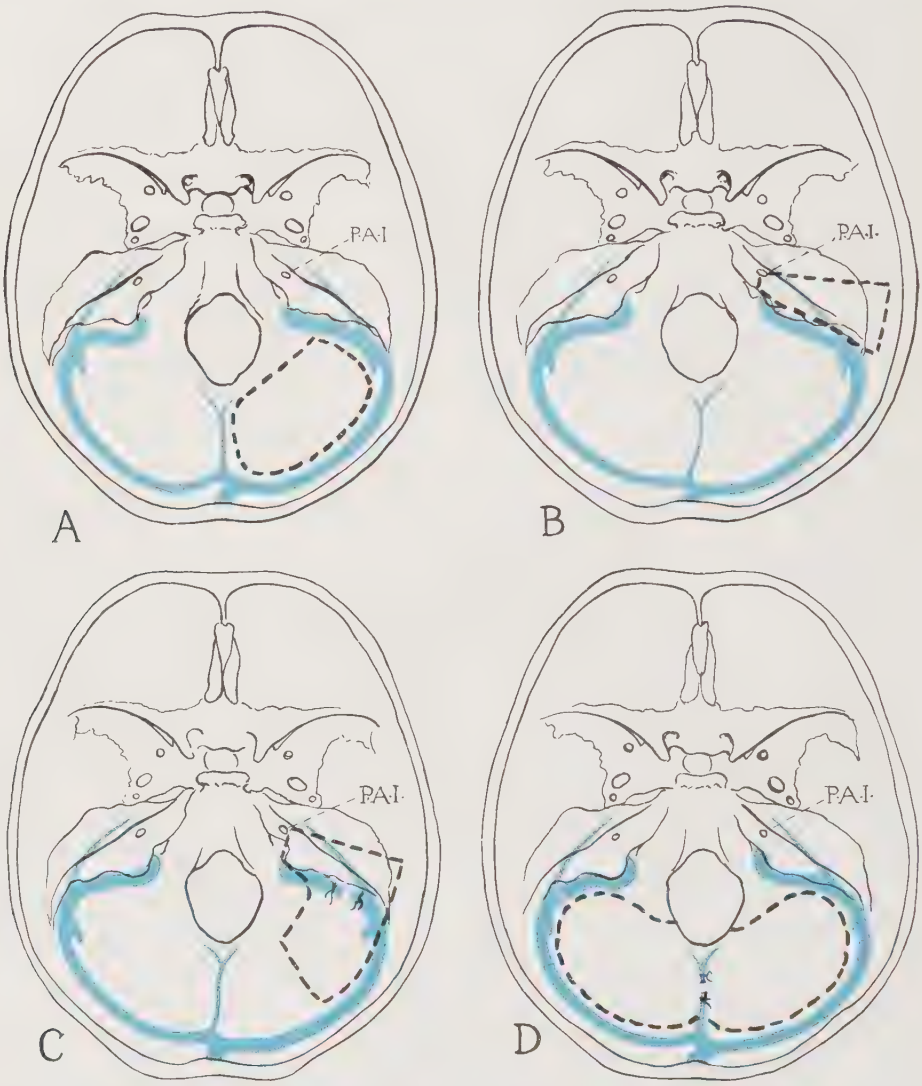


Fig. 237.—Showing in heavy dotted lines the situation, in relation to the sinuses, of the bony opening in (A) the unilateral, (B) the translabyrinthine, (C) the combined, and (D) the bilateral methods of approach. P.A.I.: porus acusticus internus.

tion, and the comparatively slight risk of hemorrhage. Hemorrhage, however, must be much more serious than in a carefully conducted suboccipital procedure; the technical difficulties must be overwhelming; the exposure is

insufficient; and, above all, the operation, as already emphasized, is incapable of affording a coincidental decompression.

It is, however, within the realm of possibility that in the case of a very early and minute tumor largely limited to the internal canal the translabyrinthine operation may in time become the operation of choice, but this will necessitate far more precocious and more exact diagnoses than we as yet are capable of. In view of his experience, however, Quix[145] recommends a combined procedure similar to that to be described.

**The combined suboccipital and petrosal approach.**—In 1904[55] Elsberg proposed and undertook in a single case to carry out a two-stage procedure in which a primary unilateral bone defect was made far enough to the side to include the mastoid process. The patient did not survive for the second stage. In the following year Borchardt[27] independently carried this proposal still further with partial removal of the pyramidal bone as far as the internal meatus. There was so much hemorrhage that three stages were employed, the tumor being removed at the third session with early fatality. Leischner[109] reports a case operated upon by v. Eiselsberg in 1907 by a modification of the same procedure said to have been devised by Tandler, in which preparation was made for a subsequent spinofacial anastomosis. After an excision of the mastoid and pyramidal bone, the cerebellar hemisphere was exposed by an osteoplastic flap: the sinus transversus was then divided between ligatures and the dura incised: a tumor was exposed and partially removed, with fatality in 48 hours.

Though the advantage of a more direct access to the lesion is claimed for this elaborate operation, it is obviously a procedure of magnitude and hazard and has little advantage over the Panse method except for the possibility of cerebellar decompression which is afforded. So far as I am aware there have been no recoveries, and Marx[119] could find record of only five operations of this type, one of them being his own case (the patient previously operated on by Kümmel in the translabyrinthine method) with apparently complete extirpation of the growth, but the wound was tamponed with iodoform gauze, leading to a cerebrospinal fistula and fatality after eight days. Borchardt[29] himself subsequently abandoned the method in favor of the Krause procedure, by which he and Oppenheim in 1907[134] reported two recoveries, one of them a particularly satisfactory result.

Only under the so-called Krause method, therefore, had a few notably successful cases been reported—namely, those of Annandale for Gibson in 1895, Bendani for Murri in 1897, Horsley for Jackson in 1903, Krause for Ziehen in 1905, Borchardt for Oppenheim in 1907, v. Eiselsberg for Marburg in 1909, and in 1910 Clairmount for Schlesinger (*cf.* Leischner's Case 8).

In the description of the methods employed in all of the foregoing procedures it is my feeling that too great stress has been laid upon direct access to the tumor by the shortest route and too little stress upon what may happen to cerebellum and brain stem as the result of manipulations of the tumor in a restricted field.

**The bilateral operation.**—This method, first described in 1905[43] as "a bilateral exposure of the cerebellar hemispheres through a cross-bow incision," was originally advocated largely for the purpose of exploration and decompression for obvious subtentorial lesions not definitely localized on one side

or the other, but as the procedure has become perfected it has been used as the preferential method of exposure for all cerebellar tumors.*

It is admittedly an operation of magnitude and requires not only a special table but unusual training, not only on the part of the surgeon but of his assistants if, as is possible and eminently desirable for all concerned, it is to be carried through in one session. Its advantages, however, are many and some of them may be enumerated. Both hemispheres are exposed and, as we have seen in Case XXX, and as the experiences of Ziegenweidt and of Korteweg and Winkler[99] show, it is not always possible to determine from

Fig. 238.—Showing (after Leischner[111]) the square-flap procedure for a bilateral approach which ineffectually exposes the foramen.

clinical symptoms the side occupied by the lesion. It allows of dislocation outward of the unaffected hemisphere during the extracerebellar exploration on the opposite side. It moreover makes it possible to diminish tension early in the course of the operation by the securing of cerebrospinal fluid owing to the removal of the posterior margin of the foramen magnum; for the low median incision permits of early entry into the posterior cistern, and in case there is a far advanced pressure cone the dural incision may be carried to the atlas (*cf.* Case IV) or the posterior arch of the atlas may even be removed

* A bilateral one-stage method, accompanied by ligation of both lateral sinuses, was employed by Willy Meyer[123] in 1908 in a successful operation for an acoustic tumor. It was also successfully employed by Poppert[140] in 1907, though with an osteoplastic resection, and was advocated by Lecène[108] in 1909.

(*cf.* Case VIII). It is thus possible, even in far advanced cases, to avoid serious medullary compression during the course of the operation, and this is almost unavoidable in the unilateral method of exposure, especially with an osteoplastic resection, as originally advocated. Though Krause[101] and Borchardt[29] have both described a bilateral method of cerebellar exposure with an osteoplastic resection in two sessions, I am unaware that the method has been put in practice for an acoustic tumor, nor can I imagine its being other than a desperate and bloody manner of approach.

Another bilateral procedure with removal of bone, which differs from that herein described only in the fact that a square rather than a parted flap of the overlying tissue is advocated, was also described by Frazier[62] in 1905 as the result of studies on the cadaver. He suggested that it might be useful for median tumors, but regarded it as an operation of too great magnitude for a routine procedure. So far as I know, it was first employed in 1910 on two cases by Leischner and v. Eiselsberg. Both operations were performed in two sessions and were attended by troublesome hemorrhage: both patients succumbed. There is no reason, however, with painstaking hæmostasis and a one-stage operation, why a satisfactory exposure should not be made through this square-flap procedure (Fig. 238), though for the reasons which have been given I prefer to have better access to the region of the foramen magnum.

The literature is filled with the accounts of fatalities following a first-stage operation for a cerebellar tumor, which has stopped short of opening the dura. One reason for this is the lack of immediate relief from the pre-existing tension, which is in all likelihood increased by the anæsthetization and the operative manipulations, whereas the patient's ability to withstand any additional pressure is greatly lessened by the great loss of blood, inevitable with the methods usually employed.

## Steps of the Preferential Procedure

I. *Preparation of the patient.* This consists in the mere omission of breakfast, the giving of an enema if necessary, and the shaving of the back of the patient's head the morning of the operation, over an area shown in the post-operative photographs accompanying the case reports. Proper shaving of the scalp is an art. In the case of women the hair should be parted in a curved line running from pinna to pinna and about 4 or 5 cm. above the line of the proposed incision. The hair above the line should be drawn up and gathered in a tight braid which centers at the vertex, and the shaving should run downward from the exact line of the part.

Elaborate preparations for operation often defeat their own aims, in giving patients an uncomfortable night, in sending them to the operating room with their courage at a low ebb from intestinal cramps due to the unnecessary administration of a laxative and with the scalp sore from soap poultices or antiseptic applications. Some neurological surgeons have even advised a preliminary skin treatment lasting over a period of two days.

There are certain risks in a small area of shaving, but these are overcome by pinning the sheets securely into the scalp so that they remain immobile even through a long preparation. A little skill in the arrangement of their hair makes women presentable even after the shaving of the suboccipital area (*cf.* Figs. 261, 262) and the advantages of this are not to be lost sight of.

II. *Position on the table.* The operation being a symmetrical one, a face-down position is essential, and to make this position tolerable and permit of unimpeded free thoracic respiration, shoulder supports are necessary and the patient's face must rest in an outrigger

beyond the table in such a way as to be accessible to the anæsthetist (Fig. 239). Some useful modifications in the crutch for the head have been devised by Dr. Grey, but to all intents and purposes it is much the same in principle as was originally described. The face rests in a well-padded horseshoe-shaped support which can be tilted or raised or moved in or out as necessary (Figs. 240 and 241). It is essential that the patients be comfortable and in such a position as to breathe freely, and this is one reason why they should always be put upon the table in the desired position before the anæsthetic is started, for they may have to remain unmoved for several hours. The patient, moreover, should lie upon a thick mattress and not on a hard surface, and from personal tests it can be certified that the position is comfortable enough to favor sleep.



Fig. 239.—Showing outrigger for head and adjustable shoulder supports: before padding: also hoop to support sheets.

III. *The anæsthetic.* The most important factor is the anæsthetist. No patient should be given inhalation narcosis by unskilled hands, but in these operations in particular, carried out on patients who have some deglutitory difficulty and whose respiratory center may readily become embarrassed, something more than the customary familiarity with giving an anæsthetic is necessary.

Though de Martel advocates local anæsthesia for cerebellar operations and others have employed various anæsthetics or combinations of inhalation drugs, ether remains unquestionably the safest, though it admittedly is the most difficult to administer and it possesses the disadvantage of increasing the secretion of the cerebrospinal fluid and thus accentuating tension.

With the face-down position some method of giving ether vapor is necessary and we have come to rely on the Connell apparatus (Anæsthetometer), by which warmed ether vapor is administered and the tension of the vapor is accurately recorded. Dr. Boothby

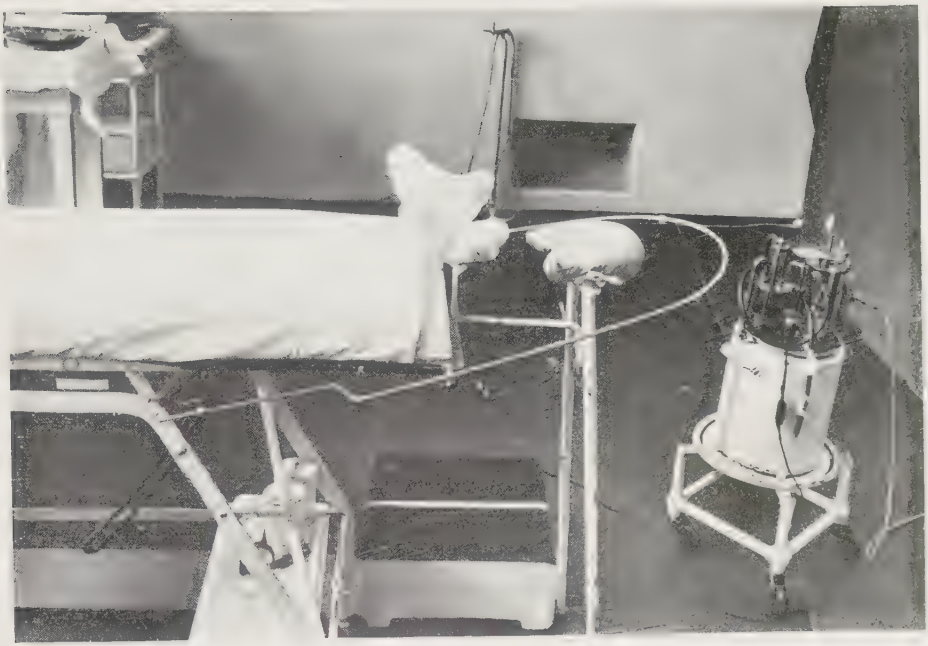

Fig. 240.—Table supports padded to fit patient. Connell apparatus to right.

Fig. 241.—Patient in position before anæsthetization.

has found that the same tension of the vapor appears to be required for the anæsthetization of all vertebrates, large or small, and when one has learned to use the Connell machine, complicated as it appears, the giving of ether is not only greatly simplified but made a much

CHART 3

PETER BENT BRIGHAM HOSPITAL
SURGICAL SERVICE

WARD A..... ANAESTHESIA CHART

Name Mrs·M·L·D·..... Age 41..... Date of Operation April 20, 1916

Lungs Negative..... Heart Negative

Urine Normal..... Arteriosclerosis None

Operator H·C·..... 1st Assistant G·H·..... Anaesthetic Ether [Connell]

Operation Suboccipital for Acoustic Tumor Prelim. Drugs None

Blood Pressure { Start / End: Systolic 120 / 120; Diastolic 95 / 90; Pulse Press. 25 / 30 } April 20, 1916 (Date and Time) ..... Rectal Temp.

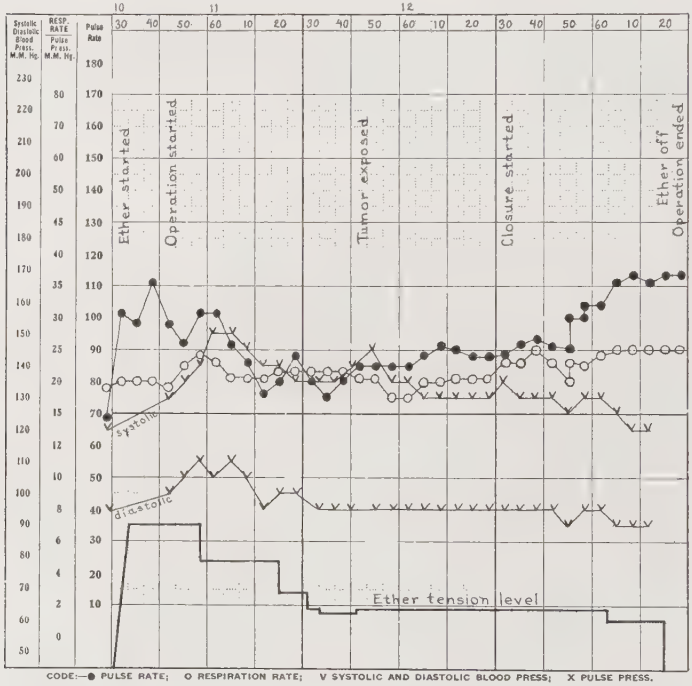


Stimulants None

Remarks ...Anaesthetic well and evenly taken

Acoustic Tumor ... Case no·XXIII

Drains. None

Closure Complete ..... Anaesthetist. W·B·.....

2m-3 16 Form 13.

Example (Case XXIII) of an ether chart (reduced).

more exact and even procedure. The face-down position, it may be added, is ideal for the effectual drainage of saliva and mucus.

There are certain advantages in Meltzer's intratracheal anæsthesia which are offset by the frequent difficulty of introducing the tube into the trachea and the fact that the complete relaxation of profound anæsthesia is essential to the act. Were this introduction easier to accomplish and could the tube be accurately passed with the patient on his face, the method would be favored in all cerebellar operations in view of the possible need of artificial respiration. The face-down position, however, is the correct position for the employment of Schaefer's method, and this has been relied upon (e. g., Case IV) in case of respiratory failure during the operation.

The anæsthetist keeps an accurate ether chart (e. g., Chart 1, p. 109, Chart 2, p. 118, and Chart 3), recording not only pulse rate, respiration, and ether tension but also by means of an auscultatory method (Tycos) the systolic and diastolic pressures. Thus the patient's condition can be determined with almost the exactness of an animal whose pulse and respiration is recorded on a drum during a laboratory experiment. The anæsthetized patient should be, and usually is, so quiet during these prolonged operations that the operator has

Fig. 242.—Final preparation. Epidermal lines of incision can be seen through gauze covering.

no distractions whatsoever on that score, and though it would possibly appear that the keeping of such a record might put too heavy a burden upon the anæsthetist, Dr. Keen has testified to the contrary in his "Ether Day Address."[94]

IV. *Preparation of the field.* The freshly shaved area of scalp (Fig. 241) over the occiput to the ears and back of the neck, is merely washed with green soap on a gauze sponge, followed by alcohol and bichloride just as the patient is reaching the second stage of ether. Personally, I abhor the use of iodine, at present so popular for a skin preparation.

A cuticular scratch barely deep enough to draw blood is then made with the edge of the knife to outline the proposed incisions. The curvilinear line thus demarcated should run from mastoid to mastoid and arches possibly 4 cm. above the occipital protuberance. If one is reasonably certain as to the side of the lesion, as when an acoustic tumor is expected, the scratch on that side may be carried somewhat farther down on that side, so that the posterior margin of the mastoid is more accessible. The demarcation for the vertical

incision should be made exactly in the midline, like the arrow in a drawn bow, and is carried downwards 9 or 10 cm. possibly to the spine of the V$^{th}$ cervical vertebra. Over the field a large layer of bichloride gauze is then thrown.

A series of sheets are then applied (Fig. 242). The first, a sheet with a hemicircular notch with tapes at the angles, is draped over the wire hoop which serves to hold it away from the field and makes a tent for the anæsthetist. The hemicircle is pinned into the scalp

Fig. 243.—Showing method of controlling hemorrhage. Incision through galea on right half of wound.

just above the scratched line of incision and the tapes are tied by the anæsthetist below the head crutch. Lateral towels are pinned to the side of the wire hoop, drawn taut and, together with the hemicircle of the first sheet, secured with a towel clip into the skin at the point of the mastoid, and where they cross are similarly secured to the skin in the midline of the lower neck. The instrument stand is moved up and over all is thrown a gray sheet which also has a hemicircle cut in its margin and which encircles the field.

Every surgeon has his personal preferences for the arrangements of his field of operation, and it may seem superfluous to go into this stage of an operation in much detail, but there must be no slipping nor changing of towels during such an operation in this circumscribed field and the incision, to be exactly in the position desired, must be marked out before the cloths are placed, else it would be necessary to leave uncovered anatomical landmarks which cannot be cleaned beyond



Fig. 244.—Showing control of incision for completion of incision.

suspicion. It is a principle, I think, which could well be introduced into surgical operations elsewhere in the body.

V. *The making of the flaps.* Every possible precaution should be taken to avoid loss of blood, and much blood can be lost from 10 or 12 inches of scalp incision, particularly when the extracranial vessels are distended, as they usually are in the presence of a brain tumor.

As described in a recent article upon the technique of a subtemporal decompression,[48] we have come of late years to depend, except when a tourniquet can be used, solely upon the pressure of the fingers (Figs. 243, 244) to control hemorrhage from scalp incisions, and with practised assistants it is possible to make these incisions down through the galea and to separate the edges in the subaponeurotic layer with practically no bleeding whatsoever. Before the pressure is released

Fig. 245.—Reflection of flap in subaponeurotic layer to just below superior curved line.

a series of pointed clamps are attached to the galea, which is folded over the incision and effectually prevents subsequent bleeding. Particular care must be taken to catch the major suboccipital arteries which lie in the substance of the occipitalis muscles. This curvilinear flap is then "scalped" back (blunt dissection will usually suffice) in the subaponeurotic layer to slightly below the occipital protuberance and the muscular attachment of the superior curved line (*cf.* Fig. 245).

The midline incision (Fig. 246) is then made with like precautions and it is essential that it be exactly in the midcervical line or otherwise there will be unnecessary bleeding. It is carried down through the intermuscular spaces to the skull and to the spines of the upper cervical vertebræ, clamps being applied symmetrically on the two sides as the wound is deepened. This midline incision, made at this time and carried to the

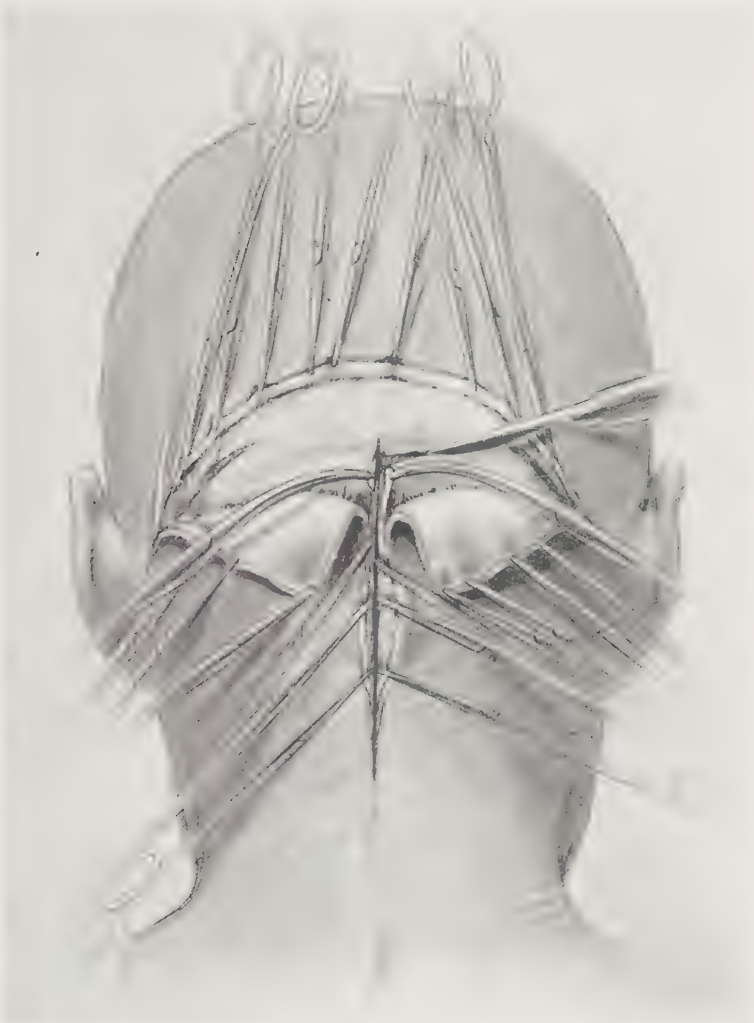

Fig. 246.—Mid-cervical incision carried to spine. Placement of identifying clamps on corners before lateral incisions are made through.

skull, serves to show the exact level at which the transverse cut should be made along the line of muscular attachment.

At this juncture a clamp of different pattern, so that later on it may be easily distinguished from the others, is attached on each side to the two upper edges of the vertical incision in the fascia (*cf.* Fig. 246) and the fascia is divided along the superior curved line and drawn down. The muscle in turn is similarly treated after two clamps have been put

at the angles, leaving just enough of a margin of fascial and muscular attachment to serve for subsequent suture. The placement of these clamps at the corners is an important step, for without these landmarks it will be found difficult to exactly reapproximate and resuture the layers at the close of the operation (*cf.* Fig. 256).

The muscle is then scraped back from the bone on each side far enough to fully expose the margin of the foramen magnum, the edge of each mastoid process and well down under

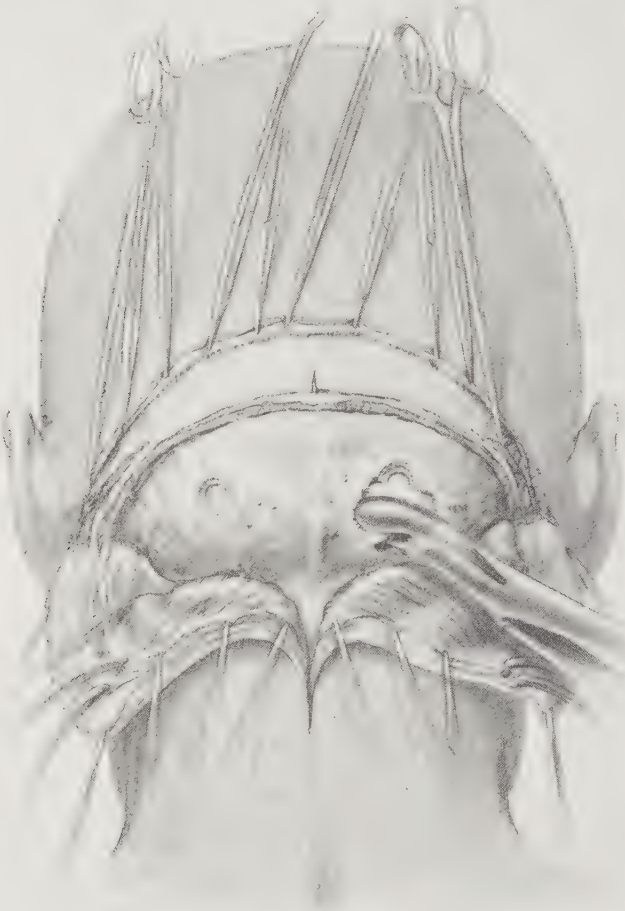

Fig. 247.—Showing denudation of suboccipital region: exposure of foraminal field by reflection of flaps: primary bone openings.

the occipital bone on either side, much farther than can be shown in the sketch (Fig. 247). During this act profuse bleeding may occur from emissary vessels, particularly in the midline and around the occipital protuberance, unless proper use is made of Horsley's bone wax, large quantities of which may sometimes be needed. Another place where embarrassing bleeding may occur is from the mastoid emissary, and here again wax is necessary or in difficult situations the placement of a fragment of muscle may be required.

VI. *The craniectomy.* With a motor-driven burr one or more primary perforations are made over each hemisphere and with rongeurs the openings are subsequently enlarged (Fig. 247) to the full extent of the denuded area of bone. The lower margin of the lateral sinus is usually exposed on each side.

Difficulty may be experienced in crossing the midline, and in the removal of this thicker area of bone the placement of wax may be necessitated after each bite of the forceps. Needless to say, care should be taken that the bone should be bitten outward so as to avoid any

Fig. 248.—Showing, near the foraminal region, the primary small opening in the dura and subsequent puncture of the lateral ventricle if failure to secure fluid and extreme tension demand.

jar of the forceps against the dura and brain. In the process of removing the posterior rim of the foramen and the bone to the side of it, emissary vessels from the sinus encircling the foramen may be encountered on each side, but they may be easily controlled.

In many cerebellar cases the bone will be found greatly thinned and is very easy to remove, and though this may be true also of recess tumors it is perhaps less common than in the case of intracerebellar growths.

VII. *The dural opening and release of tension.* The membrane will be found tense and

should an opening be made over one of the hemispheres before the tension has been lowered, the cortex will protrude and is likely to become contused before the exposure can be completed. Consequently it is desirable to secure fluid at the outset. Hence a minute primary dural opening (Fig. 248) is made low down near the foramen in order, if possible, to secure fluid from the posterior cistern. If there is a

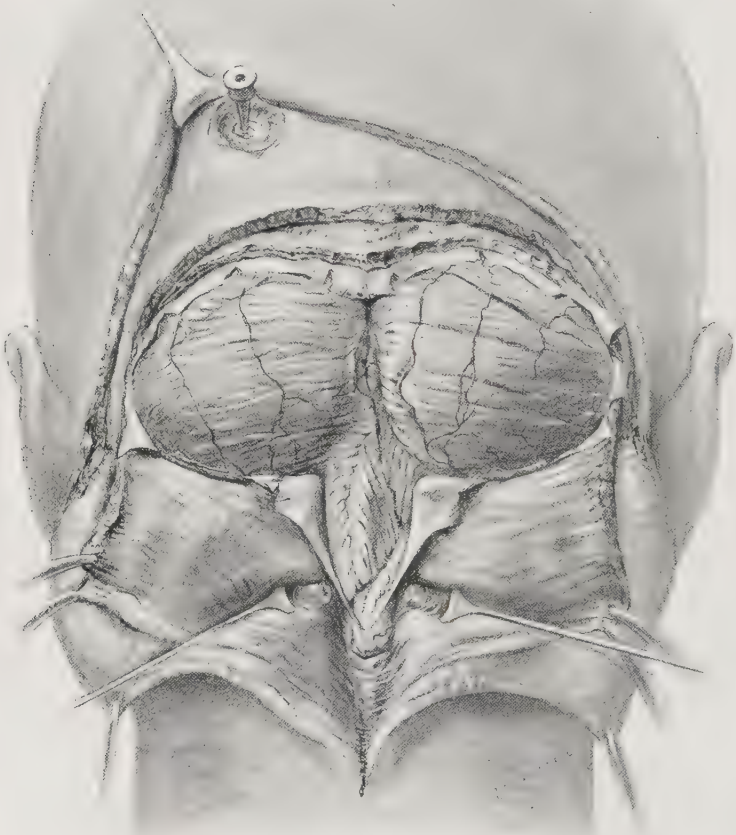

Fig. 249.—Showing extreme foraminal herniation (pressure cone) in a case in which tension was so great as to necessitate removal of the laminæ of the atlas and carrying the dural incision to the atlas before respiratory embarrassment was relieved.

marked pressure cone and the cistern empty, cortex will immediately occlude the small opening and it is far safer to immediately tap the lateral ventricle than to venture upon a further enlargement of the opening.

To tap the ventricle the scalp is drawn back in the subaponeurotic

layer as shown in Fig. 248, and with a burr a perforation is made about 3 or 4 cm. above the superior curved line and 2 cm. from the midline. Through this opening the blunt cerebral aspirating needle is introduced slightly upward and outward, and with a good visualization of the ventricle the first tap rarely fails at a depth of 4 or 5 cm. to reach fluid. The needle is left in place during the remainder of the exploration and serves as a great safeguard against medullary pressure. I have never seen any accident whatever from this procedure, which must have been carried out in over a hundred cases of cerebellar tumor.* Indeed on many occasions when hemorrhage from the extracranial tissue and the bone is particularly troublesome, the intracranial tension has been thus lowered before the completion of the bone defect with immediate marked lessening of the tendency of the tissues to bleed.

After the ventricular tapping the dura will lose its tension and can be safely opened. Care must be taken in crossing the median line, for the sagittal cerebellar sinus may be of considerable size and the cerebellar falx may penetrate in some cases for a considerable distance. As the midline is crossed the cerebellum should be held away with a spoon spatula and the sinus may be caught, before division, with silver clips. Stellate incisions of the membrane to the margins of the bone defect are then made and the hemispheres fully exposed.

At this stage of the operation if there is any doubt of the diagnosis the two hemispheres should be compared for differences of tension, of form or of vascularity. An intracerebellar cyst can usually be detected by palpation; an involvement of one hemisphere rather than the other by the displacement of the midline structures. Particular attention should be given to the conditions at the foramen, where a marked pressure cone may forbode ill.

An extensive foraminal herniation of the cerebellar tonsils (Fig. 249), however, is not so apt to accompany cerebellopontile lesions as intracerebellar tumors: indeed with some of the acoustic tumors in the series there has been but little displacement and a large posterior cistern is present. In only one of these operations for an acoustic tumor (*cf.* Case VIII) has it been necessary, in order to free the medulla, to resort to the device of removing the posterior arch of the atlas (Fig. 249) and to carry the median incision of dura to the upper edge of the axis.† This procedure may be a life-saving measure in desperate operations for cerebellar tumors which have produced a large pressure cone. It possibly would have resulted in saving Case XV on his second operation had it been carried out. Occasionally, as in Case IV, the dural incision may be carried down through the foramen to the upper margin of the atlas and suffice to free the herniation and secure spinal fluid without an actual laminectomy of the atlas.

VIII. *The exposure of the tumor.* In the case of a presumable cerebellopontile-angle lesion one turns his attention to the recess without these preliminaries, and, if the cranial defect has been made so as to include the mastoid margin, slight pressure on the cerebellar hemisphere with the spoon spatula gives access to the region. The sigmoid sinus is first brought into view and at a varying distance beyond it the arachnoid attachment or, more often still (14 of the 29 cases), an actual collection of fluid encysted within the arachnoid is encountered. On opening the cyst and carefully sponging away the fluid with flat cotton pledgets, the surface of the tumor will usually be seen. Occasionally, as shown in Fig. 250, the encysted fluid may be found low down, but more often the tumors lie higher and deeper than was the one in the case from which this sketch was made. Nevertheless the best line of approach is toward the jugular foramen rather than directly toward the porus.

As the story of the operations in this series of patients will have indicated, the exposure

---

* I confess that this does not coincide with the experience of others. Frazier[62] has stated that tapping of the ventricle is fatal in its tendencies.

† This was necessitated in an operation on one of the three patients admitted since February 1st and not included in the series. The sketch (Fig. 249) was made during the operation on this case, which was a very advanced one, and it was necessary to remove the atlas and split the dura to the axis before respiration, which up to this point had been greatly embarrassed, was fully relieved.

of the growth may not always be so easy, even when one has considerable familiarity with the region. In many of the early and some of the later cases (e. g., Case XXVIII) the search was not prolonged sufficiently far beyond the cyst and in one instance the tumor was completely overridden and, being held back together with the hemisphere by the spatula, was long overlooked. In Case XXVI no trace whatsoever of the tumor was seen until the greatly thickened nerve was disclosed entering the porus, and this was traced backward to

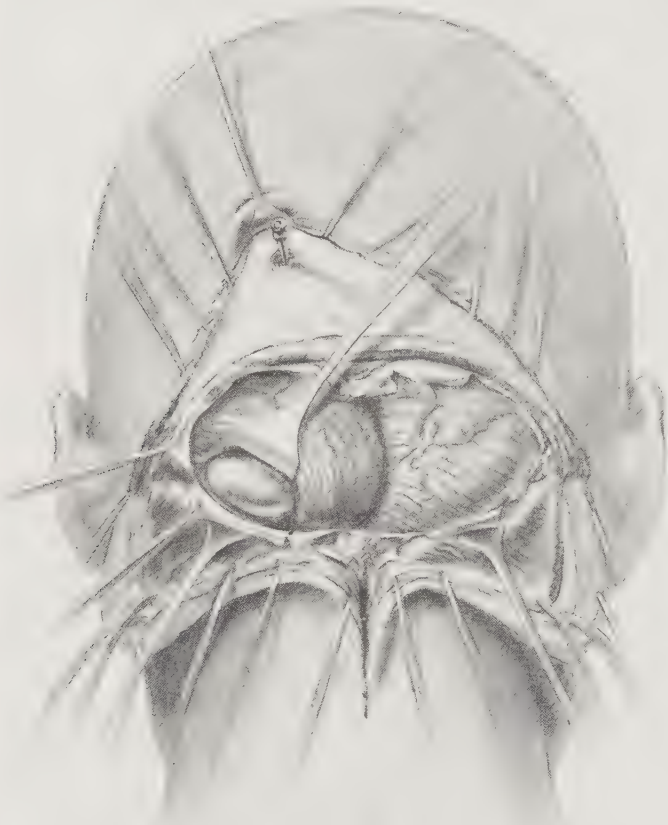

Fig. 250.—Showing exposure of encysted fluid within the arachnoid overlying a tumor, from a sketch during operation.

the encircling cuff of cerebellum before the major portion of the growth was identified and exposed.

When the growth is identified, it is possible, with wet cotton pledgets, to wipe the arachnoid, together with the crescentic margin of the cerebellum, away from the surface of the tumor and thus to expose the lesion. The cerebellum, meanwhile, if protected by a covering of wet cotton (never unprotected as shown in Fig. 250) may be held to the side by

the spoon, or (as in Fig. 250) by a delicate flexible aluminum retractor made for the purpose. It is true that the cerebellum tolerates injuries without permanent serious damage, but if one desires the best possible functional result every effort should be made to avoid any trauma or contusion whatsoever.

IX. *The treatment of the tumor.* It would appear from the description of most of the operations recorded in the literature that attempts have been made, usually with the fingers, to enucleate these growths *in toto* with the almost invariable result of a fragmented lesion and hemorrhage so profuse that packing has been necessary. This without doubt has been largely responsible for the excessive mortality usually ascribed to shock.

Some of the German writers have attempted to subdivide their operative results into two classes—those for large tumors and those for smaller ones—and there can be little question but that the smaller tumors are more favorable, but as a matter of fact, most patients who at the present day come to operation for such a malady will have a sizable growth.

I doubt very much, unless some more perfected method is devised, whether one of these lesions can with safety be totally enucleated.* Furthermore if, as appears to be the case, there is almost always a projection of the growth into the porus, a stalk from which further growth may take place would necessarily remain after most if not after all so-called extirpation operations. The tumor is not only encircled by nerves, which are almost certain to be damaged—and a facial paralysis such as was produced in three cases in this series (*cf.* Fig. 160) is not a pleasant post-operative sequel—but it may also be encircled by arterial branches from the basilar of considerable size. The growth itself is relatively non-vascular, but it is the tearing of these surface vessels which produces the most serious complication, for they cannot be caught and ligated, and sufficient pressure to control them will inevitably contuse the brain stem.

Owing to these considerations we have come in recent years to abandon the idea of an extirpation and the usual custom is to bluntly incise or even to bisect the lesion after it has been as fully exposed as possible, and by an intracapsular procedure to enucleate as much of the contents as possible (*cf.* Figs. 251, 252, 253).† This may be possible as a single large mass (*cf.* Fig. 19) or as many smaller fragments (*cf.* Fig. 159). Such bleeding as occurs from the raw cavity may be readily checked by the insertion, directly into the cavity, of pledgets of wet cotton or of pledgets dipped into some fixative (e. g., Zenker's solution), which should be at hand for immediate preservation of the removed tissue if it is to be properly hardened for subsequent study. The more yellowish the tumors, and consequently the more fatty and less fibrous they are, the easier they are to enucleate by this method.‡

A long-handled blunt spoon similar to a gall bladder scoop is used for the purpose of enucleation, and despite the fibrous appearance of these tumors on section the tissue is soft enough to be readily scooped out in this way. One can usually tell when he is near the capsule, though, as stated, the enucleation has been overdone in one or two cases with resulting facial paralysis and occasionally one sees twitching of the shoulder, which indicates nearness to that part of the capsule overlain by the accessorius and adjacent nerves. Often-

---

* Leischner credits both Clairmont and Eiselsberg with a recovery after total removal, and Jiano,[14] a Roumanian surgeon, has recently recorded another case, but the experience with Case V in this series leaves one a little skeptical and I have learned that the tumor in one of the so-called successful enucleations reported in this country has proved to be a meningeal endothelioma and not an acoustic tumor.

† Dr. H. J. Boevé of Rotterdam writes me that he has had a successful operation of this type with an intracapsular enucleation, and he is told by Dr. Brouwer that it is the only patient in the Netherlands who has survived the removal of a tumor of the VIII$^{th}$ nerve.

‡ In a recent case, operated upon since the completion of this report, the tumor had undergone a marked degree of fatty transformation, and after it had been so far enucleated that the capsule began to collapse, it was possible with but little difficulty to strip most of the remaining shell away from the enclosing arachnoid (Figs. 254, 255), but even so the enucleation was not total.

Fig. 251

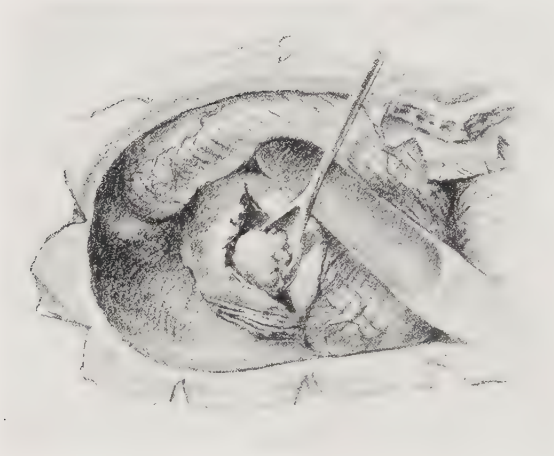

Fig. 252

Fig. 253

FIGS. 251, 252, 253.—Showing the method of treating the tumor by an intracapsular enucleation.

times the thin capsule, when unsupported by its tumor content, may collapse into the field, and the temptation is great to strip it out, and though fragments of considerable size may be thus removed (Figs. 254, 255) the procedure cannot be unreservedly recommended, as it was in so doing that the hemorrhage occurred which led to the operative complications in Cases VIII and XIX and the ultimate death of these patients, and in Case XXIX to a wide-spread injury of all the adjacent nerves.



Fig. 254 Fig. 255

Figs. 254, 255.—Showing the large fragment of capsule representing the lower pole of the tumor removed as one piece at end of enucleation, from a case operated upon during March, 1917.

When as much of the tissue has been removed as seems wise, the angle must

Fig. 256.—Showing early stage of closure of the median incision, the clamps identifying the corners of fascia and muscle being drawn up.

be left completely dry before the dislocated cerebellar hemisphere is allowed to settle back in place again and preparations are made for closure.

X. *The wound closure.* This stage of the operation, usually left to an assistant, is no less important and no less difficult, if properly done, than is the approach to the lesion. Indeed if the patient is to be given a sound neck and the post-operative leakage of cerebrospinal fluid from the wound is to be avoided, the most accurate closure in layers is necessary. In the average case it takes fully forty-five minutes to an hour to get in and as long to

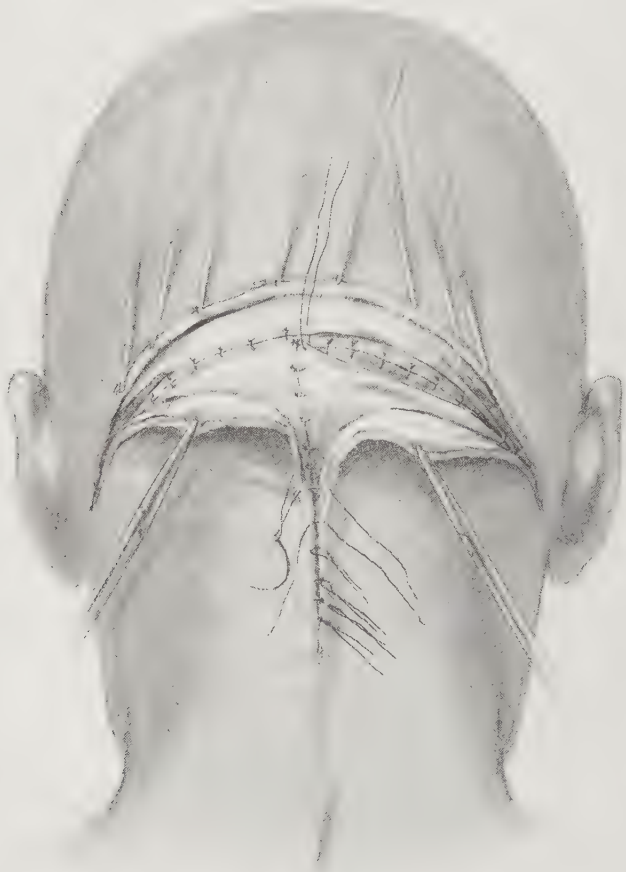

Fig. 257.—Showing further stage of the closure in layers.

close, so that, with the allotment of time for the treatment of the lesion, many of these operations from the beginning of the anæsthetization to the final closure approach or even exceed a three-hour period.

To take the strain off the flaps, the mass of clamps on each side is supported by the assistant who stands at the top of the head, and the four clamps, placed as described, on the corners of muscle and fascia are drawn up as shown in Fig. 256. The vertical incision is then closed accurately in several layers, three of which are indicated

in the sketch. Fine, waxed, black silk sutures passed on curved French needles are used throughout and tied three times so that they may be safely cut almost at the knot, thus avoiding any but the smallest amount of buried material.

The transverse incision is then sutured in turn, the crutch supporting the patient's head being raised and the neck extended slightly so as to facilitate bringing the edges together. A layer of interrupted sutures in the muscle (Fig. 257) is followed by a more secure second layer in the fascia and a third layer to accurately

Fig. 258.—Showing method of closure of scalp over buried layer of fine silk sutures "cut on the knot," approximating the galea.

approximate the galea. This layer not only catches all of the vessels of the scalp but holds the edges of the scalp so closely together that cutaneous sutures are only necessary in order to get an exact approximation of the skin edges. For this purpose fine round cambric needles are passed before tying, so that the wound edges may be "heaped up" and a broad approximation secured (Fig. 258). Unquestionably a continuous suture is quicker, but it does not give equally exact union of the edges nor can it be left so

long in the tissues, and the wound is of such magnitude and in such a position that it should be left until completely healed before the first dressing is made.

If precautions are not taken to have an absolutely secure closure, layer by layer, cerebrospinal fluid will find its way out, and though in one case in the series (*cf.* Fig. 108) it got through the muscles under the scalp, in no instance has an actual leak occurred nor have I seen such an accident in any case of cerebellar operation for many years.

The different point of view of various clinics in regard to these wounds is best seen in the manner of closure and the importance placed upon it. Horsley, for example, always favored a loose closure of cranial wounds so that an escape of cerebrospinal fluid would occur. It is the custom of the German clinics to drain these wounds and in many cases a gauze pack leading from the recess has been left leading from one angle of the incision.

Fig. 259.—Case XXV. Showing size and extent of original dressing.

Attention may be called to the fact that no vessels whatever are tied during the operation—in other words, no bits of tissue are strangulated by an encircling ligature. Such vessels as are divided in the extracranial tissues are occluded by the approximating sutures serially placed as the clamps are removed when the wound is closed. If the margin of the dura bleeds it is caught with silver clips, a device described elsewhere,[45] and if bleeding occurs from the nervous tissues themselves it is controlled by the placement of a fragment of raw muscle.

The minute black knots of the iron-dyed silk, it may be added, make very useful landmarks in case a subsequent exploration is necessary, for they remain practically unchanged for years and it is possible to retrace one's former steps by their aid on a second or a third session, such as was necessary in Case XXVIII. These small knots of fine black silk are probably stronger for their size and are far better tolerated by the tissues than any other suture material, provided no tissue is strangulated in their placement.

Special emphasis should again be laid on the importance of a secure and separate closure of the galea by buried sutures in all cranial wounds which are to resist tension. Another purpose of this, in addition to security, is a cosmetic one. A scalp wound which is otherwise closed tends to part and to leave a broad ugly scar owing to destruction of the hair follicles. An example of this is seen in Fig. 24, which may be compared with the photographs of other patients after operation in whom, as will be seen, the hair grows from the very edge of the fine linear scar.

XI. *The dressing.* A temporary dressing is applied and the patient is usually left unmoved on the table until consciousness is regained, and in a serious case in which respiratory difficulties have occurred, still longer. In critical cases the mere change of position from face to back may be enough to bring on a period of rhythmic respiration or, indeed, lead to its cessation. It is for this reason that a comfortable position on the table before the anæsthetic is started is all important.

I am not sure but that we overdo the size of the dressing which is applied when the patient is finally moved. We have adhered from the outset to a large hood dressing covered by a layer of well-starched crinoline (Fig. 259). This comes down onto the thorax and holds the head and neck reasonably immobile for the ten days it is worn. Patients in a bed capable of being elevated can sit up in a few days and owing to the large dressing and its firm support convalescence is reasonably free from discomforts. The dressing remains unchanged for from 10 to 12 days and at the end of this period the silver foil over the wound will be found crisp and dry, the sutures can be safely removed and the wound left without special support (Fig. 260).

Fig. 260.—Case XXV. Wound on tenth day at first dressing on removal of superficial scalp sutures.

All of these wounds have healed absolutely without reaction, as seen by the photographs, and even a stitch abscess with the fine, iron-dyed sutures is unknown. An infected wound or meningitis following a clean cranial operation is practically inexcusable at the present day.*

As mentioned when discussing the preparation of the wound, it is of distinct advantage, particularly to women, if the shaving is confined to as small a field as is reasonably safe. For though it may not be their customary coiffure, women nevertheless may, as shown in Figs. 261 and 262, effectively conceal the operative field as soon as the dressings are removed.

* The series of photographs (Figs. 241, 242, 259–262) were taken of a single patient, Case XXV, to illustrate this context.

From the outset this operation has seemed to possess certain advantages which are lacking in those heretofore described. Briefly, they lie in the wide bilateral exposure of the posterior surface of the cerebellum, and this, combined with the early evacuation of cerebrospinal fluid, serves to promptly relieve the intracranial tension which in turn permits of sufficient dislocation of the hemispheres to expose the recess without jeopardizing the medullary centers or traumatizing the adjacent cerebellar lobe. Moreover, carefully planned hæmostasis not only makes it possible to carry the procedure through

Fig. 261 Fig. 262

FIGS. 261, 262.—Case XXV. Photographs on patient's discharge the 21st day, illustrating manner of concealing the operative field.

in one session, but justifies an exact reapproximation of the divided tissues in layers without drainage, thereby greatly lessening the risk of post-operative complications as well as giving the patient a sound and presentable neck. The large cranial opening, furthermore, serves as an effective palliative measure not only against the possible early œdema but as a future decompression in view of the almost inevitable continuance of the growth.

Some of the imperfections of the operation, as it has been outlined, lie in its magnitude, the expenditure of time,—for one could hardly undertake two such procedures in a day,—and the fact that a

partial intracapsular enucleation is advocated at the present time rather than an attempted complete extirpation. These, however, are drawbacks which must necessarily characterize all operations for tumors in this difficult region if they are undertaken with due precautions and respect for life.

The technical details of the performance, as is true of all elaborate operations, have been gradually developed. As defects in the method became apparent from case to case, efforts were made to control them: as errors in judgment were committed they were so far as possible avoided in later operations. To this can be attributed the fact that we find four post-operative deaths in the first ten cases and only one in the last ten. The fatality in Case I demonstrated the necessity of head and shoulder supports. The accident of a respiratory failure in Case IV was a valuable experience from which was learned the possibility of carrying through an operation under artificial respiration and of freeing the medulla by continuing the dural incision through the foraminál region to the atlas or, as in the first operation in Case VIII, even to the axis after removal of the laminæ of the atlas. The comparative ease of an intracapsular enucleation was first learned from Case IV, but the same case has demonstrated that it is not a permanently curative measure. The hazards of attempting too radical procedures in the direction of total extirpations was a lesson drawn from the series of fatalities in Cases VIII, IX and X, but it was learned from Case VIII that a two-stage procedure after failure at the first session promises little, and from Case IX that these patients should be left in position on the table until out of their anæsthetic, owing to the risks of early change of position (*cf.* also Case XV). It was learned from Case XI that inhalation pneumonia may be forestalled in case of post-operative deglutitory difficulties by temporary recourse to nasal feeding, and also that transection of the cerebellar hemisphere is a very poor way of getting at one of these growths (*cf.* also Cases XV and XXVIII) and, therefore, that the opening must be made far enough to the side to make this unnecessary. The lowering of tension by a ventricular puncture, since largely utilized, was first undertaken in Case X, and Case XV shows that even a large tumor may be entirely overlooked during an exploration, which probably accounts for the number of uncertified though presumable acoustic tumors in our operative series.

## Statistical Results

The proof of the pudding is in the eating: the advantages of one operative method over another for a given lesion are told by the results. These in the case of any operation may be measured in various ways: (1) by the percentage of immediate or early fatalities; (2) by the post-operative complications which endanger or disturb the ease of convalescence; (3) by the degree of relief from suffering or avoidance of such sequels as blindness for the survivors; (4) by the capacity to resume a former occupation; (5) by the duration of the period of partial or total relief; and (6) by the measured prolongation of life. Unfortunately the only one of these on which surgical estimates are usually based is the first—the mere operative recovery—whereas statistics of the ultimate

result are rarely given and, it is to be admitted, are exceedingly difficult to assemble and to properly estimate.

(1) *The operative mortality.* This in the case of cerebellopontile-angle tumors, the majority of them as we have seen being acoustic tumors, has been variously estimated—though always high. This is so both for the cases assembled from miscellaneous reports in the literature as well as from the reports from individual clinics.

Henschen[79] in 1910 collected 43 cases with partial tumor removal of which only 8 lived for any length of time. Leischner's[109] statistics, gathered in 1911, including 10 cases from Eiselsberg's clinic, gave a mortality of 70 per cent. According to Fumarola[63] Krause had only 4 recoveries in a series of 30 angle tumors (86.6 per cent mortality) and Eiselsberg in 1912, 4 recoveries in 12 cases (66.6 per cent mortality). Tooth's statistics[151] of the operations with removal, complete or partial, of extracerebellar tumors during the years 1902 to 1912 at the National Hospital give 24 cases with 17 deaths attributed to the operation (70.8 per cent), whereas 11 out of 12 cases succumbed after a mere suboccipital decompression for tumor (91.6 per cent). In the 70 cases of which Henschen found record between 1910 and 1915 there was a 68.7 per cent mortality.

Shocking as these figures are and desperate as the condition must be which justifies operation attended with such high risks, it must be acknowledged that they represent the experience of surgeons who at the time of their report had had but few cases, and whose later records would have been far better. After the first operation the surgical mortality in the writer's series of acoustic tumors was 100 per cent. After the first 10 cases it was lowered to 40 per cent, after 15 cases it had dropped to 33.3 per cent, after 20 cases to 30 per cent, after 25 cases to 24 per cent, and after 30 cases to 20 per cent; and it must continue to fall until it drops to 10 or to 5 per cent or better, even though the total figures must carry the burden of early inexperience. In the Baltimore series of 11 operated cases the mortality was 35.4 per cent, in the Boston series of 18 it has been 11.1 per cent, and it may be pointed out not only that in a number of these patients more than one operation has been performed, so that the operative mortality would be considerably lower than the case mortality, but also that there have been an equally large number of cerebellar operations for presumable tumors of the angle which have not been surgically verified, all of which have recovered except the two included in this report, one of them, Case VII, dying from the consequences of a misdirected operation over the cerebrum, and the other, Case XV, from the immediate effects of a second negative cerebellar exploration.

(2) *The convalescence.* This is disturbed chiefly by the confinement in the large crinoline dressing, which may be unnecessary but, being fearful of too free movements, it has seemed to us the lesser of two evils. The relief of headache more than atones for the slight discomforts in the wound itself, and though dizziness, vomiting and dysarthria may persist for a time, or even be increased, they usually subside in a few days. The assurance of primary wound healing without a drain or cerebrospinal-fluid leak goes far toward easing the recovery, and as a rule the patients should be sitting up in a reclining bed in a few days.

(3) *The degree of symptomatic relief.* This is difficult to estimate, but it is usually enormous, particularly on the side of the general pressure symptoms, and there is often considerable amelioration in the local manifestations, even after a simple decompression with the mere free opening of the obstructed lateral cistern. This is well shown by Case IV, which, though histologically unverified, has, in view of the distended porus, been included in the series as a type case.

Another important result is the saving of vision. Unfortunately at the time of their admission all of these patients have shown a marked choked disc or its late effects. Cases II and XXX were already blind. In six cases (e. g., Case XXVII) vision on admission was reduced to shadows and in three of them mere light perception (e. g., Cases XI and XII) has been retained following the operation. In eighteen there was an advanced grade of choked disc, usually with beginning secondary atrophy: of the fourteen survivors five retained normal vision, five retained useful vision, and four impaired vision. In the remaining four (Cases VIII, XIII, XXII and XXVI) the process was comparatively early and normal vision has been retained by the three survivors.

It has taken many years and much insistance to make the profession appreciate that a choked disc is a mechanical process due to tension which can be surgically relieved even though a localizing diagnosis cannot be made. It will doubtless take many years more to make them feel that it is somewhat disgraceful under these circumstances to permit a patient to become blind or even to allow the process to advance to such a stage that vision becomes impaired.

(4) *The resumption of a former occupation.* When this entails stress and vigor and manual dexterity, it possibly could hardly be expected after an operation for an acoustic tumor which has reached a large size. Most of the women, however, have been able to resume their household duties. Thus a patient (Case IV) with an unremoved tumor, despite her local symptoms, has led an active life, and for the past five years since her husband's death has been able to conduct his large affairs and bring up her several children practically unaided. Case V, on the other hand, with the twice performed enucleation, though free from discomforts and able to be about, must be regarded as more or less of an invalid. Case VI was able to resume active work on his farm for three years. Case XI has been, owing to her persisting ataxia, a distinct invalid for the five years and Case XII for the same reason is little better.

The "subsequent notes" appended to the more recent cases in the Boston series give a much better showing, and for the time being Case XIII has been a wage earner and Cases XIV, XVI, XX and XXVII would be except for their lowered vision. Cases XVII, XVIII, XXI, XXII and XXV have largely resumed their former activities, and in regard to the later patients in the series, all of whom have so far done well, it is too early to speak on the ground of occupation.

Good as they are, these results on the basis of a wage-earning capacity would be far better had the operations been undertaken even a few months earlier, and I hope to see the day when the proportion of blind to seeing patients admitted to the clinic suffering from tumor is materially diminished.

(5) *The duration of relief.* A certain measure of relief from general pressure symptoms is likely to be permanent. The outlook for permanent relief from local symptoms is less bright. Just how long the relief may last depends on many factors—the size attained by the tumor at the time of the operation, the rapidity of its growth, and the relative thoroughness of the enucleation. It will take a much larger series of cases than the present one and a much longer period of time must elapse before one can speak with any accuracy on this score.

Though there are exceptions in the series (with extremes shown by Case IV, whose period of relief has persisted 7 years and 10 months, and Case VII who had but brief relief after a decompression) I would regard a three-year period after a wide decompression and partial enucleation as a fair estimate of an expected period of relief before a return of pressure symptoms. This estimate is of course based on an experience with large tumors, and doubtless with small ones (e. g., Case XXV) it would be much longer.

It is a natural expectation that this procedure will come in time to be done more frequently and at an earlier stage of the growth, and this will mean far more perfect recoveries with, perchance, an occasional total enucleation which will mean a permanent cure.

(6) *The prolongation of life.* The mere lengthening of life is not a desirable basis on which to estimate end results unless the life has been made better worth living. I can hardly believe that such a result as was afforded by the primary decompression in Case XV was worth while, and it was this feeling which led to the second, ineffectual and disastrous, attempt to reach the tumor.

It is hardly possible to estimate the duration of life without operation, though Tooth[183] has attempted to do this, and finds for the group of extracerebellar tumors in his series that 11.8 months represents the average survival period if the cases are left to run their course. The only verified case in the writer's series which was not operated upon, Case XXX, lived only seven months. This all depends, of course, on how early the diagnosis can be made and the size and rapidity of growth of the tumor at the time the patient comes under observation.*

It may be presumed that the majority of the patients in this series had not long to live in view of the comparatively advanced symptoms at the time of their admission. Cases II and III, both of whom had an advanced process, one with blindness and the other nearly so, both survived over three and one-half years after the decompression with removal of but a small fragment of the tumor, and this may perhaps be taken as the average expectation of life under these circumstances. Then, too, Case V after about the same length of time,—namely, three and one-half years,—had a return of symptoms, with a secondary operation and again a period of relief which has lasted four years. However, Case VI lived 6 years and 7 months after a similar single operation, the disease having been allowed to run its further course without intervention.

Of the cases in the Boston Series it is too early to speak: they certainly should average far better than those in the Baltimore group. Even as they

* In his estimates of the survival period of tumors with and without operation, Tooth unfortunately does not dwell fully on the acoustic tumors, which probably are represented by the extracerebellar "fibrogliomas." These he is inclined to include with the gliomas proper, the average survival period of which he estimates to be 10.1 months.

stand, leaving much to be desired, the results are far more encouraging than any heretofore reported. Sieskind,[166] writing in Oppenheim's clinic, from which a goodly number of these acoustic tumors have been referred for operation, states that the operative mortality would be much higher than is usually estimated if the fatalities that immediately follow operation, or occur very shortly after, were included, and points out that of all Krause's successfully operated cases only one patient was still living in 1908 at the time of his report. According to Leischner, the longest recovery after operation in Eiselsberg's clinic at the time of his writing in 1911 was 18 months. Of the thirty-six operative cases in the extracerebellar group (doubtless including the more favorable meningeal as well as the acoustic lesions) in Tooth's[183] series from the National Hospital, seven of the verified cases were regarded as recoveries (4 still living after 7 months to 8 years), giving an average survival period of thirty-nine months: of the twelve unverified though decompressed cases only one survived, for three years. With these figures before him, Tooth's statement, to the effect that one must not allow his judgment in regard to operations to become biased by a few brilliant successes in the face of a preponderance of fatalities, can be thoroughly sympathized with.

These unfavorable reports are quoted not in an odious spirit of comparison, for the writer realizes that in 1908 and 1911 and 1913 his own results were none too encouraging, but merely to show that with a better method and more painstaking type of operative procedure more favorable results may be recorded today.

In the accompanying Table 5 there have been gathered the data from which the surgical end results of this series, so far as possible, may be computed. There are many elements to be considered, the time which has elapsed since the onset of recorded pressure symptoms appearing to the writer to be the point from which the expectation of life in an unoperated case could be most safely calculated. The table shows that in this series the average duration of symptoms before the patient's admission was about six years and the average duration of evident pressure symptoms about two years, evidencing the fact that the average case was an advanced one. The case mortality has been 20.7 per cent, the operative mortality, based on the number of suboccipital operations, 39 in all, has been 15.4 per cent.*

Most of the fatalities, it will be observed, occurred in cases with extreme pressure symptoms, but it is safe to say that the likelihood of a fatality depends as much upon the character of the operation performed as upon the size of the tumor and the stage of the symptoms it has produced. Nevertheless it is to be hoped that we may see these cases operated upon at a period averaging at least two years earlier, on the first appearance of general pressure symptoms, for it will be quite possible under these circumstances not only to lower the mortality figures practically to zero, but at the same time to completely forestall the loss of vision. Unquestionably for this most difficult type of tumor far better operative returns may in the future be expected from our own and from other clinics.

---

* Subsequent to February 1st, when these notes and computations were made by Dr. Cushing, four other patients were admitted to the clinic and operated upon with the usual procedure, with excellent surgical results. If these cases were included, it would lower the case mortality to 18.1 per cent, and the operative mortality to 13.9 per cent.—L. E.

One cannot gauge the benefit of operations from figures nor can one chart or tabulate such factors as relief from pain and preservation of vision, and so long as this equation must be taken into consideration, statistics regarding the results of brain tumor operations in general are deceptive and can be made to prove almost anything the author desires, no matter how honest he may be.

TABLE 5.—CHART OF THE 29 OPERATIVE CASES IN THE VERIFIED SERIES

| Case No. | On first admission | | | Operations | | | Operative fatality | Survival period after 1st operation | Living from 1st operation to Feb. 1, 1917* |
|---|---|---|---|---|---|---|---|---|---|
| | Recorded symptoms | Pressure syndrome | | | | | | | |
| | Duration | Duration | Type | Date | No. | Character | | | |
| I | Many yrs. | 3 yrs. | Extreme | Jan. 16, 1906 | 1 | 1st stage exploration | 3rd day. Pneumonia | | |
| II | Several yrs. | 9 mos. | Extreme | Apr. 3, 1906 | 1 | Partial enucleation | | 3 yrs. 8 mos. | |
| III | 4 yrs. | 3 yrs. | Advanced | Sept.15, 1906 | 1 | Partial enucleation | | 3 yrs. 7 mos. | |
| IV | 9 yrs. | 4 yrs. | Extreme | Mar. 6, 1909 | 1 | Primary exposure | | | 7 yrs. 11 mos. |
| | | | | Apr. 23, 1909 | 2 | Cyst evacuation | | | |
| V | 7 yrs. | 1 yr. | Extreme | May 21, 1909 | 1 | Radical enucleation | | | 7 yrs. 9 mos. |
| | | | | Nov. 21, 1912 | 2 | Radical enucleation | | | |
| VI | 5 yrs. | 3 yrs. | Advanced | Jan. 27, 1910 | 1 | Partial enucleation | | 6 yrs. 7 mos. | |
| VII | 1.5 yrs. | 1.5 yrs. | Advanced | June 4, 1910 | 1 | Exploration & Decompression | | 0 yrs. 11 mos. | |
| VIII | 2.5 yrs. | 1 yr. | Advanced | Jan. 4, 1911 | 1 | Tumor exposure | | | |
| | | | | Mar. 6, 1911 | 2 | Partial extirpation | | | |
| | | | | Apr. 1, 1911 | 3 | Radical extirpation | 36 hours. Shock | | |
| IX | 10 yrs. | 2 yrs. | Advanced | Oct. 17, 1910 | 1 | Attempted extirpation | 1 hour. Respiratory failure | | |
| X | 4 yrs. | 3 yrs. | Advanced | Apr. 27, 1911 | 1 | Attempted extirpation | 6th day. Pneumonia | | |
| XI | 4 yrs. | 2.5 yrs. | Advanced | May 1, 1911 | 1 | Partial extirpation | | | |
| | | | | June 2, 1911 | 2 | Radical extirpation | | | 5 yrs. 9 mos. |
| XII | 2 yrs. | 8 mos. | Advanced | Sept. 6, 1913 | 1 | Partial enucleation | | | |
| | | | | Oct. 17, 1913 | 2 | Extensive enucleation | | | 3 yrs. 5 mos. |
| XIII | 7 yrs. | 6 mos. | Medium | Dec. 23, 1913 | 1 | Partial enucleation | | | 3 yrs. 1 mo. |
| XXVIII | 3 yrs. | 1.5 yrs. | Medium | Mar. 12, 1914 | 1 | Exploration & Decompression | | | |
| | | | | May 5, 1915 | 2 | Negative exploration | | | 2 yrs. 11 mos. |
| | | | | Jan. 22, 1917 | 3 | Extensive enucleation | | | |
| XIV | 2 yrs. | 1.5 yrs. | Advanced | Nov. 10, 1914 | 1 | Partial enucleation | | | 2 yrs. 3 mos. |
| XV | 2 yrs. | 1 yr. | Extreme | Nov. 23, 1914 | 1 | Exploration & Decompression | | | |
| | | | | Feb. 12, 1915 | 2 | Exploration & Decompression | 10 hours. Respiratory failure | | |
| XVI | 1.5 yrs. | 1 yr. | Extreme | May 21, 1915 | 1 | Radical enucleation | | | 1 yr. 9 mos. |
| XVII | 3 yrs. | 6 mos. | Extreme | June 22, 1915 | 1 | Radical enucleation | | | 1 yr. 8 mos. |
| XVIII | 4.5 yrs. | 4 mos. | Advanced | June 13, 1915 | 1 | Partial enucleation | | | 1 yr. 6 mos. |
| XIX | 3 yrs. | 2 yrs. | Extreme | Sept. 4, 1915 | 1 | Attempted extirpation | 6th day. Pneumonia | | |
| XX | 4 yrs. | 1.5 yrs. | Advanced | Oct. 7, 1915 | 1 | Partial enucleation | | | 1 yr. 4 mos. |
| XXI | 5 yrs. | 1.5 yrs. | Advanced | Oct. 5, 1915 | 1 | Partial enucleation | | | 1 yr. 4 mos. |
| XXII | 9 yrs. | 1 yr. | Advanced | Jan. 22, 1916 | 1 | Extensive enucleation | | | 1 yr. |
| XXIII | 2 yrs. | 2 yrs. | Advanced | Apr. 20, 1916 | 1 | Fragmentary enucleation | | | 10 mos. |
| XXIV | 2.5 yrs. | 1 yr. | Advanced | Oct. 13, 1916 | 1 | Partial enucleation | | | |
| | | | | Jan. 15, 1917 | 2 | Extensive enucleation | | | 4 mos. |
| XXV | 6 mos. | 6 mos. | Advanced | Nov. 6, 1916 | 1 | Extensive enucleation | | | 3 mos. |
| XXVI | 2 yrs. | 6 mos. | Medium | Nov. 23, 1916 | 1 | Fragmentary enucleation | | | 2 mos. |
| XXVII | 1 yr. | 1 yr. | Advanced | Dec. 26, 1916 | 1 | Partial enucleation | | | 1 mo. |
| XXIX | 3 yrs. | 2 yrs. | Advanced | Jan. 26, 1917 | 1 | Extensive enucleation | | | 1 mo. |

* All of these patients were living July 1, 1917, and 5 months may therefore be added to their survival period.

## *Bibliography*

The assembled bibliography of the subject is too large to be given in full. Many of the papers consist merely of individual case reports or brief society notices, and unless they contained some point of unusual interest they have rarely been quoted here, except in the case of American literature, which has heretofore been largely neglected. The articles of Henschen and Fumarola give the titles of the majority of these fugitive publications. The articles to which the author is particularly indebted are as follows. They represent only about one-third of the references which have been traced to the original source.


1. **Abercrombie (J.).** *Pathological and practical researches on diseases of the brain and the spinal cord. Edinburgh, A. Balfour & Co., Ed. 2,* ***1829,*** *443, Case XLII.*

2. **Adrian (C.).** *Die multiple Neurofibromatose. Centralbl. f. d. Grenzgeb. d. Med. u. Chir.,* ***1903,*** *vi, 81.*

3. **Alagna (G.).** *Sur les tumeurs de l'acoustique. Arch. internat. de laryngol. (etc.),* ***1909,*** *xxvii, 751: xxviii, 66, 461, 859;* ***1910,*** *xxix, 142.*

4. **Alexander (G.).** *Zur Kenntnis der Akustikustumoren. Ztschr. f. klin. Med.,* ***1907,*** *lxii, 447–456.*

5. **Alexander (G.) & Frankl-Hochwart (L. v.).** *Ein Fall von Akustikustumor. Arb. a. d. neurol. Inst. a. d. Wien. Univ.,* ***1904,*** *xi, 385–399.*

6. **Alexander (G.) & Obersteiner (H.).** *Das Verhalten des normalen Nervus cochlearis in Meatus auditorius internus. Ztschr. f. Ohrenh.,* ***1908,*** *lv, 78–91.*

7. **Alquier (L.).** *Volumineux tubercule caséifié de la calotte protubérantielle étude anatomo-clinique. Rev. neurol.,* ***1906,*** *xiv, 406–410.*

8. **Alquier (L.) & Klarfeld (B.).** *Sur le diagnostic des tumeurs de la protubérance annulaire. Gaz. d. hôp.,* ***1911,*** *lxxxiv, 873; 1033; 1109; 1157.*

9. *Huit cas de tumeurs, juxta ou intraprotubérantielles avec autopsie. Étude des signes de localisation. Rev. neurol.,* ***1911,*** *xxi, 391–392.*

10. **Aoyagi (T.) & Kyunō (K.).** *Über die endothelialen Zellzapfen in der Dura mater cerebri und ihre Lokalisation in derselben, nebst ihrer Beziehung zur Geschwulstbildung in der Dura mater. Neuroglia,* ***1912,*** *xi, 1–12.*

11. **Babinski (J.).** *De l'asynergie cérébelleuse. Rev. neurol.,* ***1899,*** *vii, 806–816.*

12. *Hémiasynergie et hémitremblement d'origine cérébello-protubérantielle. Rev. neurol.,* ***1901,*** *xix, 260; 422.*

13. **Babinski (J.) & Tournay (A.).** *Les symptômes des maladies du cervelet et leur signification. Tr. Internat. Cong. Med., Lond.,* ***1913,*** *Sec. XI, 1–58.*

14. **Bacaloglu (C.) & Jiano.** *Tumeur ponto-cérébelleuse (fibrome); extirpation, guérison. Rev. de méd.,* ***1914–15,*** *xxxiv, 760–775.*

15. **Baisch (B.).** *Über Operationen in der hinteren Schädelgrube. Beitr. z. klin. Chir.,* ***1908,*** *lx, 479–507.*

16. **Ballance (C.).** *Some points in the surgery of the brain and its membranes. London, Macmillan & Co.,* ***1907,*** *276.*

17. **Bárány (R.).** *Untersuchungen über den vom Vestibularapparat des Ohres reflektorisch ausgelösten rhythmischen Nystagmus und seine Begleiterscheinungen. Monatsschr. f. Ohrenh.,* ***1906,*** *xl, 193–297.*

    *Operationsmethode zur Entfernung von Akustikustumoren. Ztschr. f. Ohrenh.,* ***1908,*** *lv, 414–415.*

    *Die nervösen Störungen des Cochlear- und Vestibularapparates. Cf. v. Lewandowski: Handbuch der Neurologie, Berlin,* ***1910,*** *i, 919–958.*

    *Spezielle Pathologie der Erkrankungen des Cochlear- und Vestibularapparates. Ibid., iii, 811–873.*

    *Die Ausführung der vestibularen Kleinhirnprüfung. Tr. Internat. Cong. Med., Lond.,* ***1913,*** *Sec. XI, 53–54.*

18. **Bassoe (P.) & Nuzum (F.).** *Report of a case of central and peripheral neurofibromatosis. J. Nerv. & Ment. Dis.,* ***1915,*** *xlii, 785–796.*

19. **Bell (C.).** *The nervous system of the human body. London,* ***1830,*** *Appendix of cases, pp. cxii–cxiv.*

20. **Beneke (R.).** *Casuistische Beiträge zur Geschwulstlehre. II. Zwei Fälle von "multiplen Hirnhernien." Arch. f. path. Anat. (etc.),* ***1890,*** *cxix, 60–75.*

21. **Berggrün (E.).** *Ein Fall von allgemeiner Neurofibromatose bei einem 11-jährigen Knaben. Arch. f. Kinderh.,* ***1897,*** *xxi, 89–113.*

22. **Bielschowsky (M.).** *Zur Histologie und Pathologie der Gehirngeschwülste. Deutsche Ztschr. f. Nervenh.,* ***1902,*** *xxii, 54–99 (Case II).*

23. **Bielschowsky (M.) & Schwabach (D.).** *Ein Fall von Myxo-Fibrom des Felsenbeins mit multipler Hirnnervenlähmung. Deutsche med. Wchnschr.,* ***1909,*** *xxxv, 793–794.*

24. **Biggs (G.).** *A case of cerebellar tumor involving the auditory nerve. Arch. Otol.,* ***1908,*** *xxxvii, 468.*

25. *Case of multiple intracranial tumors with involvement of both auditory nerves. Lancet,* ***1909,*** *ii, 14–15.*

26. **Boettcher.** *Über die Veränderungen der Netzhaut und des Labyrinths in einem Fall von Fibrosarcom der N. acusticus. Arch. f. Augen- u. Ohrenheilk.,* ***1871,*** *ii, pt. 2, 87–115. Also: Arch. Ophth. & Otol.,* ***1873,*** *iii, 134–172.*

27. **Borchardt (M.).** *Zur Operation der Tumoren des Kleinhirnbrückenwinkels. Berl. klin. Wchnschr.,* ***1905,*** *xlii, 1033–1035.*

28. *Über Operationen in der hinteren Schädelgrube inkl. der Operation von Tumoren des Kleinhirnbrückenwinkels. Arch. f. klin. Chir.,* ***1906,*** *lxxxi, 386–432.*

29. *Diagnostik und Therapie der Geschwulstbildungen in der hinteren Schädelgrube. Ergebn. Chir. u. Orthop.,* ***1911,*** *ii, 131–173.*

30. **Borst (M.).** *Echte Geschwülste. Cf. Aschoff: Pathologische Anatomie. Jena, Ed. 3,* ***1913,*** *i, 686.*

31. **Boyer (M.).** *Tumeur cancéreuse de la fosse occipitale comprimant le cervelet, la moelle, et la plupart des nerfs qui se distribuent au côté droit de la face. Arch. gén. de méd.,* ***1835,*** *Series 2, viii, 91–98.*

32. **Bramwell (B.).** *On the localisation of intracranial tumours. Brain,* ***1899,*** *xxii, 1–70.*

33. **Bregman (L.) & Krukowski (G.).** *Beitrag zu den Geschwülsten des Kleinhirnbrückenwinkels. Deutsche Ztschr. f. Nervenh.,* ***1911,*** *xlii, 373–398.*

34. **Bright (R.).** *Reports of medical cases selected with a view of illustrating the symptoms and care of diseases by a reference to morbid anatomy. Diseases of the brain and nervous system. London,* ***1831,*** *ii, 48–52.*

35. **Bruce (A.).** *The localisation and symptoms of disease of the cerebellum considered in relation to its anatomical connections. Tr. Med.-Chir. Soc., Edinb.,* ***1899,*** *xviii, 85–97.*

36. **Brückner (C.).** *Ein Fall von Tumor in der Schädelhöhle. Berl. klin. Wchnschr.,* ***1867,*** *iv, 303–306.*

37. **Bruns (L.).** *Metastatisches Karzinom an der Basis der hinteren Schädelgrube. Neurol. Centralbl.,* ***1906,*** *xxv, 542.*

38. *Die Geschwülste des Nervensystems. Berlin,* ***1908,*** *220.*

39. **Collier (J.).** *The false localizing signs of intracranial tumor. Brain,* ***1904,*** *xxvii, 490–508.*

40. **Collin & Barbé.** *Gliome de l'angle ponto-cérébelleux. Rev. neurol.,* ***1911,*** *xxi, 601–603.*

41. **Cruveilhier (J.).** *Anatomie pathologique du Corps Humain. Paris,* ***1835–1842,*** *ii, Part 26, pp. 1–8.*

42. **Cushing (H.).** *The taste fibres and their independence of the Nervus Trigeminus. Johns Hopkins Hosp. Bull.,* ***1903,*** *xiv, 71–78.*

43. *The establishment of cerebral hernia as a decompressive measure for inaccessible brain tumor, with the description of intermuscular methods of making a bone defect in temporal and occipital regions. Surg., Gynec. & Obst.,* ***1905,*** *i, 297–314.*

44. *Strangulation of the nervi abducentes by lateral branches of the basilar artery in cases of brain tumor. Brain,* ***1910,*** *xxxiii, 204–235.*

45. *The control of bleeding in operations for brain tumors, with the description of silver "clips" for the occlusion of vessels inaccessible to the ligature. Ann. Surg.,* ***1911,*** *liv, 1–19.*

46. *On convulsive spasms of the face produced by cerebellopontine tumors. J. Nerv. & Ment. Dis.,* ***1916,*** *xliv, 312–321.*

47. *Anosmia and sellar distension as misleading signs in the localization of a cerebral tumor. Ibid., 415–423.*

48. *The purpose and technical steps of a subtemporal decompression. In publication.*

49. **Cushing (H.) & Walker (C.).** *Distortions of the visual fields in cases of brain tumor. Binasal hemianopsia. Arch. Ophth.,* ***1912,*** *xli, 569 (Case IV).*

50. **Dalton (J.).** *On the cerebellum as the centre of co-ordination of the voluntary movements. Am. J. M. Sc.,* ***1861,*** *xli, 83–88.*

51. **Dana (C.).** *The cerebellar seizure (cerebellar fits), a syndrome characteristic of cerebellar tumors. N. York M. J. (etc.),* ***1905,*** *lxxxi, 270–272.*

52. **Druault (A.).** *Sarcome du conduit auditif interne. Ann. d. mal. de l'oreille, du larynx (etc.),* ***1898,*** *xxiv, 113–119.*

53. **Eichelberg (F.).** *Zur Diagnostik und Therapie der Gehirntumoren (Bericht über 43 Fälle). Deutsche Ztschr. f. Nervenh.,* ***1914,*** *li, 288–313.*

54. **Eiselsberg (A.).** *Über die chirurgische Behandlung der Hirntumoren. Tr. Internat. Cong. Med., Lond.,* ***1913,*** *Sec. VII, 203–207.*

55. **Elsberg (C.) (with Fraenkel & Hunt).** *Ann. Surg.,* ***1904,*** *xl, 293–319.*

56. **Ferrier (D.) & Turner (W.).** *A record of experiments, illustrative of the symptomatology and degenerations following lesions of the cerebellum, etc. Phil. Tr., Lond.,* ***1894,*** *clxxxv, 476.*

57. **Fester (O).** *Zur Casuistik der Psammome am Centralnervenapparat. Berl. klin. Wchnschr.,* ***1878,*** *xv, 97–100.*

58. **Foix (C.) & Kindberg (L.).** *Tumeurs de l'angle ponto-cérébelleux sans symptômes cérébelleux. Rev. neurol.,* ***1911,*** *xxii, 638–642.*

59. **Fraenkel (J.) & Hunt (J.).** *Tumors of the ponto-medullo-cerebellar space. Acoustic neuromata. (Central neurofibromatosis.) Med. Rec., N. Y.,* ***1903,*** *lxiv, 1001.*

60. **Fraenkel (J.); Hunt (J.); Woolsey (G.) & Elsberg (C.).** *Contribution to the surgery of neurofibroma of the acoustic nerve; with remarks on the surgical procedure. Ann. Surg.,* ***1904,*** *xl, 293–319.*

61. **Frankl-Hochwart (L. v.).** *Der Ménière'sche Symptomenkomplex. Wien,* ***1895.*** *Cf. Nothnagel, H.: Specielle Pathologie und Therapie.* ***1898,*** *xi, Part 2, 1–74.*

62. **Frazier (C.).** *Remarks upon the surgical aspects of tumors of the cerebellum. N. York M. J. (etc.),* ***1905,*** *lxxxi, 272; 332.*

63. **Fumarola (G.).** *Das Syndrom der Kleinhirnbrückenwinkeltumoren. Klinischer und pathologisch-anatomischer Beitrag. Arch. f. Psychiat.,* ***1915,*** *lv, 781–908.*

64. **Funkenstein (O.).** *Ein Beitrag zur Kenntnis der Tumoren des Kleinhirnbrückenwinkels ("zentrale Neurofibromatose," "Akustikusneurome"). Mitt. a. d. Grenzgeb. d. Med. u. Chir.,* ***1905,*** *xiv, 157–194.*

65. **Gairdner (W.) & Haldane (D.).** *Two cases of tumor at the base of the brain, with remarkably contrasted symptoms. Edinb. M. J.,* ***1861,*** *vi, 788–798.*

66. **Garré.** *Cf. Funkenstein, O.: Ein Beitrag zur Kenntnis der Tumoren des Kleinhirnbrückenwinkels ("zentrale Neurofibromatose," "Akustikusneurome"). Mitt. a. d. Grenzgeb. d. Med. u. Chir.,* ***1905,*** *xiv, 157–194.*

67. **Garrod.** *Papillomatous tumour in the fourth ventricle of the brain. Lancet,* ***1873,*** *i, 303.*

68. **Gibson (G.).** *Remarks on the results of surgical measures in a series of cerebral cases. Edinb. M. J.,* ***1896,*** *xli, 689–692.*

69. **Gierlich.** *Zur Symptomatologie der Tumoren des Kleinhirns und des Kleinhirnbrückenwinkels. Deutsche med. Wchnschr.,* ***1908,*** *xxxiv, 1800–1804.*

70. **Goerke.** *Demonstration mikroskopischer Präparate von Akustikustumoren. Verhandl. d. deutsch. otol. Gesellsch.,* ***1901,*** *x, 144–146.*

71. **Gomperz (B.).** *Beiträge zur pathologischen Anatomie des Ohres. Arch. f. Ohrenh.,* ***1890,*** *xxx, 216–229.*

72. **Goodhart (S.).** *A case for diagnosis: probably multiple sclerosis. J. Nerv. & Ment. Dis.,* ***1910,*** *xxxvii, 436–437.*

73. **Gowers (W.).** *A clinical lecture on a metastatic mystery. Lancet,* ***1905,*** *ii, 1593–1597.*

74. **Grasser (C.).** *Über das primäre Endotheliom des Mittelohres bzw. des Felsenbeins. Ztschr. f. Ohrenh.,* ***1909,*** *lix, 225–243.*

75. **Grey (E.).** *Studies on the localization of cerebellar tumours.*

I. *Posterior new growths without nystagmus. J. Am. M. Ass.,* ***1915,*** *lxv, 1341–1345.*
II. *Staggering gait, limb ataxia, the Romberg test and adiadokokinesia. J. Nerv. & Ment. Dis.,* ***1915,*** *xlii, 670–679.*
III. *The position of the head and suboccipital discomforts. Ann. Surg.,* ***1916,*** *lxiii, 129–139.*
IV. *The pointing reaction and the caloric test. Am. J. M. Sc.,* ***1916,*** *cli, 693–704.*
V. *The cranial nerves. Johns Hopkins Hosp. Bull.,* ***1916,*** *xxvii, 251–262.*

76. **Grinker (J.).** *Three cases of tumor in the cerebellopontile angle. J. Am. M. Ass.,* ***1910,*** *lv, 1961–1965.*

77. **Hartmann (F.).** *Die Klinik der sogenannten Tumoren des Nervus acusticus. Ztschr. f. Heilk.,* ***1902,*** *xxiii, 391–440.*

78. **Henneberg & Koch.** *Über "centrale" Neurofibromatose und die Geschwülste des Kleinhirnbrückenwinkels (Acusticusneurome). Arch. f. Psychiat.,* ***1902,*** *xxxvi, 251–304.*

79. **Henschen (F.).** *Über Geschwülste der hinteren Schädelgrube, insbesondere des Kleinhirnbrückenwinkels. Jena,* ***1910.***

80. *Die Akustikustumoren, eine neue Gruppe radiographisch darstellbarer Hirntumoren. Fortschr. a. d. Geb. d. Röntgenstrahlen,* ***1912,*** *xviii, 207–216.*

81. *Zur Histologie und Pathogenese der Kleinhirnbrückenwinkeltumoren. Arch. f. Psychiat.,* ***1915,*** *lvi, 21–122.*

82. **Hermanides (R.).** *Operatieve Behandeling van hersengezwellen. Inaug. Diss., Utrecht,* ***1894,*** *111.*

83. **Heuer (G.) & Dandy (W.).** *A report of seventy cases of brain tumor. Johns Hopkins Hosp. Bull.,* ***1916,*** *xxvii, 224–237.*

84. **Hezel.** *Ein Fall von Akustikustumor. Ztschr. f. Laryngol., Rhinol. (etc.),* ***1912,*** *v, 973–980.*

85. **Higier (H.).** *Epithelioma psammosum am Boden des 3. Hirnventrikels und interpedunkuläre Arachnoidealzyste, einen Tumor des Kleinhirnbrückenwinkels vortäuschend. Neurol. Centralbl.,* ***1913,*** *xxxii, 741–750.*

86. **Hildebrand (O.).** *Beitrag zur Chirurgie der hinteren Schädelgrube auf Grund von 51 Operationen. Arch. f. klin. Chir.,* ***1912–13,*** *c, 597–702.*

87. **Hubrich (M.).** *Geschwulst des Kleinhirns, Druck auf die Medulla oblongata. Arch. f. Psychiat.,* ***1875,*** *v, 549–554.*

88. **Hulles (E.).** *Beiträge zur Kenntnis der sensiblen Wurzeln der Medulla oblongata beim Menschen. Arb. a. d. neurol. Inst. a. d. Wien. Univ.,* ***1906,*** *xiii, 392–398.*

89. **Jackson (H.).** *Tumour at the base of the brain.—Death.—Autopsy.—Clinical remarks. Med. Times & Hosp. Gaz.,* ***1865,*** *i, 626–627.*

90. **Jakob (A.).** *Kasuistischer Beitrag zur Lehre von den Kleinhirnbrückenwinkeltumoren und von der diffusen Sarkomatose der Meningen des Zentralnervensystems. Ztschr. f. d. ges. Neurol. u. Psychiat.,* ***1910,*** *iii, 249–270.*

91. **Josefson (A.).** *Zwei Fälle von intrakraniellem Acusticustumor. Deutsche Ztschr. f. Nervenh.,* ***1910,*** *xxxix, 468–485.*

92. **Jumentié (J.).** *Les tumeurs de l'angle ponto-cérébelleux. (Étude anatomo-pathologique et clinique.) Paris, Steinhill Ed.,* ***1911.***

93. **Kato (T.).** *Ein kasuistischer Beitrag zur Kenntnis von teratoiden Geschwülsten im Kleinhirnbrückenwinkel. Jahrb. f. Psychiat.,* ***1915,*** *xxxv, 43–57.*

94. **Keen (W.).** *The dangers of ether as an anesthetic. Ether Day Address, Mass. Gen. Hosp. Series,* ***1915,*** *1–29.*

95. **Kennedy (R.).** *A case of intracranial tumour relieved by a decompression operation. Brit. M. J.,* ***1910,*** *i, 1226–1227.*

96. **Klebs (E.).** *Beiträge zur Geschwulstlehre. II. Die Geschwülste des nervösen Centralapparates. Vrtljschr. f. prakt. Heilk.,* ***1877,*** *cxxxiii, 1–84 (Case 12).*

97. **Knoblauch.** *De neuromate et ganglii̇s accessoriis. Inaug. Dissert., Frankfort,* ***1843.*** *Cited by Adrian.*

98. **Kolb.** *Beitrag zur Kenntnis der Geschwülste des Kleinhirnbrückenwinkels. Inaug. Dissert., Giessen,* ***1910.***

99. **Korteweg & Winkler, quoted by Winkler & Rotgans.** *Cf. Chipault, A.: L'état actuel de la chirurgie nerveuse,* ***1902,*** *i, 689.*

100. **Krause (F.).** *Die Neuralgie der Trigeminus. Leipzig, F. C. W. Vogel,* ***1896,*** *103.*

101. *Zur Freilegung der hinteren Felsenbeinfläche und des Kleinhirns. Beitr. z. klin. Chir.,* ***1903,*** *xxxvii, 728–764.*

102. *Operationen in der hinteren Schädelgrube. Arch. f. klin. Chir.,* ***1906,*** *lxxxi, 40–60.*

103. *Discussion of Eiselsberg's paper. Tr. Internat. Cong. Med., Lond.,* ***1913,*** *Sec. VII, 214.*

104. **Kümmel (W.).** *Otologische Gesichtspunkte bei der Diagnose und Therapie von Erkrankungen der hinteren Schädelgrube. Deutsche Ztschr. f. Nervenh.,* ***1909,*** *xxxvi, 132–142.*

105. **Langdon (F.).** *Multiple tumors of the brain; fibrocystoma of pons and cerebellum and multiple fibropsammomata of dura, pia-arachnoid and cortex cerebri. Brain,* ***1895,*** *xviii, 551–561.*

106. **Lange (W.).** *Labyrinthveränderungen bei Tumoren des Kleinhirns und Kleinhirnbrückenwinkels. Arch. f. Ohrenh.,* ***1913,*** *xc, 180–199.*

107. **Lannois (M.) & Durand (M.).** *Deux cas d'intervention pour tumeurs de l'angle ponto-cérébelleux (tumeurs de l'acoustique). Ann. d. mal. de l'oreille, du larynx (etc.),* ***1909,*** *xxxv, Part 1, 629–673.*

108. **Lecène (P.).** *Les tumeurs de l'angle ponto-cérébelleux et leur traitement chirurgical. J. de chir.,* ***1909,*** *ii, 361–375.*

109. **Leischner (H.).** *Zur Chirurgie des Kleinhirnbrückenwinkeltumors. Mitt. a. d. Grenzgeb. d. Med. u. Chir.,* ***1911,*** *xxii, 675–714.*

110. **Lévéque-Lasource (A.).** *Observation sur un amaurosis et un cophosis, avec perte ou diminution de la voix, des mouvemens, etc., par suite de lésion organique apparente de plusieurs parties du cerveau. J. gén. de méd., chir. et pharm.,* ***1810,*** *xxxvii, 368–373.*

111. **Levi (E.).** *Studien zur normalen und pathologischen Anatomie der hinteren Rückenmarkswurzeln. Arb. a. d. neurol. Inst. a. d. Wien. Univ.,* ***1906,*** *xiii, 62–77.*

112. **Lexer (E.).** *Zur Operation des Ganglion Gasseri nach Erfahrungen an 15 Fällen. Arch. f. klin. Chir.,* ***1902,*** *lxv, 843–928.*

113. **Leyden (E. v.).** *Über einen Fall von Bulbärparalyse. Charité-Ann.,* ***1887,*** *xii, 129–139.*

114. **Lhermitte (J.) & Klarfeld (B.).** *Gliome pré-protubérantiel avec métastases. Hémiplégie sans dégénération du faisceau pyramidal. Rev. neurol.,* ***1911,*** *xxi, 392–397.*

115. **Lincke (C. v.).** *Handbuch der theoretischen und praktischen Ohrenheilkunde. Leipzig,* ***1837,*** *i, 650.*

116. **Lloyd (J.) & Gerson (T).** *A case of cerebellar tumor. Phila. M. J.,* ***1902,*** *ix, 298–300.*

117. **Luciani (L.).** *Il Cervelletto. R. Istituto di Studi Superiori, Firenze,* ***1891.***

*Das Kleinhirn. Ergebn. d. Physiol.,* ***1904,*** *Part 2, iii, 259–338.*

118. **Lutz (H.).** *Ein Teratom am Kleinhirnbrückenwinkel beim Meerschweinchen. Arb. a. d. neurol. Inst. a. d. Wien. Univ.,* ***1910,*** *xviii, 111–117.*

119. **Marx (H.).** *Zur Chirurgie der Kleinhirnbrückenwinkeltumoren. Mitt. a. d. Grenzgeb. d. Med. u. Chir.,* ***1913,*** *xxvi, 117–134.*

120. **Mayer (O.).** *Kleinhirnbrückenwinkeltumor? Monatsschr. f. Ohrenh. (etc.),* ***1915,*** *xlix, 716–718.*

121. **McBurney (C.) & Starr (M.).** *A contribution to cerebral surgery: diagnosis, localization and operation for removal of three tumors of the brain: with some comments upon the surgical treatment of brain tumors. Am. J. M. Sc.,* ***1893,*** *cv, 361–387.*

122. **McCaskey (G.).** *A case of tumor of the cerebellum with drainage of fluid through the nose. N. York M. J. (etc.),* ***1900,*** *lxxi, 454–458.*

123. **Meyer (W.).** *Craniectomy for tumor of acoustic nerve. Ann. Surg.,* ***1908,*** *xlviii, 309–311; ibid.,* ***1909,*** *xlix, 552–553; ibid.,* ***1912,*** *lv, 323–324.*

124. **Mills (C.).** *The diagnosis of tumors of the cerebellum and the cerebellopontile angle, especially with reference to their surgical removal. N. York M. J. (etc.),* ***1905,*** *lxxxi, 261; 324.*

125. **Mills (C.) & Weisenburg (T.).** *Cerebellar symptoms and cerebellar localization. J. Am. M. Ass.,* ***1914,*** *lxiii, 1813–1818.*

126. **Mingazzini (G.).** *Neue klinische und anatomo-pathologische Studien über Hirngeschwülste und Abszesse. Arch. f. Psychiat.,* ***1910,*** *xlvii, 1028–1162.*

127. *Pathogenese und Symptomatologie der Kleinhirnerkrankungen. Ergebn. d. Neurol. u. Psychiat.,* ***1912,*** *i, 89–216.*

128. **Mitchell (S.).** *Researches on the physiology of the cerebellum. Am. J. M. Sc.,* ***1869,*** *lvii, 320–338.*

129. **Monakow (v.).** *Über Neurofibrome der hinteren Schädelgrube. Berl. klin. Wchnschr.,* ***1900,*** *xxxvii, 721–724.*

130. **Morély (P.).** *Sarcome angiolithique des méninges comprimant la protubérance annulaire et le cervelet. Bull. de la Soc. Anat.,* ***1897,*** *lxxii, 354–357.*

131. **Murri (A.).** *Upon diagnosis of tumour of the cerebellum. Lancet,* ***1897,*** *i, 291–295.*

132. **Muskens.** *Eenige waarnemingen omtrent reukstoornissen (neuritis olfactoria) bij verhooging van den intracranieelen druk. Nederl. Tijdschr. v. Geneesk.,* ***1901,*** *ii, 1007.*

133. **Oppenheim (H.).** *Über mehrere Fälle von endocraniellem Tumor in welchen es gelang eine genauere Localdiagnose zu stellen. Berl. klin. Wchnschr.,* ***1890,*** *xxvii, 38–40.*

134. **Oppenheim (H.) & Borchardt (M.).** *Zwei mit Erfolg operierten Fälle von Geschwulst am Kleinhirnbrückenwinkel. Berl. klin. Wchnschr.,* ***1907,*** *xliv, 875–879.*

135. **Orzechowski (K.).** *Fall von Missbildung des Lateralrezessus. Ein Beitrag zur Onkologie des Kleinhirnbrückenwinkels. Arb. a. d. neurol. Inst. a. d. Wien. Univ.,* ***1908,*** *xiv, 406–491.*

136. **Panse (R.).** *Ein Gliom des Akustikus. Arch. f. Ohrenh.,* ***1904,*** *lxi, 251–255.*

137. **Pascalis (S.).** *Tumeurs de l'angle ponto-cérébelleux. Indications opératoires et traitement chirurgical. Rev. de chir.,* ***1912,*** *xlv, 53.*

138. **Picqué (L.) & Mauclaire (P.).** *Suppurations otitiques de la loge cérébelleuse. Cong. franç. de chir.,* ***1898,*** *123–169.*

139. **Politzer.** *Lehrbuch der Ohrenheilkunde. Stuttgart, Ed. 4,* ***1901,*** *624.*

140. **Poppert.** *Exstirpation eines Tumors des Kleinhirnbrückenwinkels. Deutsche med. Wchnschr.,* ***1907,*** *xxxiii, 613.*

141. **Preisig (H.).** *Tumeur de l'angle ponto-cérébelleux. Rev. méd. de la Suisse Rom.,* ***1916,*** *xxxvi, 510.*

142. **Püschmann.** *Fall von Kleinhirnbrückengeschwulst. Deutsche med. Wchnschr.,* ***1906,*** *xxxii, 836–837.*

143. **Putnam (J.) & Waterman (G.).** *A contribution to the study of cerebellar tumors and their treatment. J. Nerv. & Ment. Dis.,* ***1906,*** *xxxiii, 297–323 (Case IV).*

144. **Quix (F.).** *Ein Acusticustumor. Arch. f. Ohrenh.,* ***1911,*** *lxxxiv, 252–253.*

145. *Ein Fall von operierter Acusticus-Geschwulst mit Darstellung mikrophotographischer Lichtbilder und Besprechung der Operationstechnik. Monatsschr. f. Ohrenh. (etc.),* ***1915,*** *xlix, 717–718.*

146. **Raymond (F.).** *Sur un cas de tumeur du cervelet. N. iconog. de la Salpêtrière,* ***1898,*** *xi, 213–229. Also: Leçons sur les maladies du système nerveux. Paris,* ***1898,*** *Series 3, Clinic VI, 77–140; 229.*

147. **Raymond (F.); Huet (L.) & Alquier.** *Paralysie faciale périphérique due à un fibrosarcome englobant le nerf à sa sortie du bulbe. Arch. de neurol.,* ***1905,*** *Series 2, xix, 1–8.*

148. **Recklinghausen (F. v.).** *Doppelseitige Hydrocele des vierten Ventrikels. Arch. f. path. Anat. (etc.),* ***1864,*** *xxx, 374–375.*

149. *Über die multiplen Fibrome der Haut und ihre Beziehung zu den multiplen Neuromen. Virchow's Festschrift, Berlin,* ***1882.***

150. **Rokitansky (C.).** *Lehrbuch der pathologischen Anatomie. Wien, Ed. 3,* ***1855,*** *i, 167.*

151. *Ibid.,* ***1856,*** *ii, 501.*

152. **Rosenstein (A.).** *Zur Kenntnis der syphilitischen Erkrankungen des Hörnervenstammes. Arch. f. Ohrenh.,* ***1905,*** *lxv, 193–225.*

153. **Rosenthal (M.).** *Klinik der Nervenkrankheiten. Stuttgart,* ***1875,*** *p. 199.*

154. **Russell (J. S. Risien).** *Experimental researches into the functions of the cerebellum. Phil. Tr., Lond.,* ***1894,*** *clxxxv, 109.*

*The value of experimental evidence in the diagnosis of diseases of the cerebellum. Brit. M. J.,* ***1895,*** *i, 1079.*

*The effects of interrupting afferent and efferent tracts of the cerebellum. Brit. M. J.,* ***1896,*** *ii, 914.*

155. **Sandifort (E.).** *Observationes anatomico-pathologicae. Lugduni Batavorum,* ***1777,*** *Chap. IX, 116–120.*

156. **Schede.** *Zwei Fälle von Kleinhirntumoren. Deutsche med. Wchnschr.,* ***1900,*** *xxvi, 477–478.*

157. **Schlesinger.** *Fall von Zystizerkus. Wien. klin. Wchnschr.,* ***1911,*** *xxiv, 223.*

158. **Schmiegelow (E.).** *Beitrag zur translabyrinthären Entfernung der Akustikustumoren. Ztschr. f. Ohrenh.,* ***1915,*** *lxxiii, 1–21.*

159. **Schüller (A.).** *Röntgen-Diagnostik der Erkrankungen des Kopfes. Wien, Alfred Hölder,* ***1912,*** *138.*

160. **Schuster (P.).** *Psychische Störungen bei Hirntumoren. Stuttgart,* ***1902,*** *Chap. XI, 205.*

161. **Seiffer.** *Tumor der hinteren Schädelgrube. München. med. Wchnschr.,* ***1902,*** *xlix, 2027.*

162. **Sézary (A.) & Jumentié (J.).** *Étude anatomo-pathologique de cinq tumeurs ponto-cérébelleuses. Rev. neurol.,* ***1911,*** *xxi, 398–401.*

163. **Sharkey (S.).** *A fatal case of tumor of the left auditory nerve. Brain,* ***1888,*** *xi, 97–101.*

164. **Sicard (J.) & Gy (A.).** *Méningite sarcomateuse à prédominance bulbo-protubérantielle. Cyto-diagnostic rachidien néoplasique. Rev. neurol.,* ***1908,*** *xvi, 1245–1250.*

165. **Siebenmann.** *Adenocarcinom des Acusticusstammes. Monatsschr. f. Ohrenh. (etc.),* ***1914,*** *xlviii, 278.*

166. **Sieskind.** *Ein Beitrag zur Klinik der Tumoren im Kleinhirnbrückenwinkel. Inaug.-Dissert. Heidelberg,* ***1908.***

167. **Sorgo (J.).** *Zur Klinik der Tumoren des Nervus acusticus nebst Bemerkungen zur Symptomatologie und Diagnose der Kleinhirntumoren. Monatsschr. f. Ohrenh. (etc.),* ***1901,*** *xxxv, 285–310.*

168. **Souques (M.).** *Tumeurs de l'angle ponto-cérébelleux, dites du nerf acoustique. Diagnostic topographique et traitement chirurgical. Rev. neurol.,* ***1909,*** *xvii, 775–781.*

169. **Spiller (W.).** *Tumor malformations of the central nervous system. Rev. Neurol. & Psychiat.,* ***1908,*** *vi, 677–682.*

170. **Stark.** *Zur Pathologie der Gehirngeschwülste. Arch. f. Psychiat.,* ***1907,*** *xliii, 1323–1324.*

171. **Starr (M.).** *Brain Surgery. New York, W. Wood & Co.,* ***1893,*** *215.*

172. *Remarks on brain tumors and their removal. Brit. M. J.,* ***1897,*** *ii, 1047–1051.*

173. *Tumors of the acoustic nerve: their symptoms and surgical treatment. Am. J. M. Sc.,* ***1910,*** *xxxix, 551–581.*

174. **Sternberg (C.).** *Beitrag zur Kenntnis der sogenannten Geschwülste des N. acusticus. Ztschr. f. Heilk.,* ***1900,*** *xxi, 163–186.*

175. **Stevens (G.).** *A case of tumor of the auditory nerve occupying the fossa for the cerebellum. Arch. Otol.,* ***1879,*** *viii, 171–176.*

176. **Stewart (J.).** *A contribution to the localization of cerebellar lesions. Edinb. Hosp. Rep.,* ***1895,*** *iii, 447–453.*

177. **Stewart (T.) & Holmes (G.).** *Symptomatology of cerebellar tumours; a study of forty cases. Brain,* ***1904,*** *xxvii, 522–591.*

178. **Stieglitz (L.); Gerster (A.) & Lilienthal (H.).** *A study of three cases of tumor of the brain in which operation was performed—one recovery, two deaths. Am. J. M. Sc.,* ***1896,*** *cxi, 509–531.*

179. **Stoddard (J.) & Cutler (E.).** *Torula infection in man. Monogr. Rockefeller Inst. M. Research,* ***1916,*** *No. 6, 1–98.*

180. **Sutton (J.).** *The lateral recesses of the fourth ventricle; their relation to certain cysts and tumors of the cerebellum, and to occipital meningocele. Brain,* ***1886,*** *ix, 352–361.*

181. **Tooth (H.).** *Some observations on the growth and survival period of intracranial tumors, based on the records of 500 cases, with special reference to the pathology of the gliomata. Brain,* ***1912,*** *xxxv, 61–108.*

182. *The treatment of tumours of the brain, and the indications for operations. Tr. Internat. Cong. Med., Lond.,* ***1913,*** *Sec. VII, Pt. 1, 203–299.*

183. *On the indications for surgical treatment in intracranial tumor. Practitioner,* ***1914,*** *xcii, 487–500.*

184. **Toynbee (J.).** *Neuroma of the auditory nerve. Tr. Path. Soc. Lond.,* ***1853,*** *iv, 259–260.*

185. **Trömner.** *Tumoren der Hirnbasis. Neurol. Centralbl.,* ***1909,*** *xxviii, 166.*

186. **Verocay (J.).** *Zur Kenntnis der "Neurofibrome." Beitr. z. path. Anat. u. z. allg. Path.,* ***1910,*** *xlviii, 1–68.*

187. **Virchow (R.).** *Das wahre Neurom. Arch. f. path. Anat. (etc.),* ***1858,*** *xiii, 256–265.*

188. *Die krankhaften Geschwülste. Berlin,* ***1863–65,*** *i, 180.*

189. *Ibid., ii, 116.*

190. *Ibid., iii, 295.*

191. **Voss (G. v.).** *Fünf Fälle von Kleinhirntumor. Deutsche Ztschr. f. Nervenh.,* ***1902,*** *xxi, 48–72.*

192. **Weed (L.).** *Studies on cerebro-spinal fluid. II. The theories of drainage of cerebro-spinal fluid with an analysis of the methods of investigation. J. Med. Research,* ***1914,*** *xxxi, 21–49.*

193. *Studies on cerebro-spinal fluid. III. The pathways of escape from the subarachnoid spaces with particular reference to the arachnoid villi. J. Med. Research,* ***1914,*** *xxxi, 51–91.*

194. **Weiglein (C.).** *Einige Krankheitsfälle, beobachtet im Siechenhause zu Grätz. Med. Jahrb. d. k. k. österr. Staates, Wien,* ***1840,*** *xxi, 569–574.*

195. **Weisenburg (T.).** *Diagnosis of tumors and other lesions in the cerebello-pontile angle. J. Am. M. Ass.,* ***1908,*** *l, 1251–1258.*

196. *Cerebellopontine tumor diagnosed for six years as tic douloureux. J. Am. M. Ass.,* ***1910,*** *liv, 1600–1604.*

197. **Westphal.** *Doppelseitige Amaurose (Neuroretinitis) und doppelseitige Taubheit; linksseitige Hemiparese. Autopsie; Geschwulst im linken mittleren Kleinhirnschenkel, in den inneren Gehörgang hineinwuchernd. Charité-Ann.,* ***1874,*** *i, 435–442.*

198. **Westphal (A.).** *Beitrag zur Kenntnis der Kleinhirnbrückenwinkeltumoren und der multiplen Neurofibromatose. Deutsche Ztschr. f. Chir.,* ***1908,*** *xcv, 403–417.*

199. *Zwei Fälle von operativer Beseitigung von Gehirngeschwülsten. Deutsche med. Wchnschr.,* ***1915,*** *xli, 1567–1569.*

200. **Weygandt.** *Trauma e tumore dell'angolo ponto-cerebellare. Abstr.: J. Nerv. & Ment. Dis.,* ***1913,*** *xl, 339.*

201. **Wiersma (E.).** *Fälle von Hemiatrophia linguæ. Neurol. Centralbl.,* ***1899,*** *xviii, 822.*

202. **Wilson (J.) & Pike (F.).** *Vertigo. J. Am. M. Ass.,* ***1915,*** *lxiv, 561–564.*

203. *The differential diagnosis of lesions of the labyrinth and of the cerebellum. J. Am. M. Ass.,* ***1915,*** *lxv, 2156–2161.*

204. **Winkler (C.) & Rotgans (J.).** *Cf. Chipault, A.: L'état actuel de la chirurgie nerveuse,* ***1902,*** *i, 658–755.*

205. **Wishart (J.).** *Cases of tumors in the skull, dura mater, and brain. Edinb. M. & S. J.,* ***1822,*** *xviii, 393–397.*

206. **Wolbach (S.).** *Multiple hernias of the cerebrum and cerebellum, due to intracranial pressure. J. Med. Research,* ***1908,*** *xix, 153–173.*

207. **Wolff (H.).** *Akustikustumor. Ein Beitrag zur Entstehung der Kleinhirnbrückenwinkeltumoren. Beitr. z. Anat., Physiol., Path. u. Therap. d. Ohres (etc.),* ***1912,*** *v, 464–466.*

208. **Wollenberg (R.).** *Zwei Fälle von Tumor der hinteren Schädelgrube. Arch. f. Psychiat.,* ***1890,*** *xxi, 791–805.*

209. *Über die cysticerken, insbesondere den Cysticercus racemosus des Gehirns. Arch. f. Psychiat.,* ***1905,*** *xl, 98–150.*

210. **Woolsey (G.) (with Fraenkel & Hunt).** *Ann. Surg.,* ***1904,*** *xl, 293–319.*

211. **Zange (J.).** *Über anatomische Veränderungen im Labyrinthe bei Kleinhirnbrückenwinkeltumoren und ihre klinische Bedeutung. Arch. f. path. Anat.,* ***1912,*** *ccviii, 297–318.*

212. *Translabyrinthäre Operationen von Acusticus- und Kleinhirnbrückenwinkeltumoren. Berl. klin. Wchnschr.,* ***1915,*** *lii, 1334.*

213. **Ziegenweidt (v.).** *Tumor cerebelli. Psychiat. en Neurol. Bl., Amst.,* ***1899,*** *iii, 36–44.*

214. **Ziehen (T.).** *Über Tumoren der Akustikusregion. Med. Klin.,* ***1905,*** *l, 847; 874.*

215. *Zur Differentialdiagnose des Kleinhirntumors. Med. Klin.,* ***1909,*** *v, 9–12.*

# INDEX OF AUTHORS


Abercrombie, 3
Alagna, 12, 147, 182, 185, 195, 199
Alexander, 155, 166, 178, 190, 195, 205, 207, 208, 241
Alquier, 12, 148, 164, 166, 175, 235
Annandale, 245
Askanazy, 181, 206

Babinski, 10, 161, 164, 173, 235
Baisch, 246
Ballance, 181, 222, 245, 246
Bárány, 157, 241, 247
Barbé, 147
Bassoe, 190, 204, 211, 213
Bell, 3, 176, 180, 195
Beneke, 193
Berggrün, 210
Bielschowsky, 166, 235
Biggs, 155, 214, 235
Boettcher, 208
Borchardt, 246, 249, 251
Borst, 195, 206
Boyer, 3
Bramwell, 235
Bregman, 235
Bright, 3
Bruce, 165
Brückner, 147, 166, 175
Bruns, 10, 149, 165, 235

Chipault, 246
Collier, 172, 220
Collin, 147
Councilman, 204
Cruveilhier, 4, 166, 181, 184, 193
Cushing, 39, 73, 93, 165, 167, 171, 172, 177, 191, 244, 249, 258, 270
Cutler, 15

Dalton, 10
Dana, 174
Druault, 150, 181, 220

Eichelberg, 235
Eiselsberg, v., 221, 246, 247, 249, 251, 265, 274, 277
Elsberg, 246, 249

Ferrier, 10
Fester, 195
Foix, 219
Fraenkel, 11, 155, 193, 213, 214, 246
Frankl-Hochwart, 155, 166, 174, 190, 207, 208
Frazier, 246, 251, 263
Fumarola, 12, 182, 220, 274
Funkenstein, 181, 208, 213, 214

Gairdner, 217
Garré, 213, 246
Gerster, 245
Gibson, 245
Gierlich, 148, 169
Goerke, 195, 208
Gomperz, 195, 208
Goodhart, 219
Goodpasture, 206
Gowers, 10, 149, 235
Grasser, 222, 235
Grey, 154, 163, 171, 172, 242
Grinker, 25
Guldenarm, 245, 246

Haldane, 217
Hartmann, 11
Henneberg, 11, 147, 170, 195, 211, 214
Henschen, 11, 12, 73, 98, 148, 149, 150, 154, 157, 177, 178, 179, 182, 183, 184, 195, 197, 206, 207, 208, 212, 214, 218, 234, 237, 274
Hermanides, 220, 221
Heuer, 31
Higier, 220
Hildebrand, 235
Holmes, 11, 156, 161, 162, 165, 166, 170, 213, 246
Horsley, 172, 213, 246, 270
Hubrich, 219
Huet, 148, 166
Hulles, 205, 206
Hunt, 11, 155, 193, 213, 214, 246

Jackson, 10, 30, 166, 174
Jakob, 235
Jiano, 265

Josefson, 157
Jumentié, 12, 152, 175, 190, 207

Kato, 235
Keen, 255
Kennedy, 43
Klarfeld, 12, 164, 175, 206, 235
Klebs, 181, 195
Knoblauch, 211
Koch, 11, 147, 170, 195, 211, 214
Kolb, 206
Korteweg, 250
Krause, 164, 246, 247, 251, 274, 277
Kümmel, 242, 247, 249

Langdon, 195, 214
Lange, 185, 208
Lecène, 250
Leischner, 197, 214, 249, 251, 265, 274, 277
Lévéque-Lasource, 3
Levi, 205
Lexer, 164, 218
Leyden, 148, 168, 219
Lhermitte, 206, 235
Lincke, 2
Luciani, 10
Lutz, 148

Marx, 247, 249
Mauclaire, 246
Mayer, 155
McBurney, 245
McCaskey, 235
Meyer, 154, 250
Mills, 30, 99, 161, 166, 171, 173
Mingazzini, 182, 195, 220
Mitchell, 10
Monakow, v., 11, 236, 244, 245
Morély, 219
Murri, 245
Muskens, 171

Narath, 246

Obersteiner, 195, 205
Oppenheim, 10, 163, 165, 170, 219, 236, 249
Orzechowski, 11, 148

Panse, 178, 182, 208, 247
Picqué, 246
Pike, 155, 156, 161
Politzer, 181
Poppert, 250
Preisig, 172
Püschmann, 235
Putnam, 175

Quix, 178, 208, 247, 249

Raymond, 148, 166, 211, 219, 246
Rokitansky, 10, 195
Rosenstein, 235
Rosenthal, 235
Rotgans, 221, 245
Russell, 10

Sandifort, 2, 222
Schede, 246
Schlesinger, 235
Schmiegelow, 247
Schüller, 236
Schuster, 172
Schwabach, 235
Seiffer, 170
Sézary, 207
Sharkey, 155, 181, 190, 218
Siebenmann, 235
Sieskind, 277
Sorgo, 152, 166, 169
Souques, 219
Spiller, 148, 163
Stark, 170, 172, 213
Starr, 31, 33, 160, 174, 244, 245
Sternberg, 10, 147, 195, 207, 213, 245
Stevens, 10
Stewart, J., 245
Stewart, T., 11, 156, 161, 162, 165, 166, 170, 213, 246
Stieglitz, 245
Stoddard, 15
Sutton, 235

Tooth, 17, 150, 172, 221, 274, 276, 277
Tournay, 173
Toynbee, 9, 154, 177
Trömner, 235
Turner, 10

Verocay, 12, 148, 195, 199, 206, 207, 214, 215
Virchow, 2, 9, 179, 181, 183, 195, 207, 222, 235
Voss, v., 170, 213

Walker, 39, 73
Waterman, 175
Weed, 194
Weiglein, 3, 181, 194

Weisenburg, 99, 161, 164, 166, 173, 218, 236
Westphal, 181
Westphal, A., 148, 214
Weygandt, 147
Whiting, 176, 180
Wiersma, 170
Wilson, 155, 156, 161
Winkler, 221, 245, 250
Wishart, 174, 211, 214
Wolbach, 193
Wolff, 178
Wollenberg, 10, 235
Woolsey, 246

Zange, 182, 208, 220, 247
Ziegenweidt, 245, 250
Ziehen, 11, 99, 166, 174, 218, 220, 246

# INDEX OF SUBJECTS


Abducens nerve, weakness of, 165, 190
Accessory nerve, distortion of, 191
  involvement of, 169
Adiadococinesia, 161
Ageusia, 167
Anæsthesia, charts, examples of, 109, 118, 254
  in cerebellar operations, 31, 252
Anosmia, 171
Arachnoid cysts, evacuation of, 220, 263
  frequency of, 175, 185, 219
Ataxia, 155, 160
Auditory nerve, histology of, 206
  inaugural involvement of, 153

Bárány reactions, 120, 154, 156, 241
Bilateral tumors, 47, 210
Binasal hemianopsia, 39, 73
Bone, pressure absorption of, 157, 181, 185, 237
Brain, deformations of, 192

Caloric tests. See *Bárány reactions*
Case histories, method of recording, 154
Cerebellar crises, 30, 169, 174
  incoördination, 160
  involvement, confused with labyrinthine, 155, 159, 160
Cerebellum, distortion of, 192
Cerebral nerves, distortion of, 190
  histological studies of, 205
  involvement of, 162
Cerebrospinal fluid, obstruction of, 39
  relation of, to symptomatology, 175, 188, 219, 230
  rhinorrhœa, 172
Choked disc, 171, 275
  labyrinth, 208. See also *Labyrinth, choked*
Clinical statistics, 14
Cochlear nerve, degenerations in, 208
  involvement of, 153
Convalescence, 274

Decompression, suboccipital, results of, 69
  subtemporal, in cases of acoustic tumor, 43
Degenerations, 207
Diagnosis, 217
  age, important in, 150, 234
  auditory symptoms, important in, 152, 213, 230
  Bárány tests, aid in, 241
  dilated lateral ventricle, aid in, 221
  mistakes in, 218
    endothelioma, 218, 223
    glioma, 231, 234
    Jacksonian epilepsy, 166
    localization, 43, 220
    Ménière's disease, 155
    meningitis serosa circumscripta, 175, 219
    papilloma, 226
    torticollis, 170
    trigeminal neuralgia, 164
  order of importance of factors in, 146
  X-ray, aid in, 157, 172, 182, 185, 213, 221, 237
Diplopia, 165
Distant effects of acoustic tumors, 193
Dysarthria, origin of, 173
Dysmetria, 160
Dysphagia, origin of, 173
  post-operative pneumonia, induced by, 173
  respiratory failure, induced by, 173

Ear, middle, degenerations in, 208
Embryonal tissue rests, 147
Endothelioma simulating acoustic tumor, 218, 223
Endotheliomata of recess, 222
  pathological differentiation of, 184
  relation of, to acoustic tumors, 214
    to neurofibromatosis, 214
Erroneous tumor localization, 220
Etiology of acoustic tumors, 147

Facial nerve, distortion of, 190
  involvement of, 99, 165
    inaugural, 166
Fat cells, 202
Frontal-lobe involvement, 172

Gait, unsteadiness of, 160
Ganglion cells, 199, 206
General pressure symptoms, 171

Glioma, histological differentiation of, 98, 196
of acusticus, case of, 112
simulating acoustic tumor, 231, 234
Glossopharyngeal nerve, distortion of, 191
impairment of, 168
Growths simulating acoustic tumors, 221, 234

Headaches, 159, 171
Hearing, restoration of, after operation, 98, 155
Hemianopsia, 39, 73
Hereditary tendency, 148
Herniations, cerebral, 193
cortical, 193
foraminal, 193, 263
Herpes, post-operative, 165
Histogenesis, 206
Histology of acoustic tumors, 194, 215
importance of, 234
Hyaline degeneration, 202
Hydrocephalus, obstructed, treatment of, 106
Hydrops, 198, 202
Hypoglossal nerve, involvement of, 170

Incidence of acoustic tumors, 149
Infection, 147
Internal auditory meatus. See *Meatus acusticus internus*

Jacksonian epilepsy, a diagnostic error, 166

Labyrinth, choked, 208
function of, tests for, 241
involvement of, confused with cerebellar, 155, 159, 160
inaugural, 155
Large tumors, appearance of, 183
enucleation of, 35, 166, 265
Lateral cistern, distention of, 175, 188, 219

Meatus acusticus internus. See also *Diagnosis: X-ray*
dilatation of, pathological studies of, 179, 185
X-ray studies of, 157, 237
pressure atrophy of, 181, 185, 237
Medulla, distortion of, 192
Ménière's disease, a diagnostic error, 155
Meninges, alterations of, 185
Meningitis serosa circumscripta, misleading in diagnosis, 175, 219
Mental derangements. See *Psychic disturbances*
Mitosis, 198
Mortality after operations, 54, 247, 274, 277
Motor paths, involvement of, 175

Nasal feeding, 173
Nerve fibres, 204
Nerves, abducens, weakness of, 165, 190
accessory, distortion of, 191
involvement of, 169
auditory, histology of, 206
inaugural involvement of, 153
cerebral, distortion of, 190
histological studies of, 205
involvement of, 162
cochlear, degenerations in, 208
involvement of, 153
facial, distortion of, 190
involvement of, 99, 165
glossopharyngeal, distortion of, 191
impairment of, 168
hypoglossal, involvement of, 170
oculomotor, impairment of, 163
trigeminal, distortion of, 190
involvement of, 163
vagus, distortion of, 191
symptoms referable to, 169
vestibular, degenerations in, 208
involvement of, 155
tumor involving, case of, 178
Neurofibromatosis, relation of, to acoustic tumors, 148, 210
to endotheliomata, 214
Nuclei, arrangements of, 198
Nystagmus, 156, 161

Oculomotor nerve, impairment of, 163
Œdema of tissues, 199
Olfaction, impairment of, 171
Operations tabulated, 278
Operative methods of approach, 245
bilateral, 249
preferential, advantages of, 250, 272
imperfections of, 272
steps of, 251
suboccipital and petrosal, 249
translabyrinthine, 247
unilateral, 246
mortality figures, 54, 247, 274, 277
results, 273
degree of symptomatic relief, 275
duration of symptomatic relief, 276
prolongation of life, 276

Operative results, resumption of occupation, 275
Origin of acoustic tumors, difficulty in distinguishing from facial, 183
embryonal, from tissue rests in nerve, 147, 207, 215
in distal (within canal) portion of nerve, 98, 157, 177
in endoneural portion of nerve, 182 183, 206
in middle wall of recess, from anlage, 148
in peripheral portion of nerve, 177, 206
in proximal (free) portion of nerve, 98, 115, 182
in transition zone in nerve, 206
relation of, to neurofibromatosis, 148, 215
tumor surface defect, significant of, 184

Papilloma simulating acoustic tumor, 226
Pathology of acoustic tumors, 177
Pigmentation, 202
Pneumonia, post-operative, 173
Pons, distortion of, 192
Porus acusticus internus. See *Meatus*
Pregnancy, effect of, 148
Prognosis, 150, 276
Psammoma bodies, 195
Psychic disturbances, 172
Pyramidal bone, examination of, 157, 184

Radiographic changes. See *X-ray*
von Recklinghausen's disease. See *Neurofibromatosis*
Reflexes, corneal, 163
deep, 176
palatal, 164
Respiration, artificial, 31, 255
Rhinorrhœa, 172
Röntgen ray. See *X-ray*

Sarcoma confused with acoustic tumor, 195
histological differentiation of, 198
Sella turcica, X-ray changes in, 236
Sensory disturbances, 175
Situation of tumors, 149
Size of tumors, 183
Small tumors, enucleation of, 265
origin of, 177
Smell, impairment of, 171
Suboccipital discomforts, 159
Surgical treatment, 244. See also *Operations*
arachnoid cyst evacuation, 185, 220, 263
lateral ventricle puncture, value of, 221, 262
lumbar puncture, danger of, 219
removal of arch of atlas, value of, 46, 263
suboccipital decompression, results of, 69
tabulation of cases, 278
total tumor enucleation, dangers of, 35, 166, 265
transcerebellar approach, avoidance of, 54
Symptoms, 152
age at onset of, 149
auditory, importance of, 152, 213, 230
bilateral, 212
cerebellar, 160
cerebral nerve, 162
contralateral, 162, 166, 221
differentiation of, 11, 221, 234
duration of, 151
fluctuation of, 174, 219
frontal-lobe, 172
general pressure, 171
inaugural, 152
medullary, 175
misinterpretation of, 218
order of onset of, 176
post-operative relief from, degree of, 275
duration of, 276
tabulation of, 162
unmistakable, of acoustic tumor, 217

Tabulation of brain tumors, 15, 16, 17
of operations, 278
of symptoms, 162
Taste, impairment of, 167
Terminology of acoustic tumors, 11, 195, 207
Tic douloureux, a diagnostic error, 164
Tinnitus, 153
Tissue, fibrous, 198
œdema of, 199
reticular, 199
types of, 197
Tongue, atrophy of, 170, 213
Torticollis, a diagnostic error, 170
Trauma, 147
Trigeminal nerve, distortion of, 190
involvement of, 163
discomforts, 164

Trigeminal nerve, motor division of, 165
Tumors, acoustic, area of attachment of, 184
degenerations produced by, 207
differentiation of, 221, 234
distant effects of, 193
relation of, to brain, 190
to endotheliomata, 214
to meninges, 185
to neurofibromatosis, 148, 210, 215
simulated by other lesions, 234
situation of, 149
size of, 183

Vagus nerve, distortion of, 191
symptoms referable to, 169
Vertigo, 156, 162
Vestibular nerve, degenerations in, 208
involvement of, 155
tumor involving, case of, 178
Vision, preservation of, 275
Vomiting, 171
von Recklinghausen's disease. See *Neurofibromatosis*

X-ray studies of porus acusticus internus, 157, 237
stereoscopic, 240
of sella turcica, 236

D7 50